

# Marginal Ulcer after RYGBP

Rana C Pullatt MD FACS FASMBS DABOM

Director Bariatric & Robotic Surgery

Division Chief Metabolic & Foregut Surgery

Professor of Surgery

Medical University of South Carolina

Director Bariatric Surgery VISN-7



# DISCLOSURES

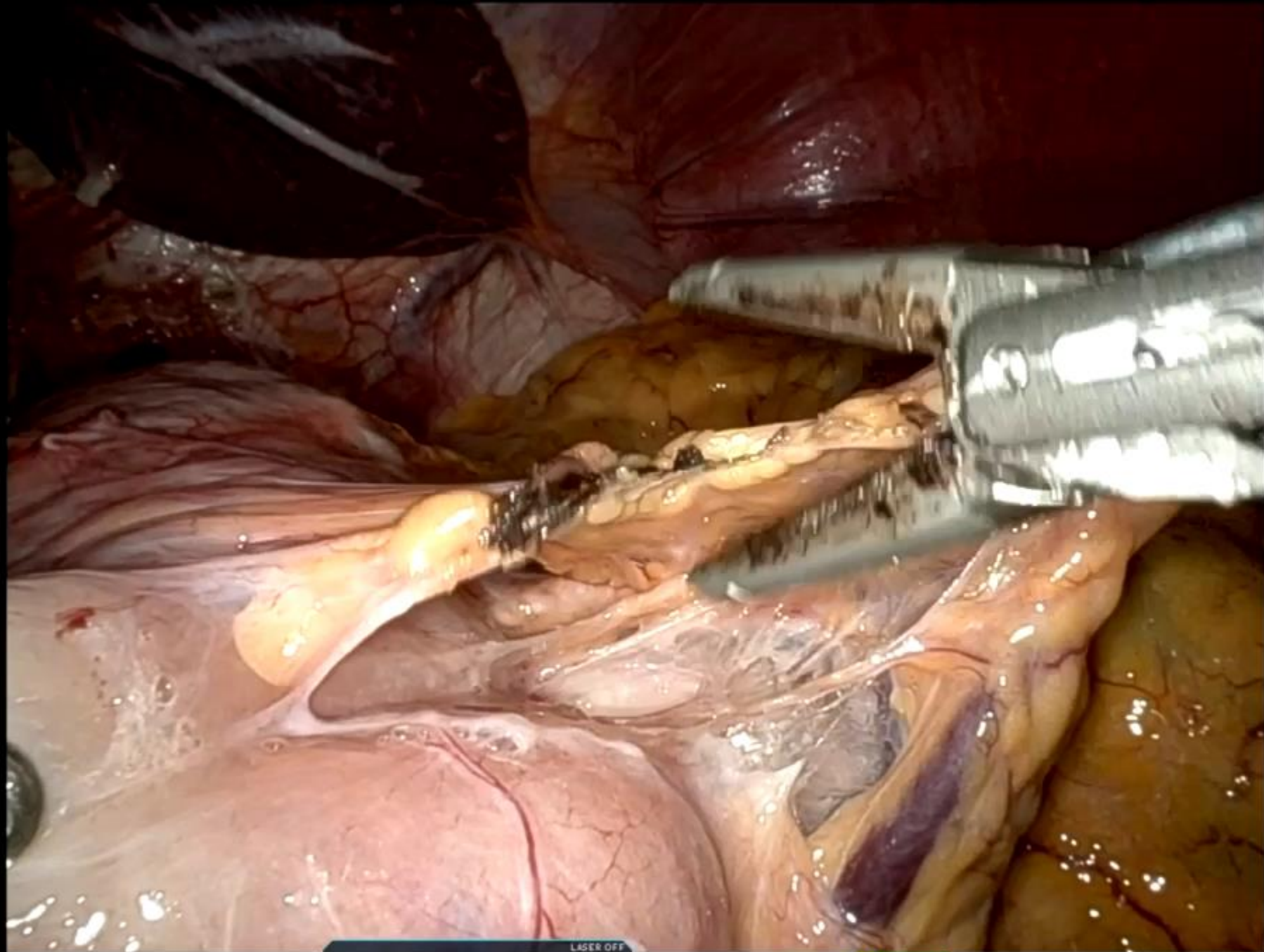
Proctor- Intuitive

Consultant- Medtronic

Speaker- Conmed.

# Etiology

- ◆ Gastrogastric Fistula
- ◆ Large Gastric Pouch
- ◆ Suture material
- ◆ NSAID use
- ◆ Smoking
- ◆ Excess acid production
- ◆ H. Pylori
- ◆ Ischemia



1 CADIERE FORCEPS      2 10° REV      3 VESSEL SEALER EXTEND      4 CADIERE FORCEPS

LASER OFF      1x 30°      R CUT      R BIPOLAR





Thank You

[pullattr@gmail.com](mailto:pullattr@gmail.com)