

SADI/ DS- The terrible Duodenum

Rana C Pullatt MD FACS FASMBS DABOM

Director Bariatric & Robotic Surgery

Division Chief Metabolic & Foregut Surgery

Professor of Surgery

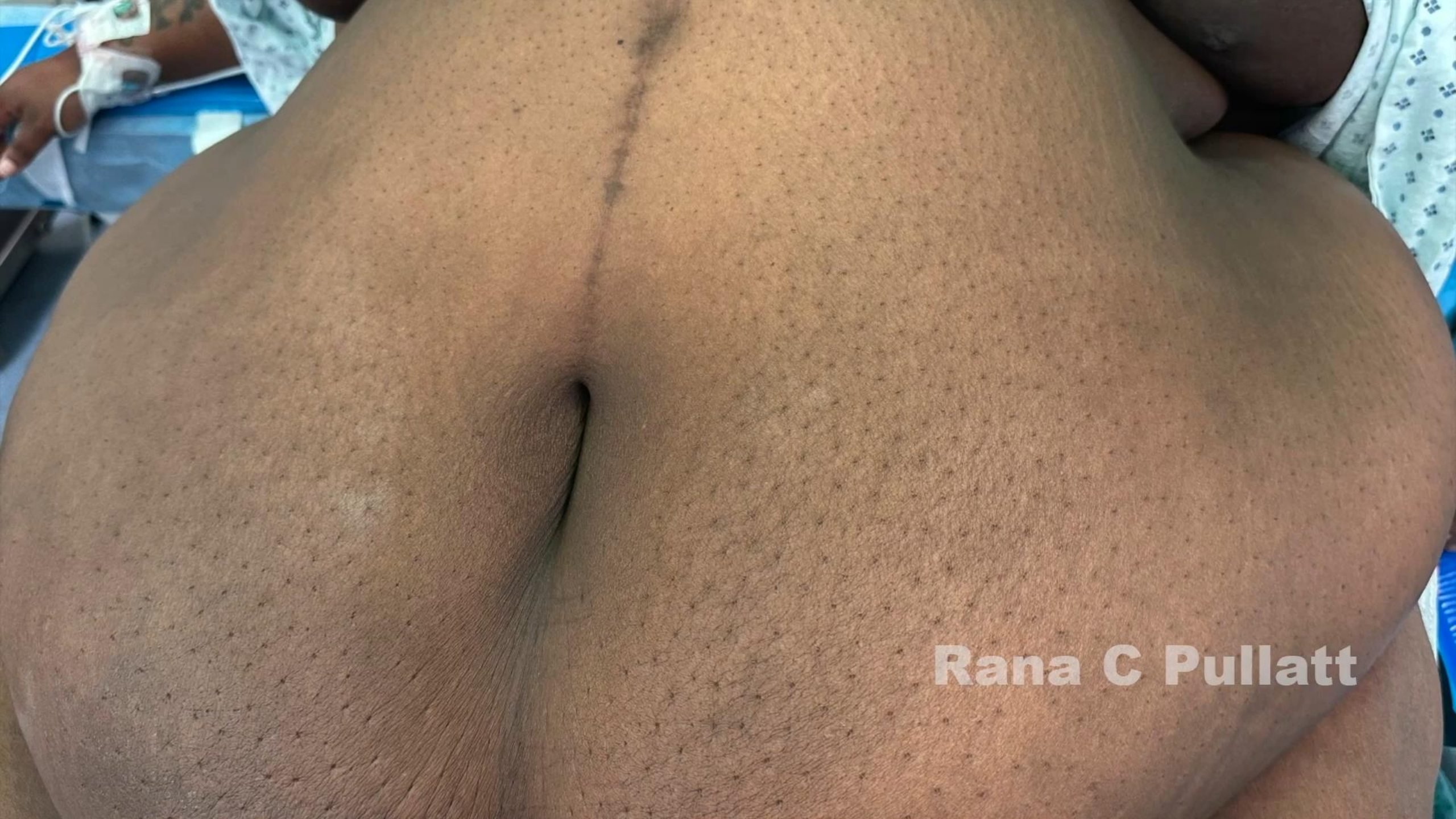Medical University of South Carolina

Director Bariatric Surgery VISN-7

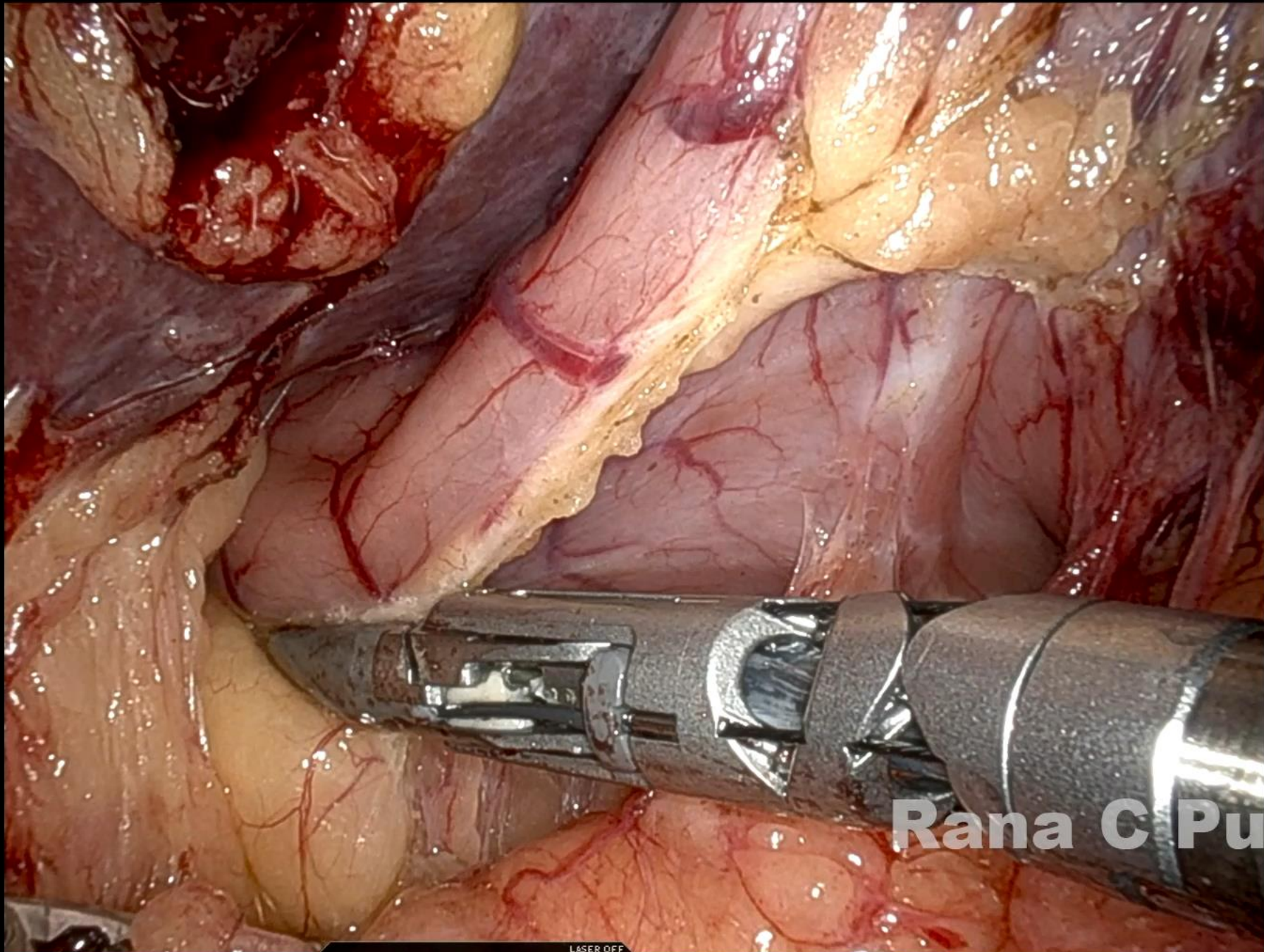


DISCLOSURES

Proctor- Intuitive
Consultant- Medtronic
Speaker- Conmed.

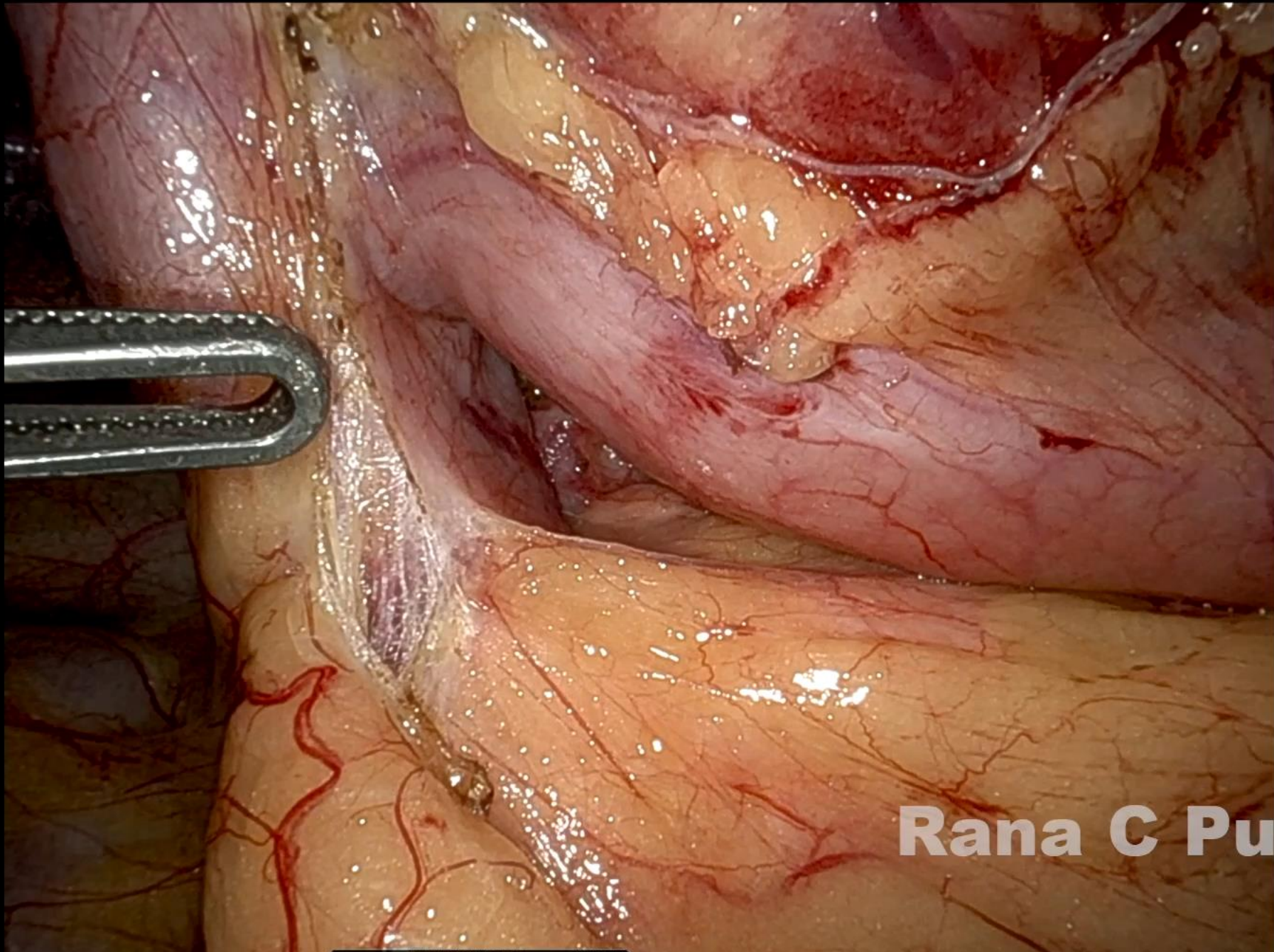


Rana C Pullatt



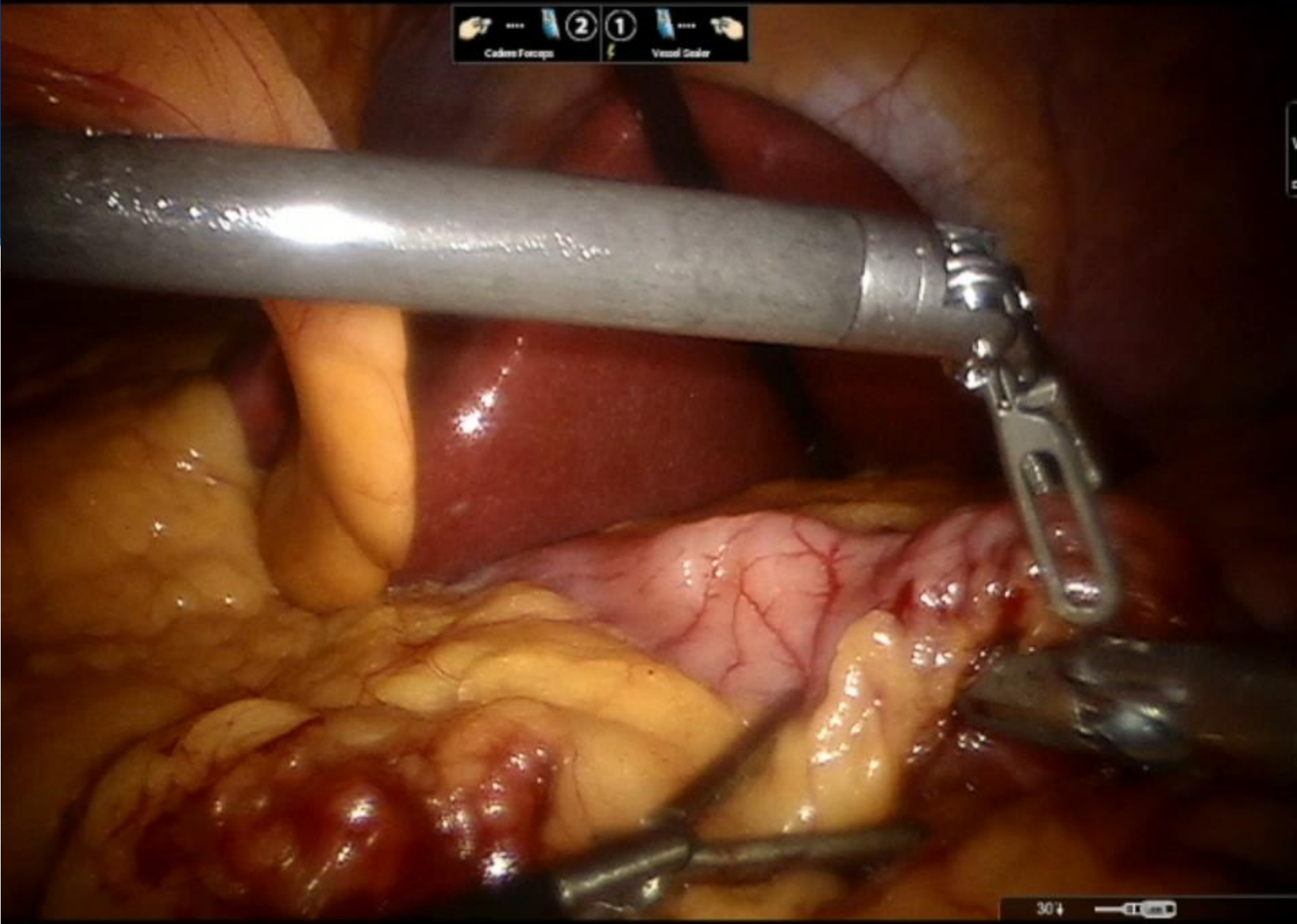
Rana C Pullatt

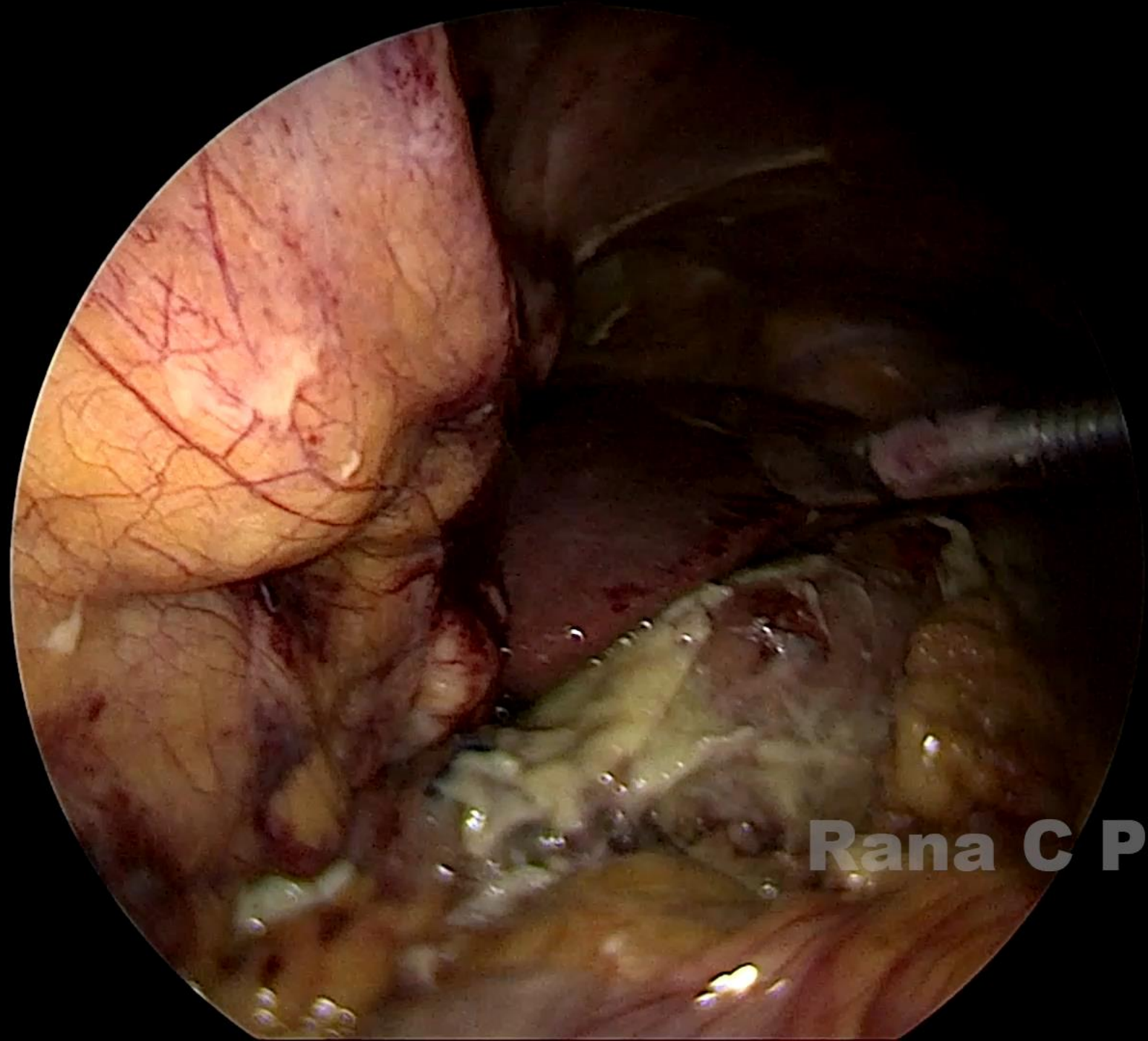
L 1 CADIERE FORCEPS 2 18° REV 5° R 1x 30° LASER OFF 3 R VESSEL SEALER EXTEND R CUT 4 CADIERE FORCEPS



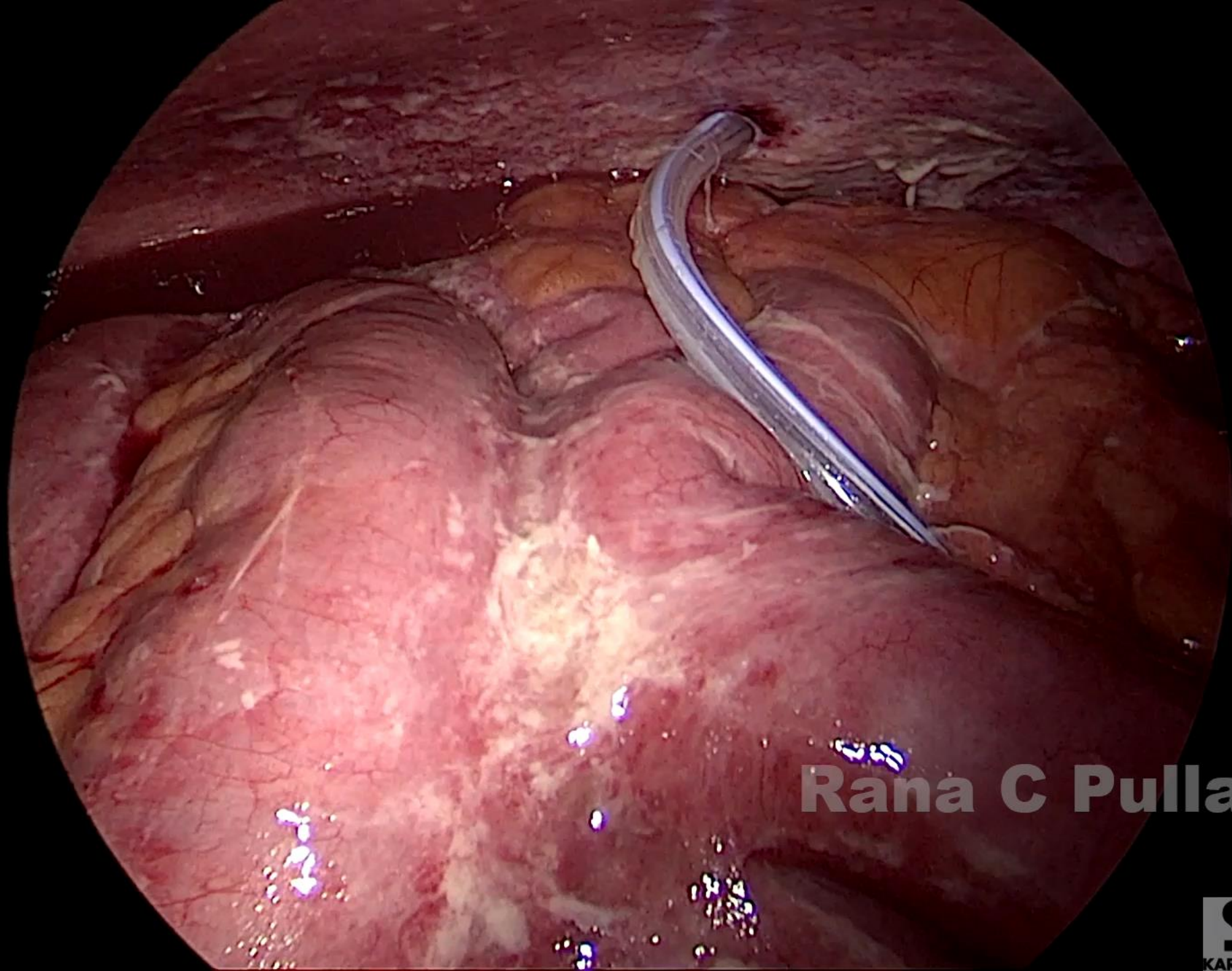
Rana C Pullatt

L 1 CADIERE FORCEPS	NOT PAIRED WITH TABLE LASER OFF 2 [Navigation icons] 1x 30°	3 R VESSEL SEALER EXTEND R CUT R COAG	4 CADIERE FORCEPS
------------------------	---	---	-------------------





Rana C Pullatt



Rana C Pullatt

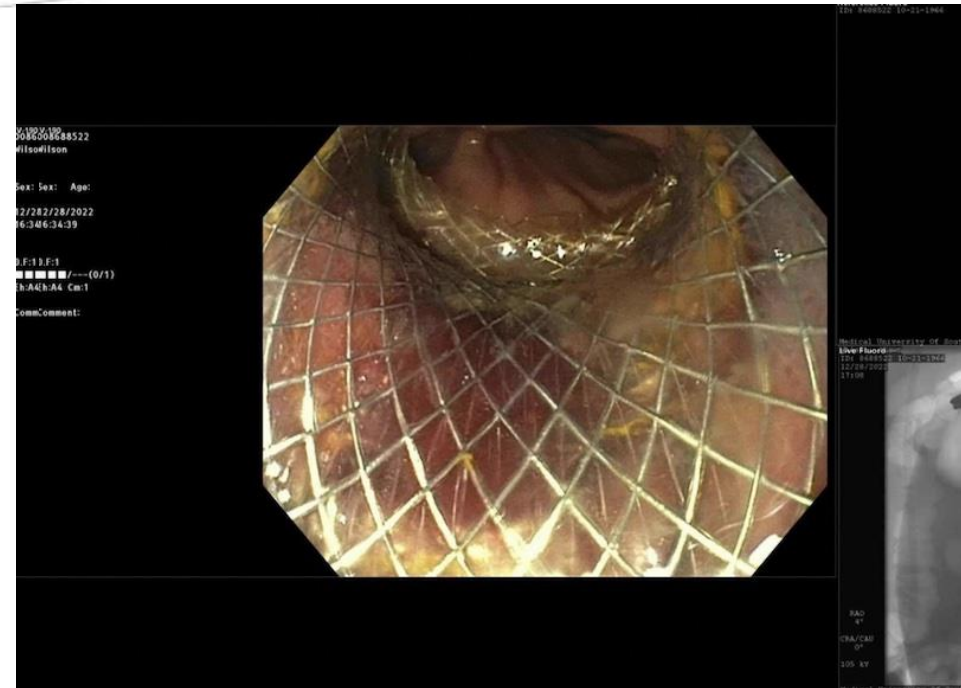
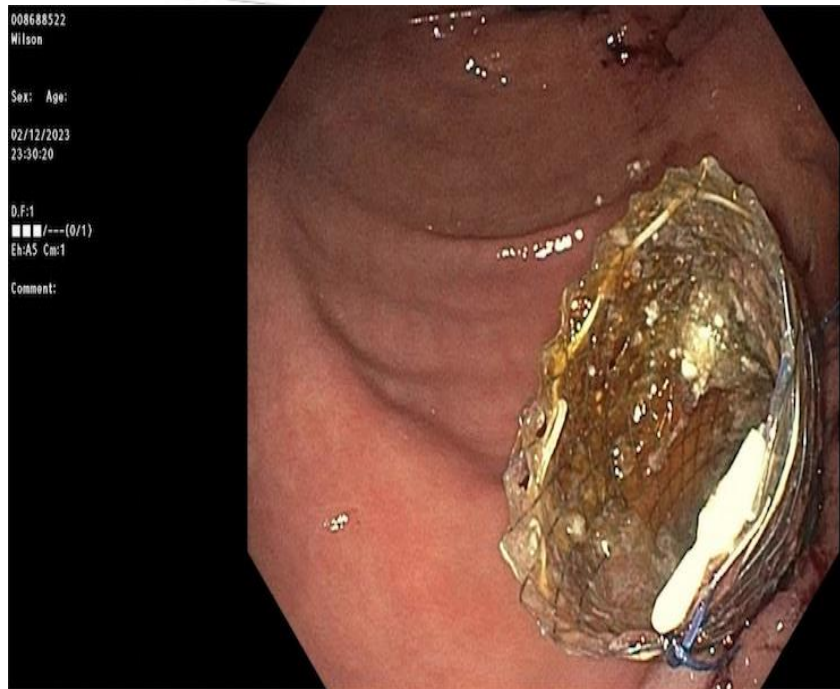SADI Stent?



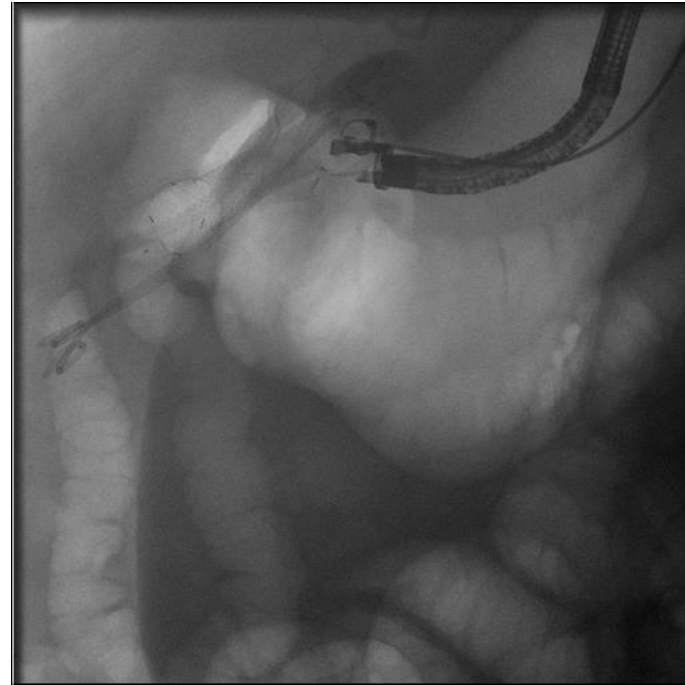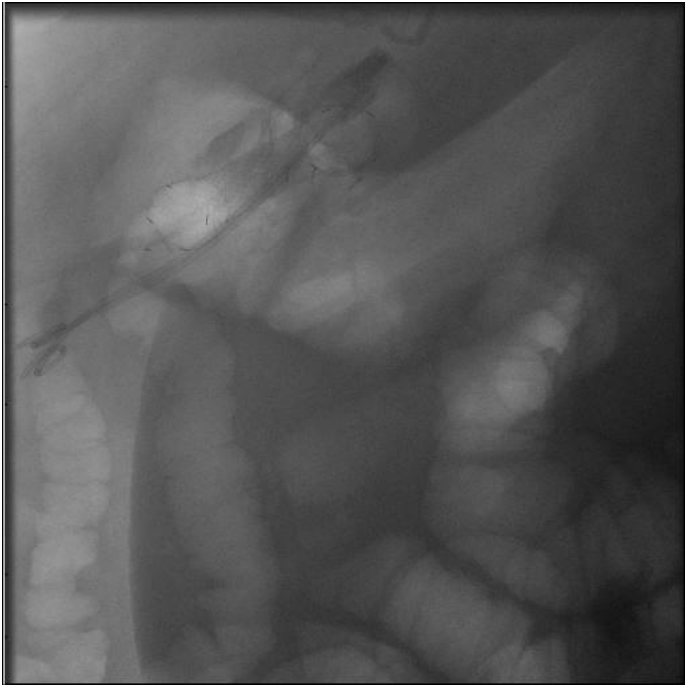
Fully covered TTS Stent- 20mm diameter x 10cm length.

Double pigtail – 7 fr x 15cm

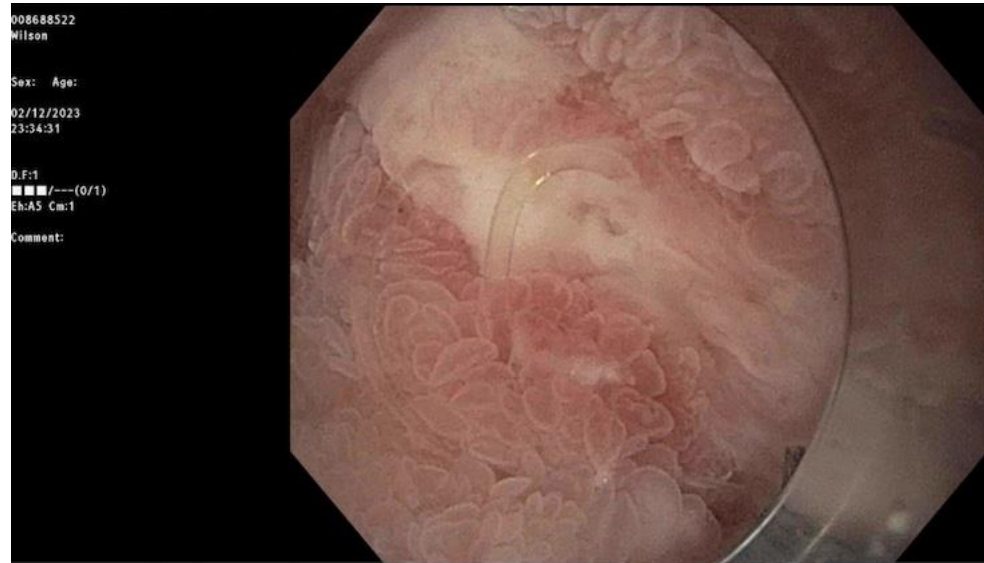Stents

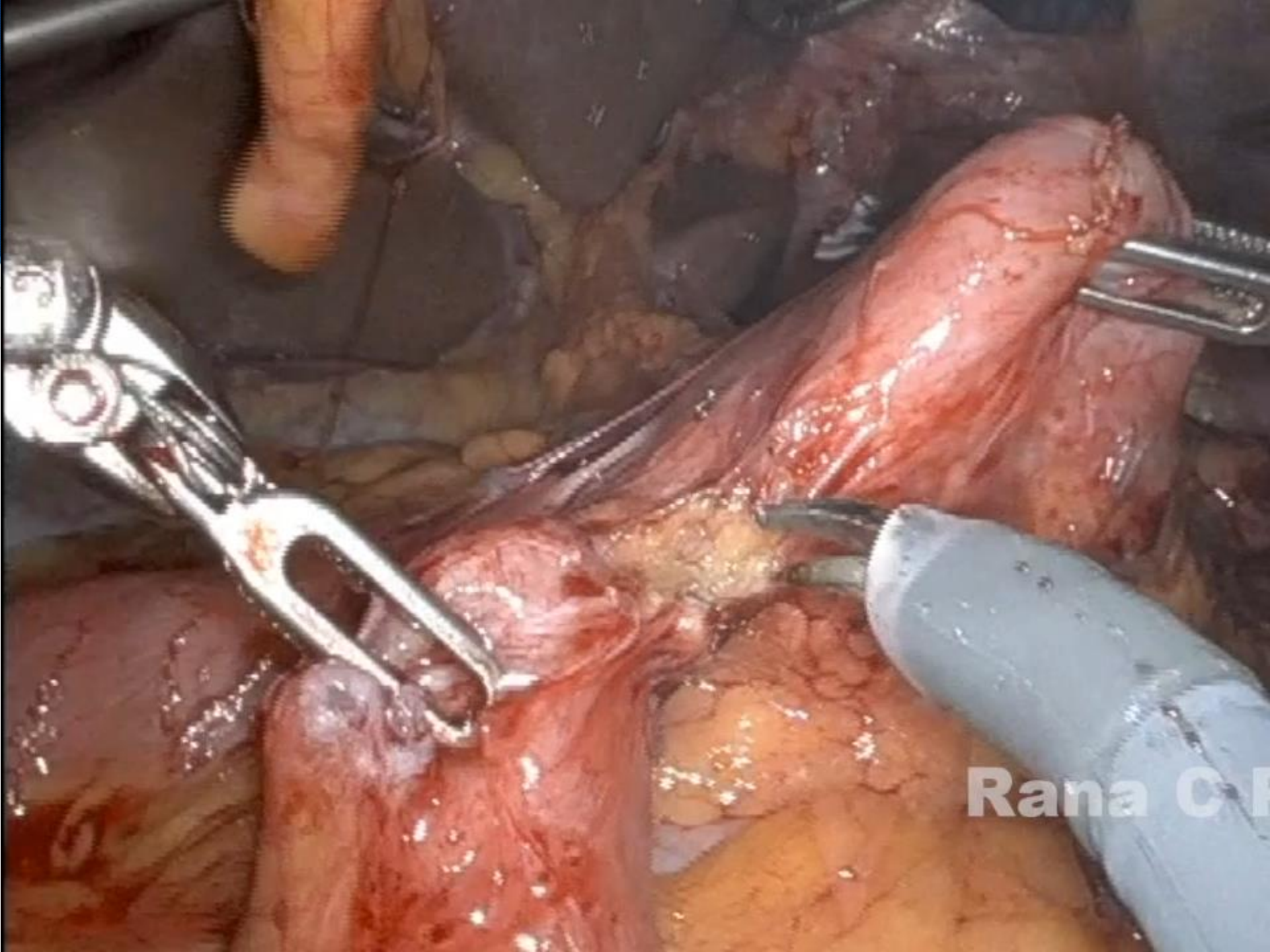


Double pigtail

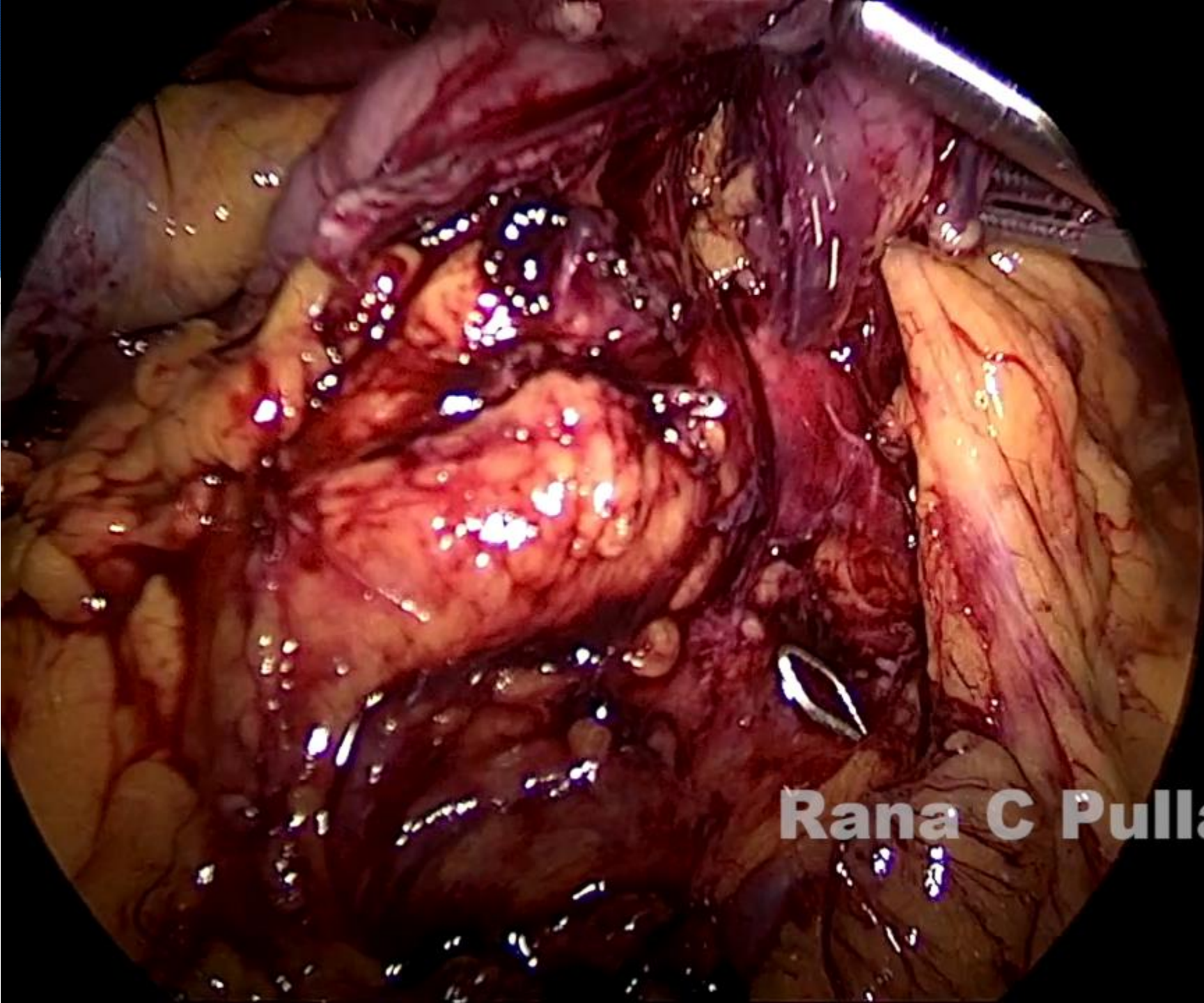


Stent Removal





Rana C. D.



Rana C Pullatt



Thank You

pullattr@gmail.com