

Case Conundrum

A lot of famous surgeons.....

Many titles.....

Question 1

Patient 40 years old who had a gastric bypass 15 years ago BMI 50 → BMI 30 → 3 pregnancy in the last 6 years → BMI 45

- DM resolved after 1 year and now recurred without need for insulin
- Hypertension remained stable since prior to the 1st operation
- No GERD symptoms
- More hungry + 70% restriction lost
- Optimal dietary and behavioral change

Question 1

Patient 40 years old who had a gastric bypass 15 years ago BMI 50 → BMI 30 → 3 pregnancy in the last 6 years → BMI 45

- DM resolved after 1 year and now recurred without need for insulin
- Hypertension remained stable since prior to the 1st operation
- No GERD symptoms
- More hungry + 70% restriction lost
- Optimal dietary and behavioral change

- OR report:
 - Laparoscopic retrocolic/retrogastric bypass
 - 6 cm pouch over 30fr bougie with hand sewn 20mm GJ
 - 100cm BPL / 100cm Roux limb

Question 1

Patient 40 years old who had a gastric bypass 15 years ago BMI 50 → BMI 30 → 3 pregnancy in the last 6 years → BMI 45

- DM resolved after 1 year and now recurred without need for insulin
- Hypertension remained stable since prior to the 1st operation
- No GERD symptoms
- More hungry + 70% restriction lost
- Optimal dietary and behavioral change

- OR report:
 - Laparoscopic retrocolic/retrogastric bypass
 - 6 cm pouch over 30fr bougie with hand sewn 20mm GJ
 - 100cm BPL / 100cm Roux limb
- UGI
 - Anatomy consistent with gastric bypass
 - No leak or obstruction

Question 1

Patient 40 years old who had a gastric bypass 15 years ago BMI 50 → BMI 30 → 3 pregnancy in the last 6 years → BMI 45

- DM resolved after 1 year and now recurred without need for insulin
- Hypertension remained stable since prior to the 1st operation
- No GERD symptoms
- More hungry + 70% restriction lost
- Optimal dietary and behavioral change

- OR report:
 - Laparoscopic retrocolic/retrogastric bypass
 - 6 cm pouch over 30fr bougie with hand sewn 20mm GJ
 - 100cm BPL / 100cm Roux limb
- UGI
 - Anatomy consistent with gastric bypass
 - No leak or obstruction
- EGD
 - Non-erosive LA grade A esophagitis
 - No hiatal hernia
 - Mildly dilated pouch 6x3cm with 30mm GJ anastomosis

Question 1

Patient 40 years old who had a gastric bypass 15 years ago BMI 50 → BMI 30 → 3 pregnancy in the last 6 years → BMI 45

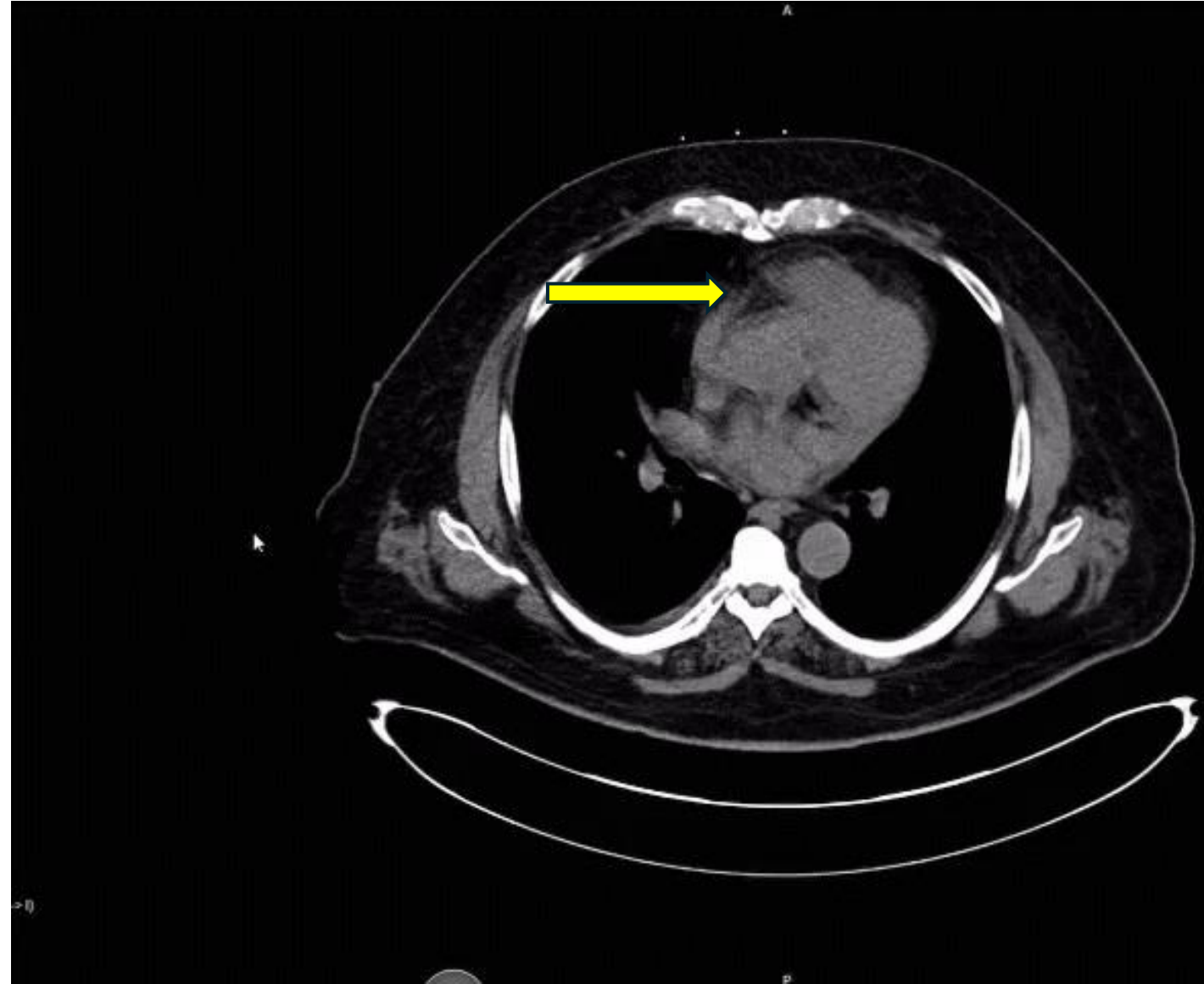
- DM resolved after 1 year and now recurred without need for insulin
- Hypertension remained stable since prior to the 1st operation
- No GERD symptoms
- More hungry + 70% restriction lost
- Optimal dietary and behavioral change

- OR report:
 - Laparoscopic retrocolic/retrogastric bypass
 - 6 cm pouch over 30fr bougie with hand sewn 20mm GJ
 - 100cm BPL / 100cm Roux limb
- UGI
 - Anatomy consistent with gastric bypass
 - No leak or obstruction
- EGD
 - Non-erosive LA grade A esophagitis
 - No hiatal hernia
 - Mildly dilated pouch 6x5cm with 2.5cm GJ anastomosis

- Medication intolerance
- She is very frustrated and wants **durable but safe solution because she will pay out of pocket**

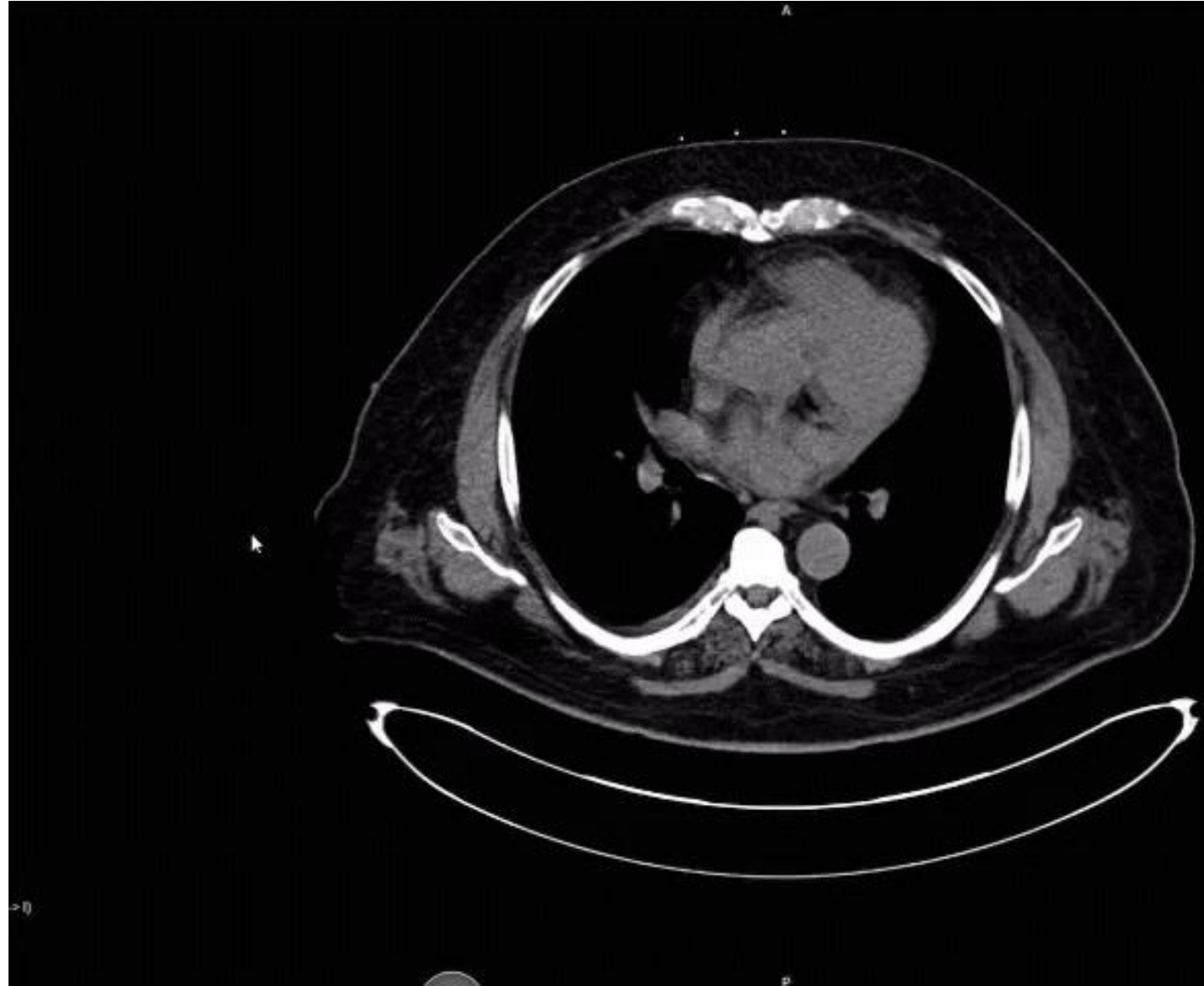Cleveland Clinic Abu Dhabi

- 63 y/o BMI 43.
CKD, HTN, DM
- Referred 2
months post
LSG for a “leak”
- EGD normal
Sleeve with leak



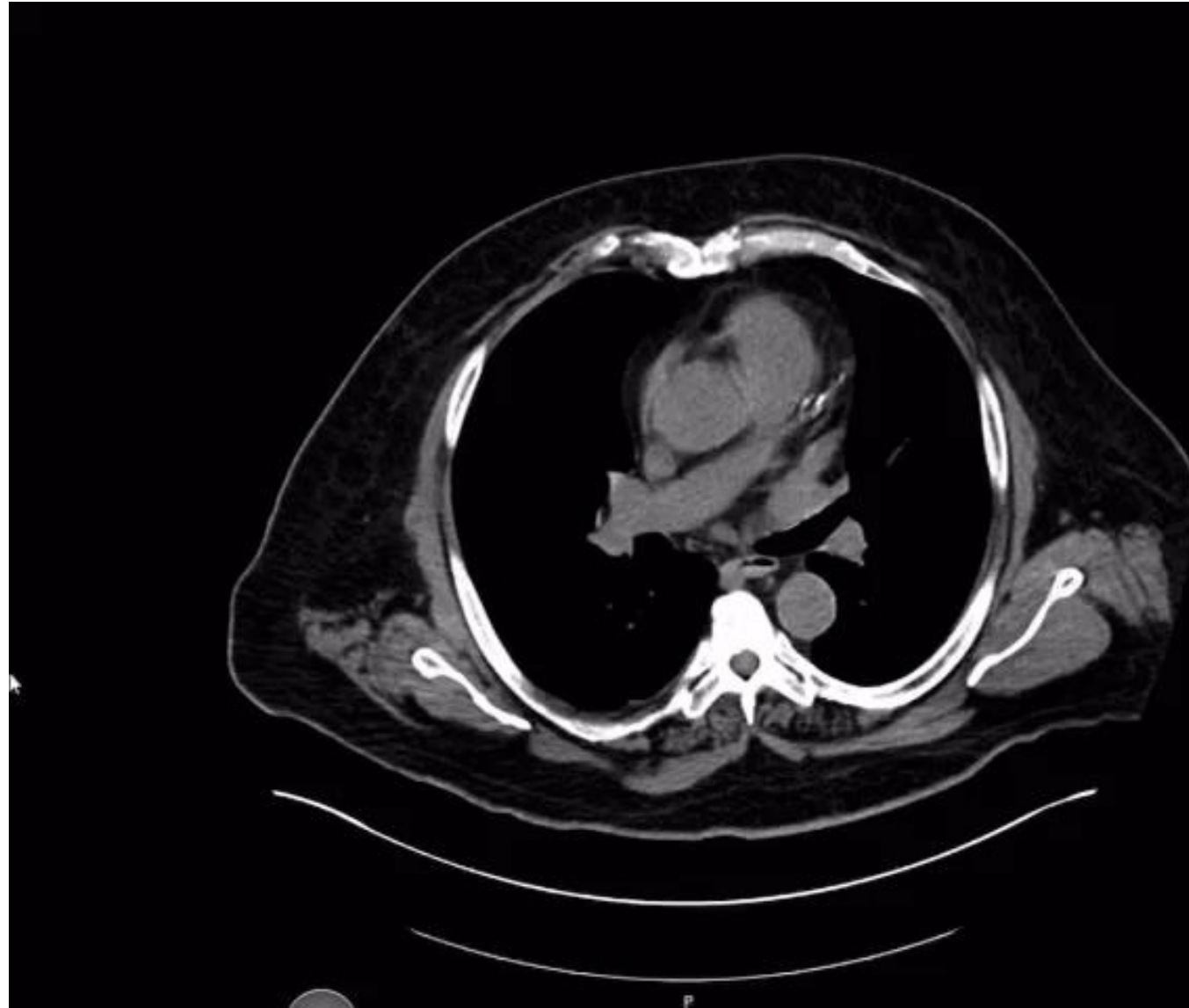
Cleveland Clinic Abu Dhabi

- 63 y/o BMI 43.
CKD, HTN, DM
- Referred 2
months post
LSG for a “leak”
- EGD normal
Sleeve with leak



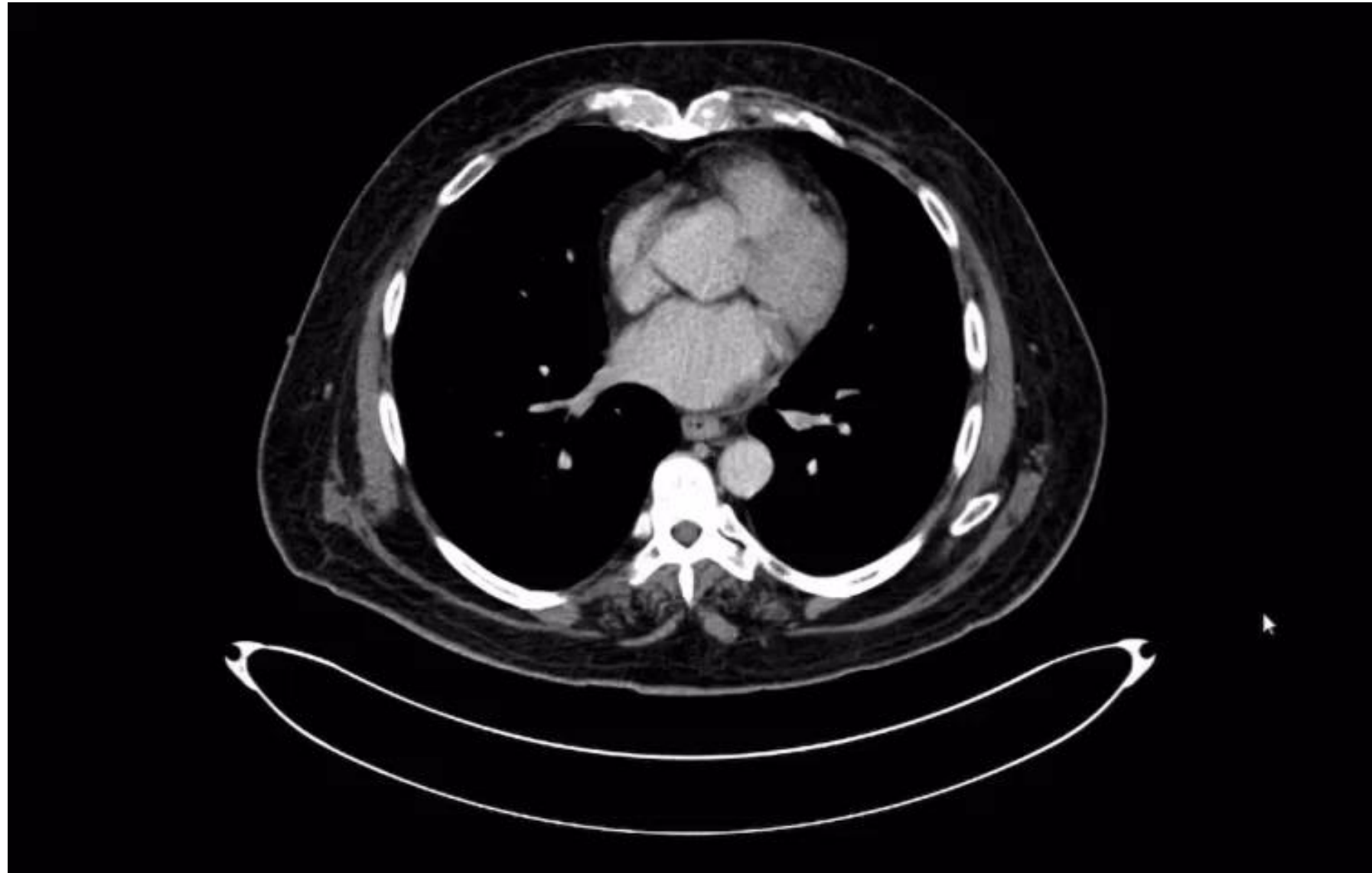
Cleveland Clinic Abu Dhabi

- Management:
 - EGD pigtail
 - IR drain
- Gets better and discharged




Cleveland Clinic Abu Dhabi

- Did well for weeks
- Both drains removed
- Readmission after 3 months
- Abdominal pain + fever




Cleveland Clinic Abu Dabi

- EGD same with re-opening of the leak defect
- Pigtail placed and came out in antrum



Cleveland Clinic Abu Dhabi

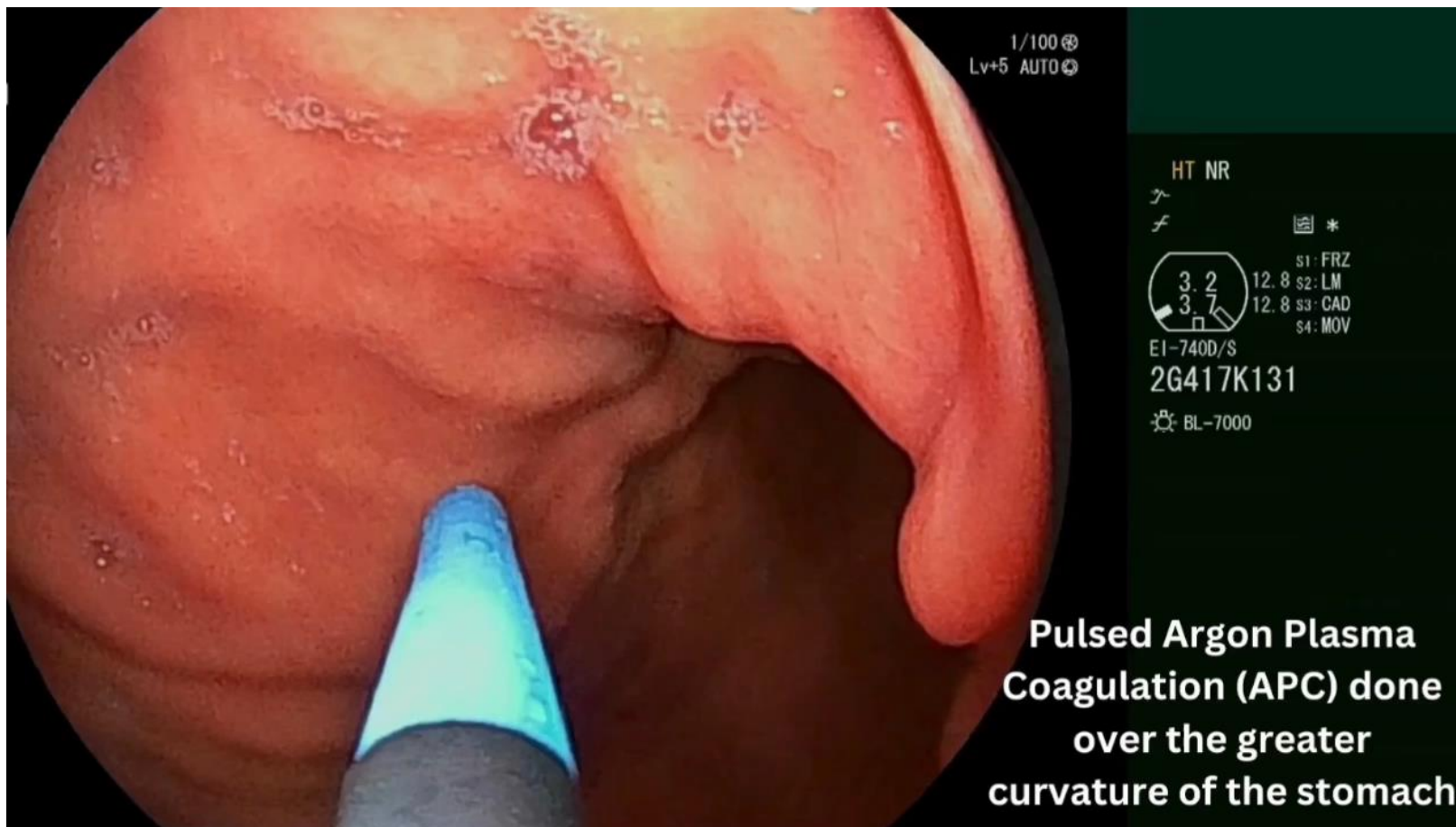
- Management:



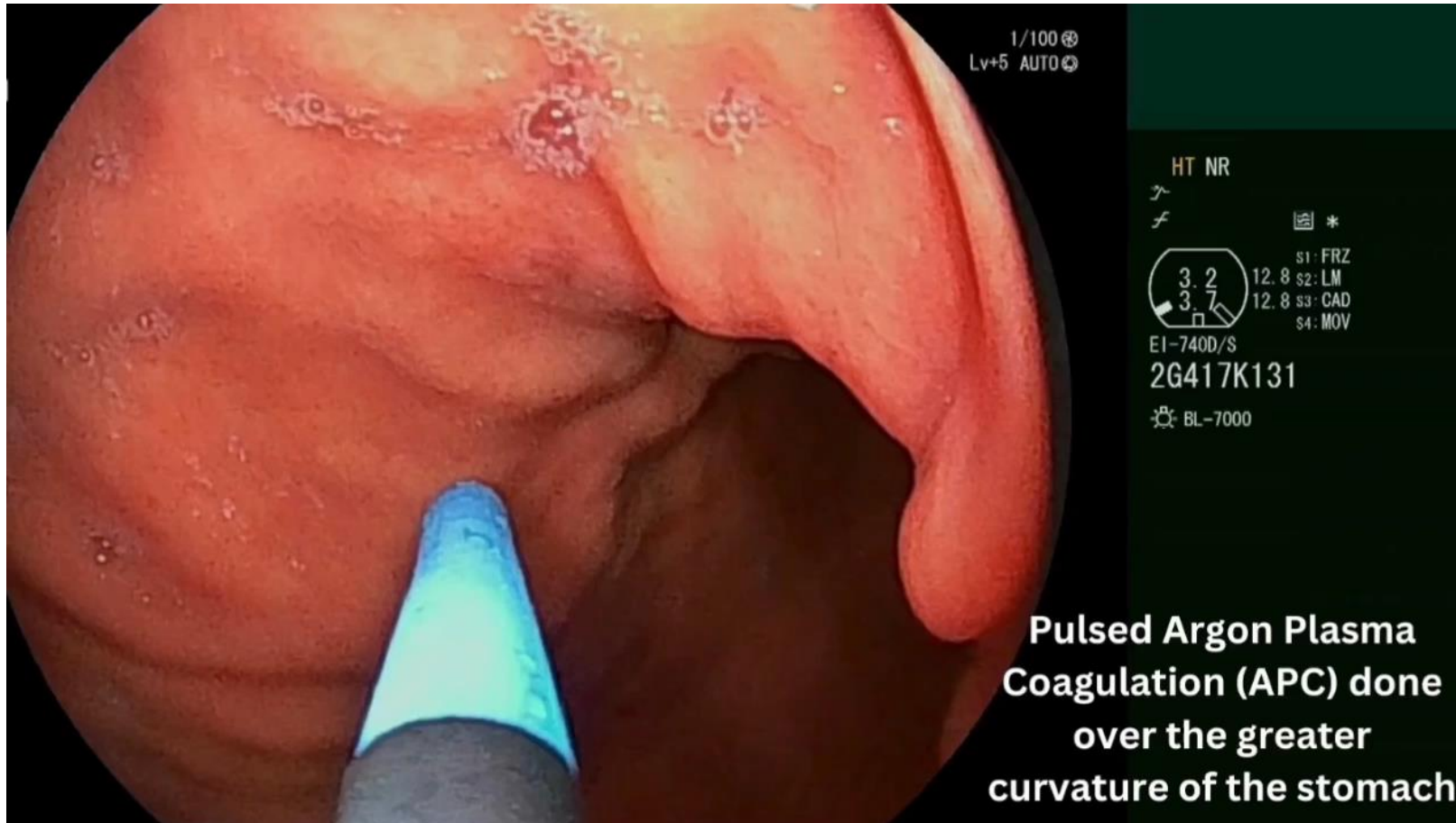
Vote



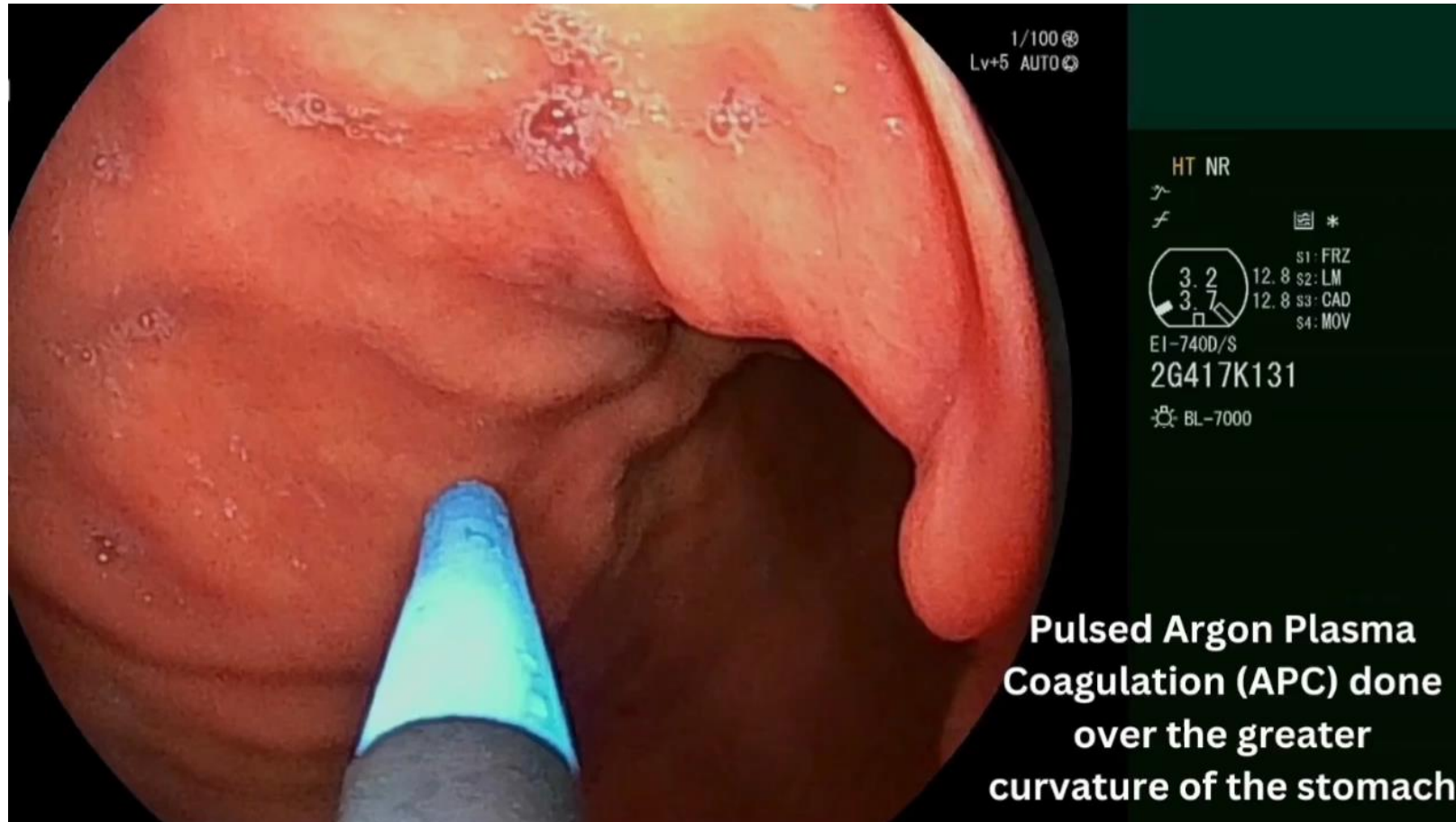
APC + ESG



Readmission



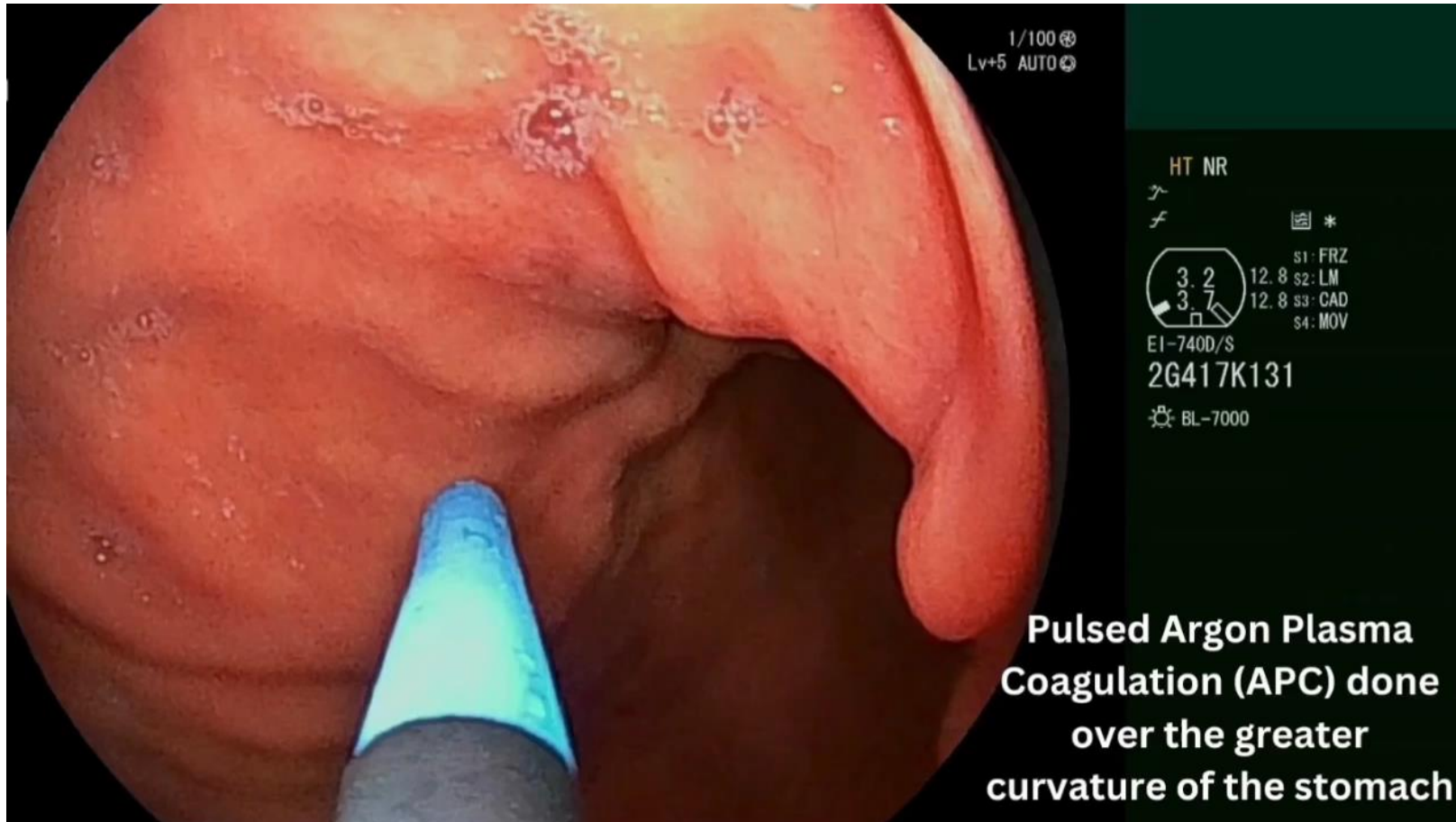
Diagnostic Laparoscopy



Vote



Management



Question 3

- 69 y/o female 4 years after OAGB
 - 34 fr bougie
 - 4cm GJ
 - BP limb 180 cm (no record of SB counting)
- Preop metabolic syndrome resolved
- Off all medications
- No GERD symptoms
- BMI 33 → 17

Question 3

- 69 y/o female 4 years after OAGB
 - 34 fr bougie
 - 4cm GJ
 - BP limb 180 cm (no record of SB counting)
- Preop metabolic syndrome resolved
- Off all medications
- No GERD symptoms
- BMI 33 → 17
- Feels tired with constant low energy
- Labs show moderate malnutrition
- Iron deficiency anemia with iron infusion
- Referred back to you
- Patient frustrated. Loves her OAGB weight loss but frustrated getting old with poor QOL

Question 3

- UGI
 - As expected with forward contrast filling
- EGD
 - Irregular z line
 - minimal grade A esophagitis
 - No hiatal hernia

Vote



Question 4

- 45 yo man s/p LSG 4 years ago
- PMH: Crohn's disease (remission for 15 years on biologics)
- BMI 45 → 28

Question 4

- 45 yo man s/p LSG 4 years ago
- PMH: Crohn's disease (remission for 15 years on biologics)
- BMI 45 → 28
- Severe GERD symptoms
- c/o heartburn + regurgitation
- UGI sliding hernia 5 cm
- EGD same with Hill grade 3 with grade A esophagitis (no Barrett)
- Demeester score 32

Vote



History

- 48 y/o male with h/o DM, OSA, and gout
- LSG in 2015 BMI 70 → 45
- Complicated with large PE
- Weight recurrence through covid 45 → 65
- Decent follow up and compliance
- Work up:
 - No hiatal hernia or esophagitis
 - Sleeve looks optimal endoscopically

OAGB: Same Complication, Different Management, Same Outcome

2024 ASMBS Annual Meeting: Excitement in Surgery, How to get out of trouble-Video Session

Enrique Bujanda-Morun MD

Zihan Dong MD

John Mitko MD

Francisco Quinteros MD FACS FASCRS

Rami Lutfi MD FACS FASMBS



Chicago Institute *of*
Advanced Surgery

OAGB: Same Complication, Different Management, Same Outcome

2024 ASMBS Annual Meeting: Excitement in Surgery, How to get out of trouble-Video Session

Enrique Bujanda-Morun MD

Zihan Dong MD

John Mitko MD

Francisco Quinteros MD FACS FASCRS

Rami Lutfi MD FACS FASMBS



Chicago Institute *of*
Advanced Surgery

Vote



OAGB: Same Complication, Different Management, Same Outcome

2024 ASMBS Annual Meeting: Excitement in Surgery, How to get out of trouble-Video Session

Enrique Bujanda-Morun MD

Zihan Dong MD

John Mitko MD

Francisco Quinteros MD FACS FASCRS

Rami Lutfi MD FACS FASMBS



Chicago Institute *of*
Advanced Surgery

OAGB: Same Complication, Different Management, Same Outcome

2024 ASMBS Annual Meeting: Excitement in Surgery, How to get out of trouble-Video Session

Enrique Bujanda-Morun MD

Zihan Dong MD

John Mitko MD

Francisco Quinteros MD FACS FASCRS

Rami Lutfi MD FACS FASMBS



Chicago Institute *of*
Advanced Surgery