

MANAGEMENT OF A LARGE SUBCARDIAL DIVERTICULUM IN SLEEVE GASTRECTOMY: TECHNICAL TIPS

Francesco Frattini, MD
ISTITUTO AUXOLOGICO ITALIANO,
IRCCS, MILANO

Research Center in Bariatric
Surgery

Division of General Surgery
(Head: Prof. Gianlorenzo Dionigi)



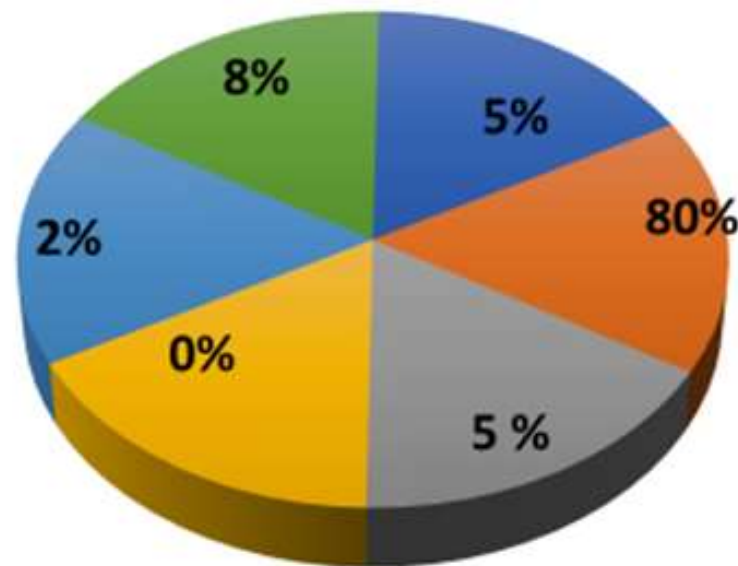
IFSO

NAPOLI 2023

In accordance with «EACCME criteria for the Accreditation of Live Educational Events», please disclose whether you have or you have not any conflict of interest with the companies:

I have no potential conflict of interest to report

CASE MIX
DISCLOSURE
100
cases/year



RYGB

SG

OAGB

DS/SADI-S

REVISIONAL

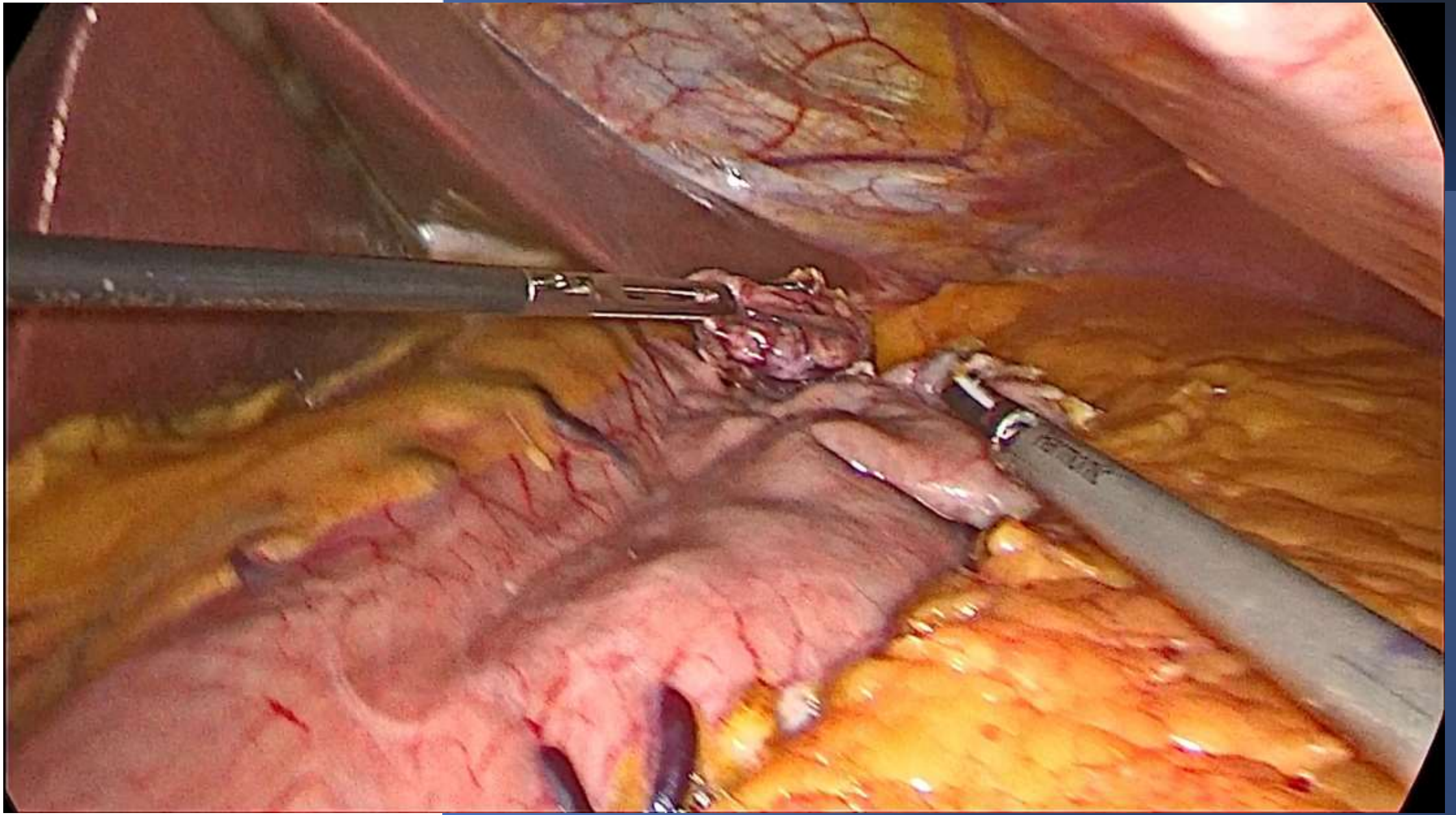
ENDOSCOPIC



NAPOLI
2023



- 60-year-old female, BMI 47 kg/m²
- Hypertension, OSAS
- Preoperative esophagogastroduodenoscopy
- At the upper GI series gastric diverticulum of the fundus





Regular postoperative UGI series

Discharge on third postoperative day

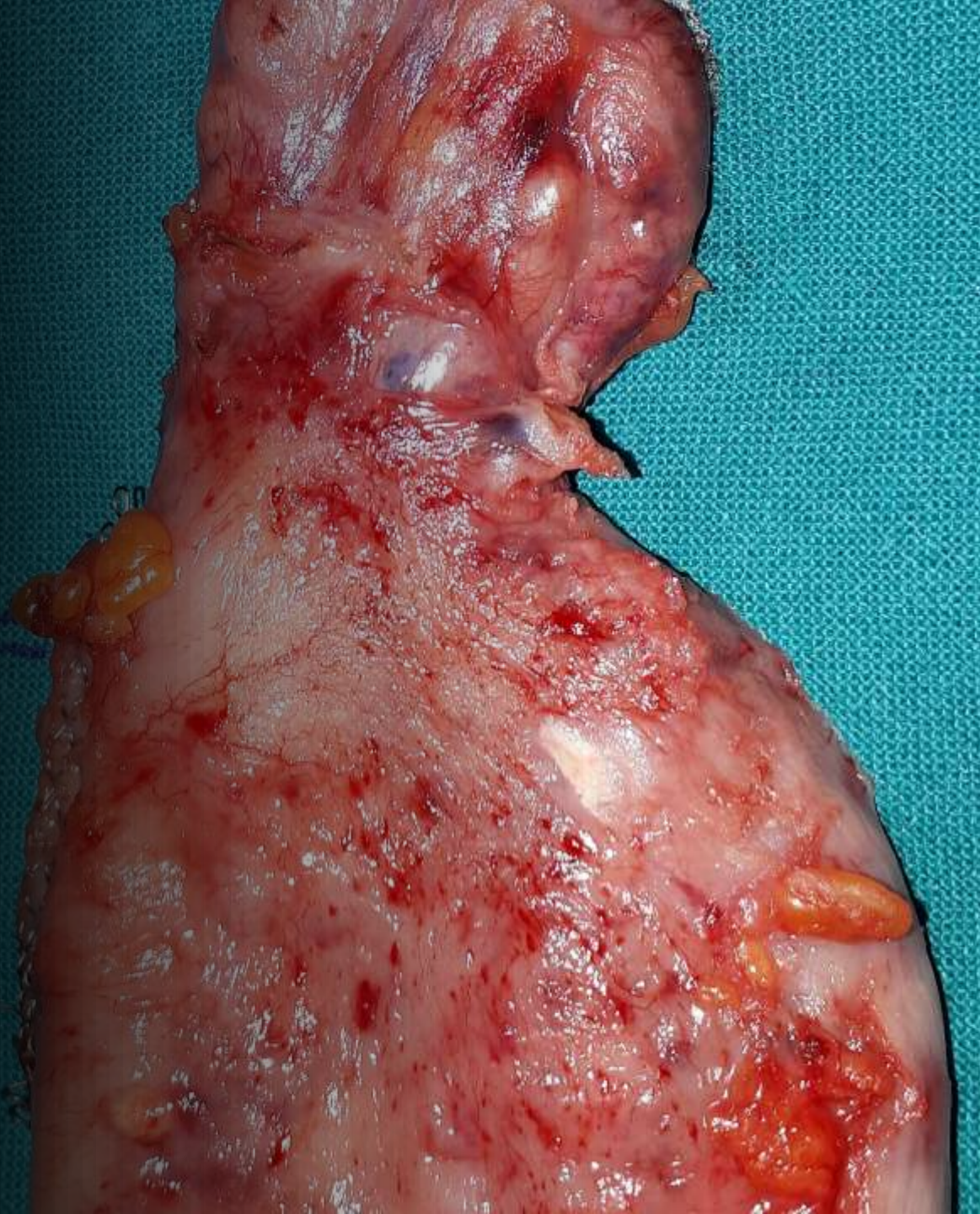
Regular postoperative course

6-months follow-

EWL 40%



- Accurate preoperative work-up
- Careful dissection of the diverticulum
- Complete resection of the diverticulum together with the gastric fundus





Thank you

