



Laparoscopic Sleeve Gastrectomy in a Patient with Situs Invertus Totalis

Mohammed Al Sibani MD,FRCSC

*Senior consultant
Bariatric & Metabolic Surgery Unit
Armed Forces Hospital- Oman*



Nothing to Disclose



Clinical History

- 40 years old, Female
- BMI: 45 kg/m²

- PMH:
 - ✓ Situs Invertus Totalis
 - ✓ Diagnosed during investigation for renal calculi



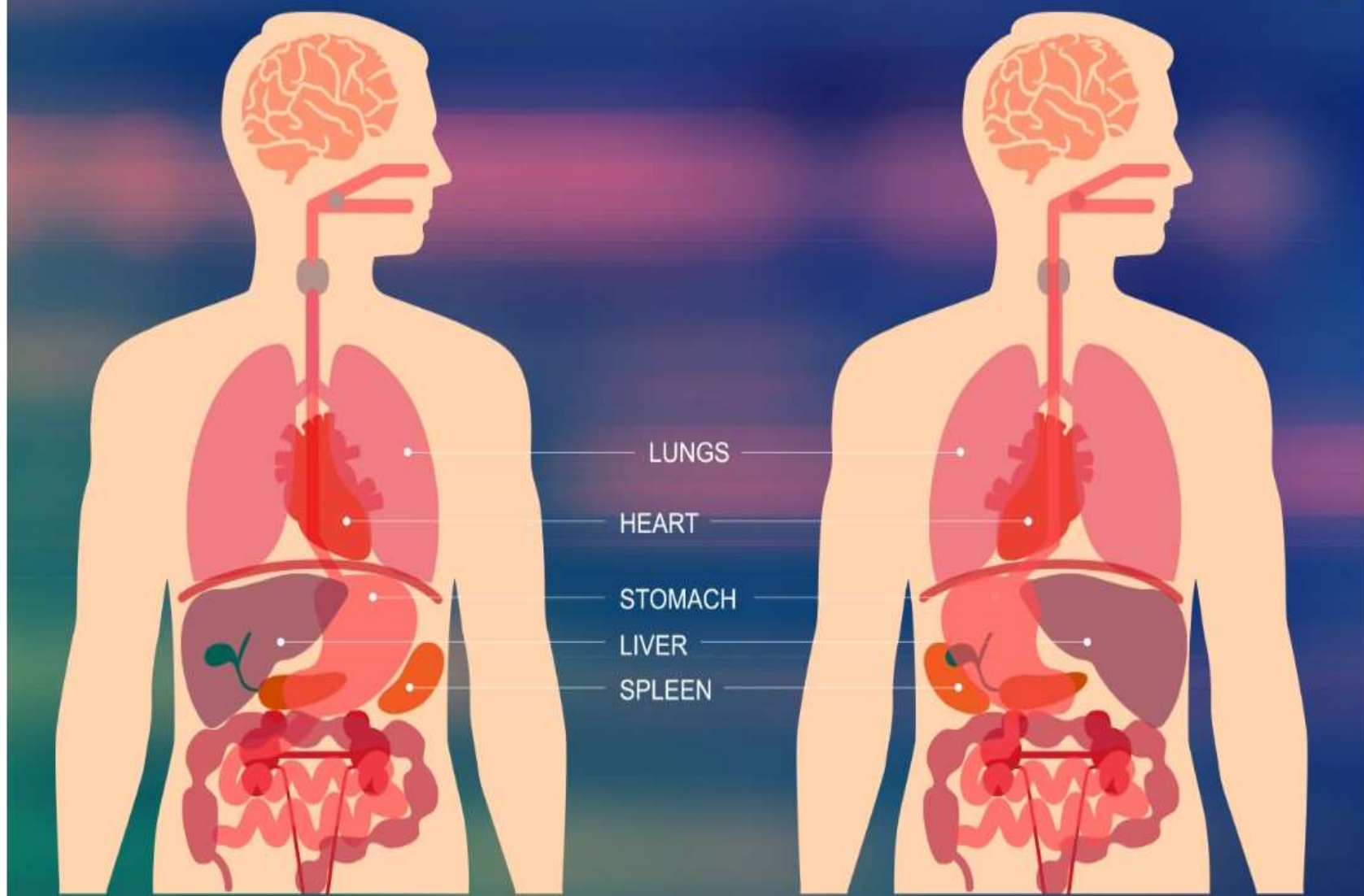
Situs Invertus Totalis

- Rare genetic condition (autosomal recessive gene)
- Prevalence : 1 in 10,000
- Characterized by Inverted anatomy and possible aberrant structures
- Difficulty in performing laparoscopic procedures with inverted anatomy



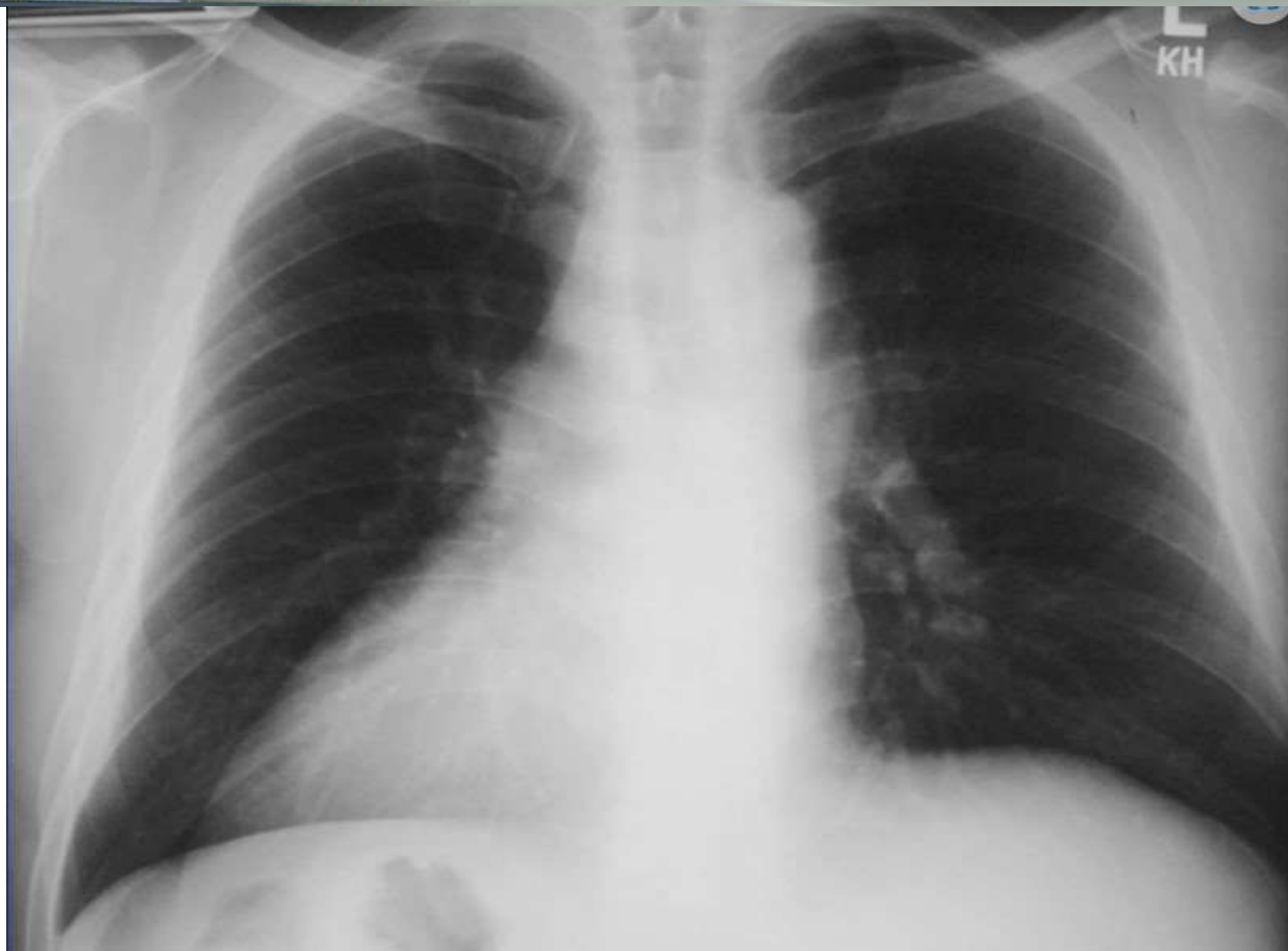Normal

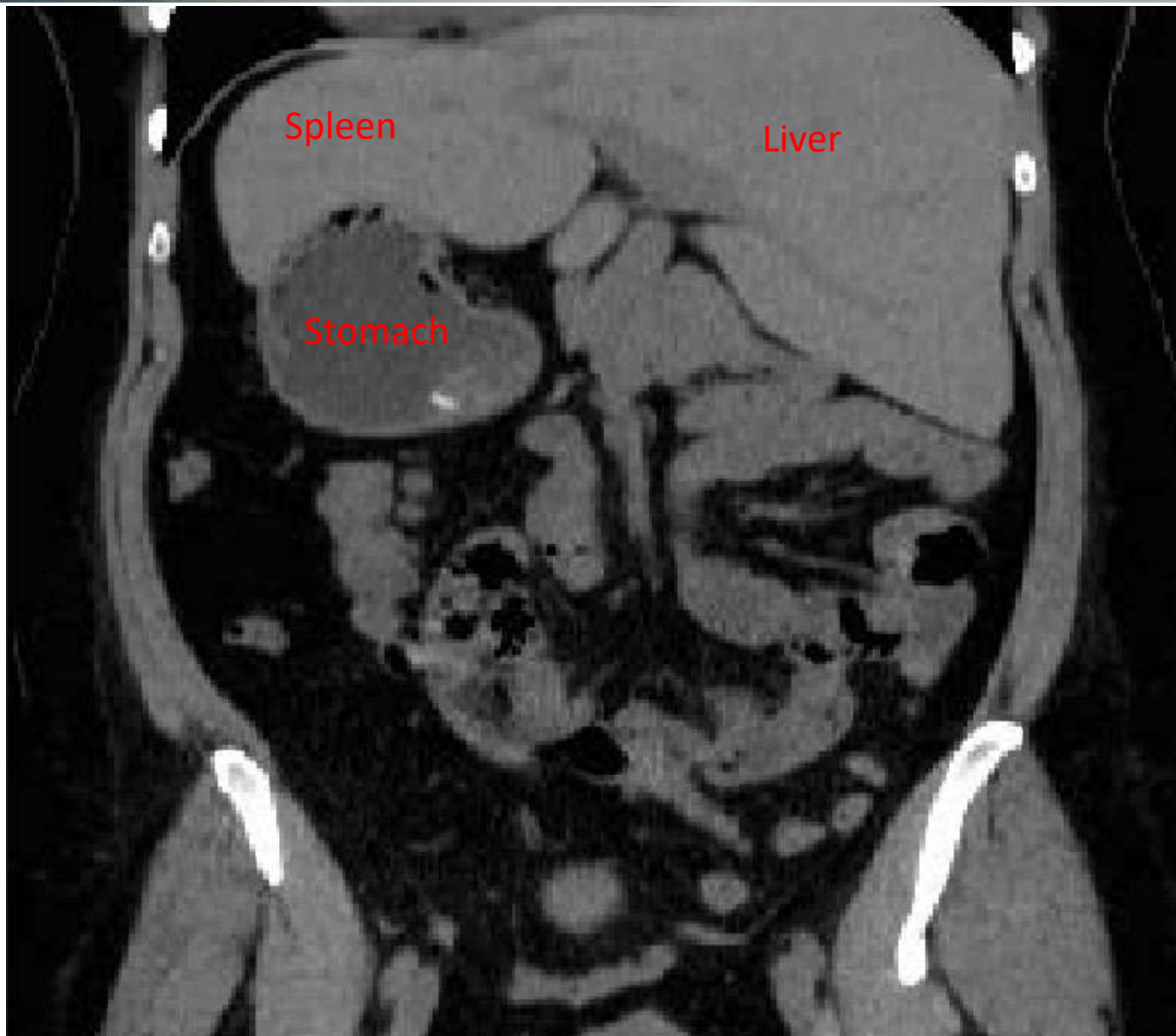Situs Inversus





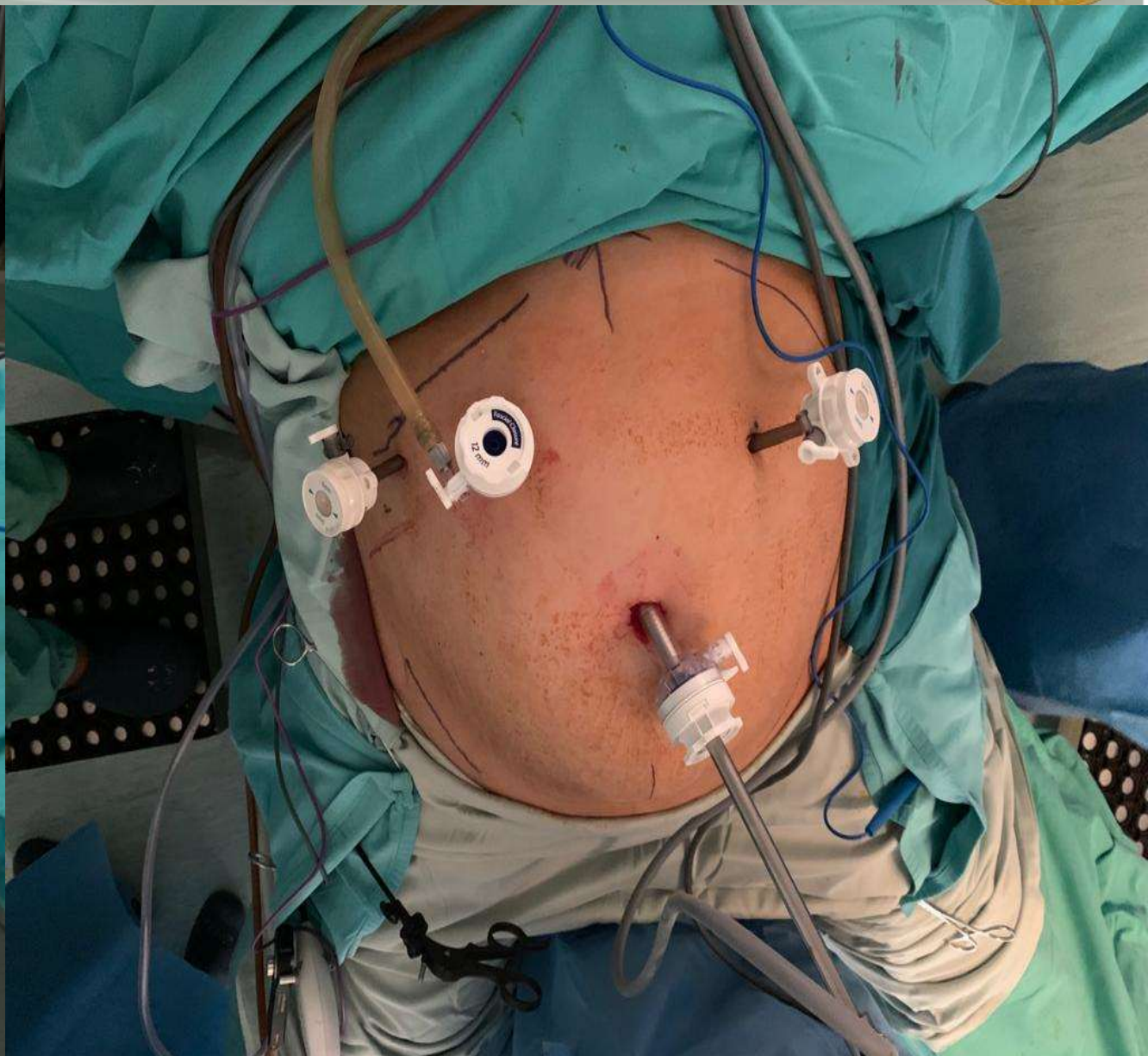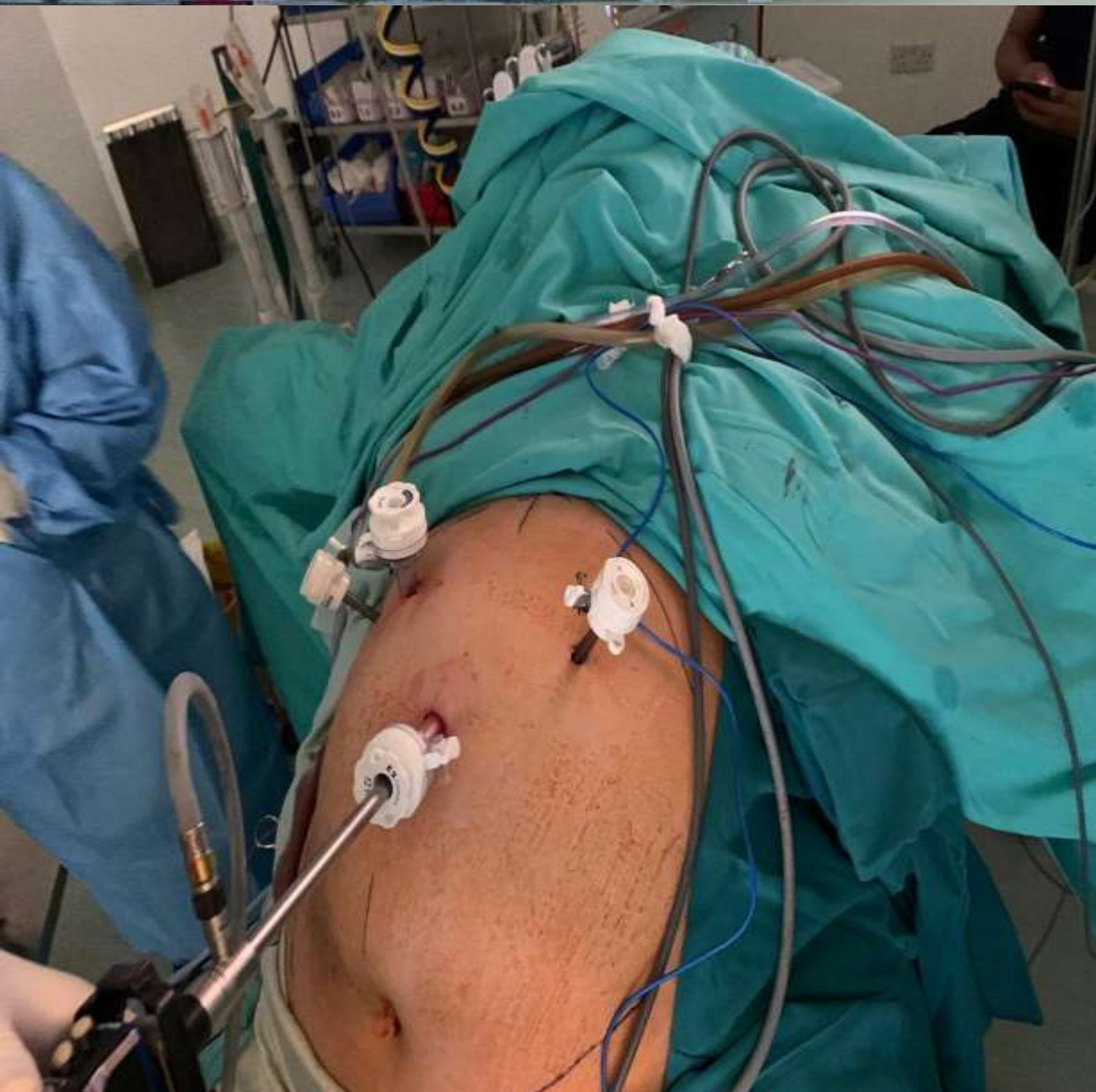Preoperative Evaluation





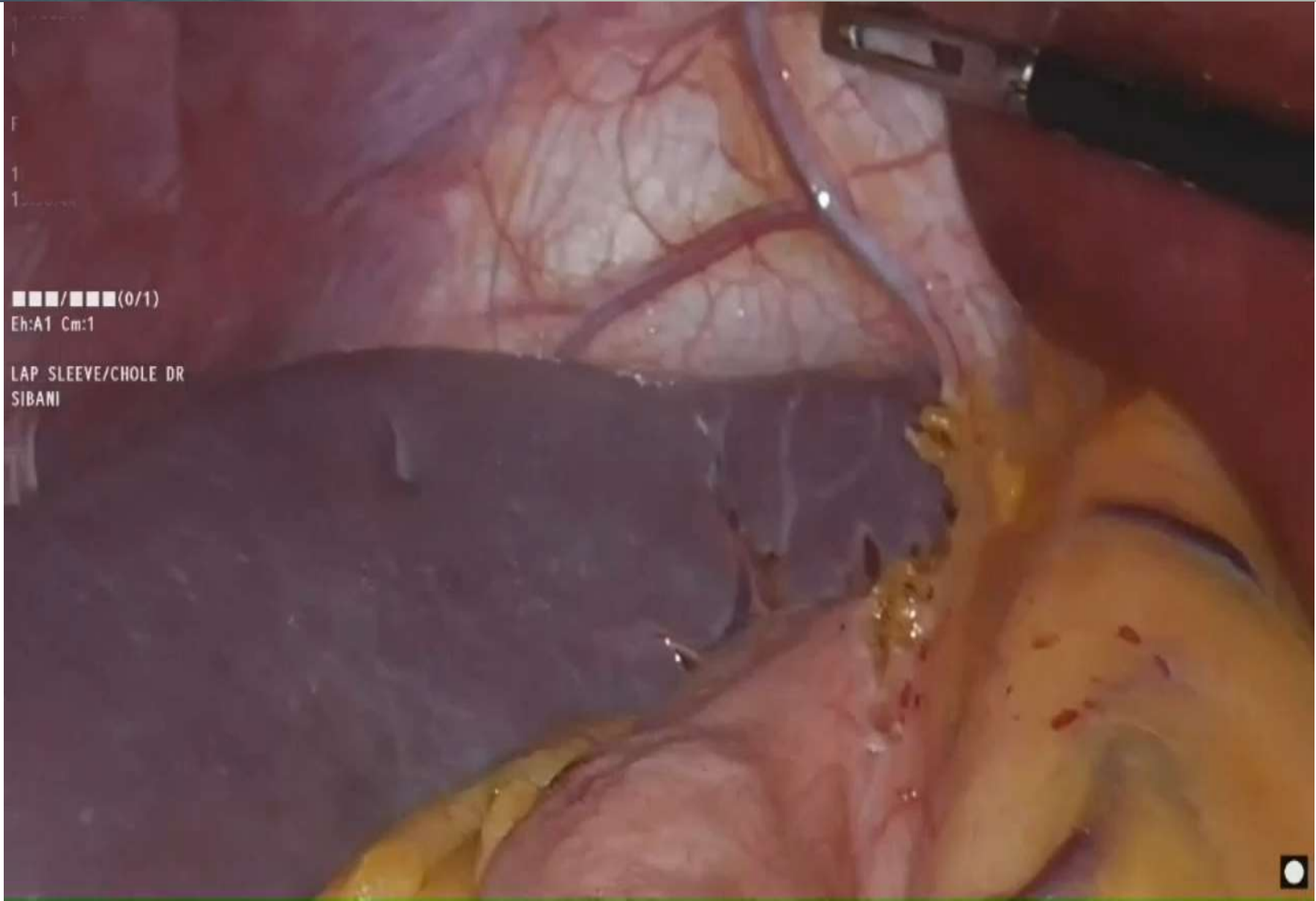


Perioperative Preparation





Operative Procedure



■■■■/■■■■(0/1)
Eh:A1 Cm:1

LAP SLEEVE/CHOLE DR
SIBANI





Postoperative

- Close Monitoring and Follow-up
- Manage the postoperative pain which might be at unusual location .
- Uneventful postoperative course
- Significant weight loss at one-year follow-up



Conclusion



LSG in SIT

- Preoperative planning and imaging
- Modification of surgical technique : ports position , patient position , instruments use , traction etc
- Care and attention to the inverted anatomy and aberrant structures



Thank You