



A whole variety of disasters: Get your Popcorn!

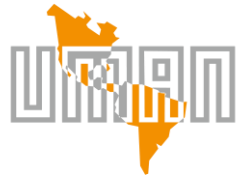Felipe J. Cantú Jr. MD FACS FASMBS

Bariatric & Metabolic Surgery Professor

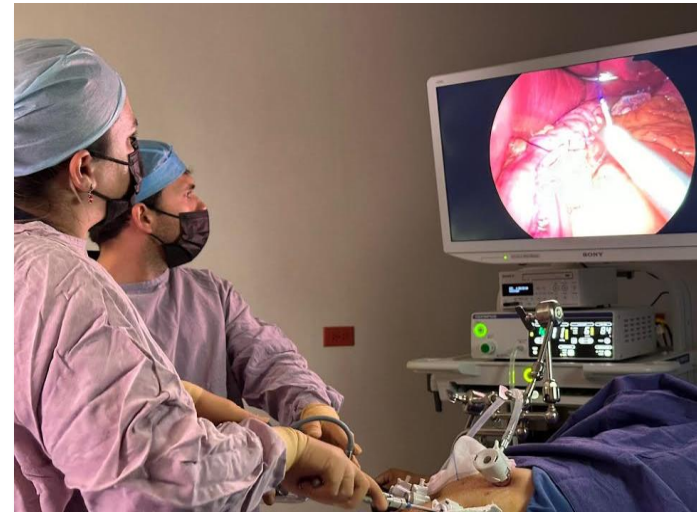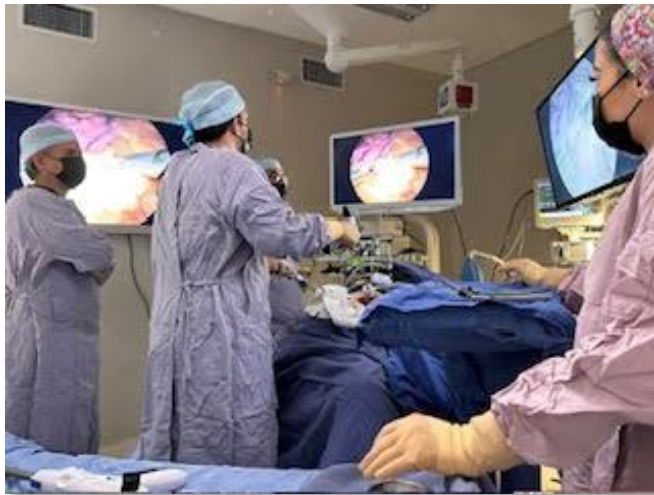IFSO LAC Fellowship Program

Universidad México Americana del Norte UMAN

Reynosa, Tamaulipas, México.

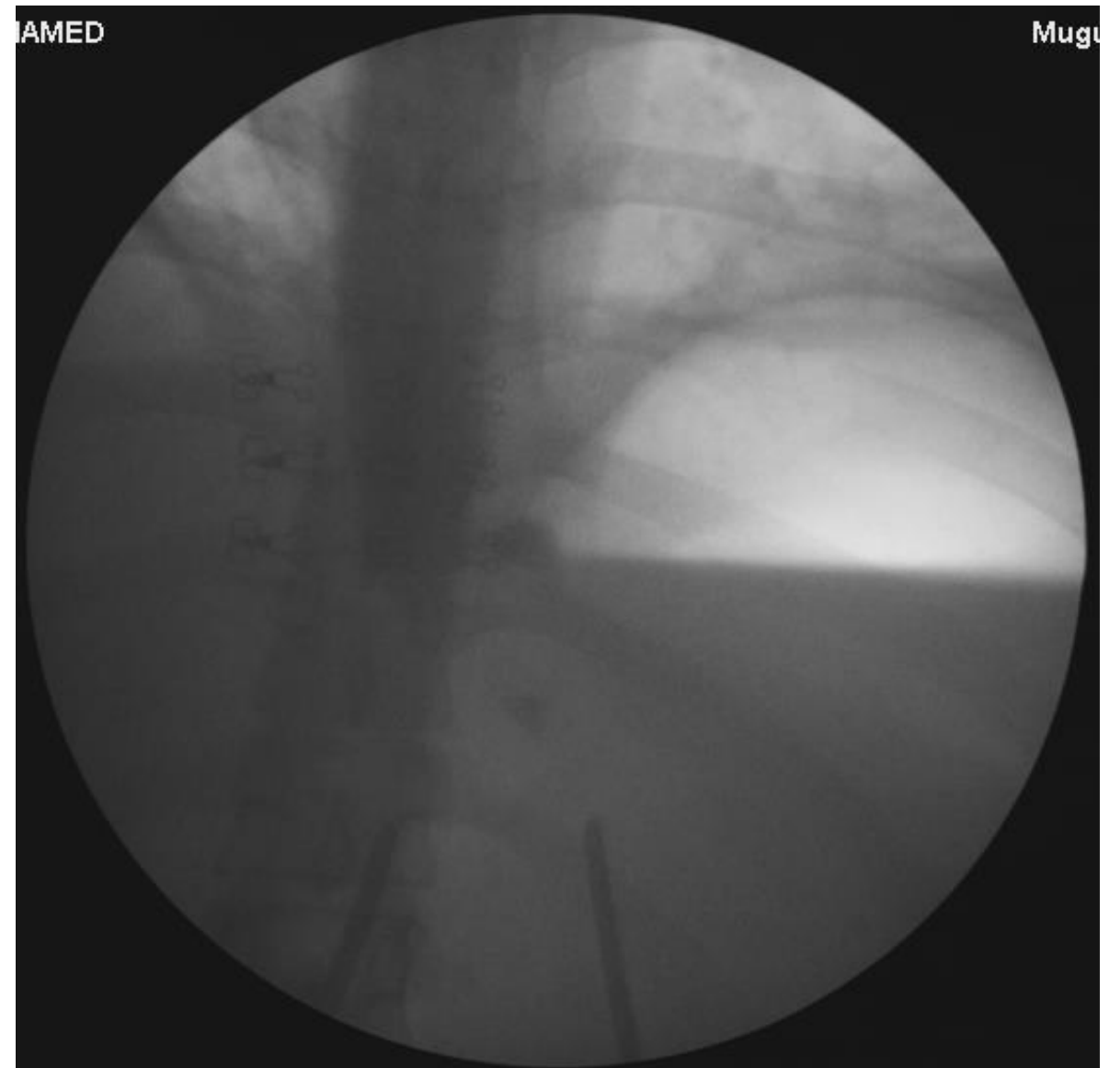
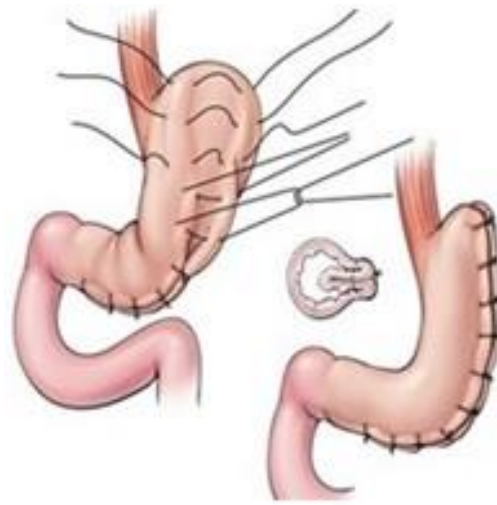

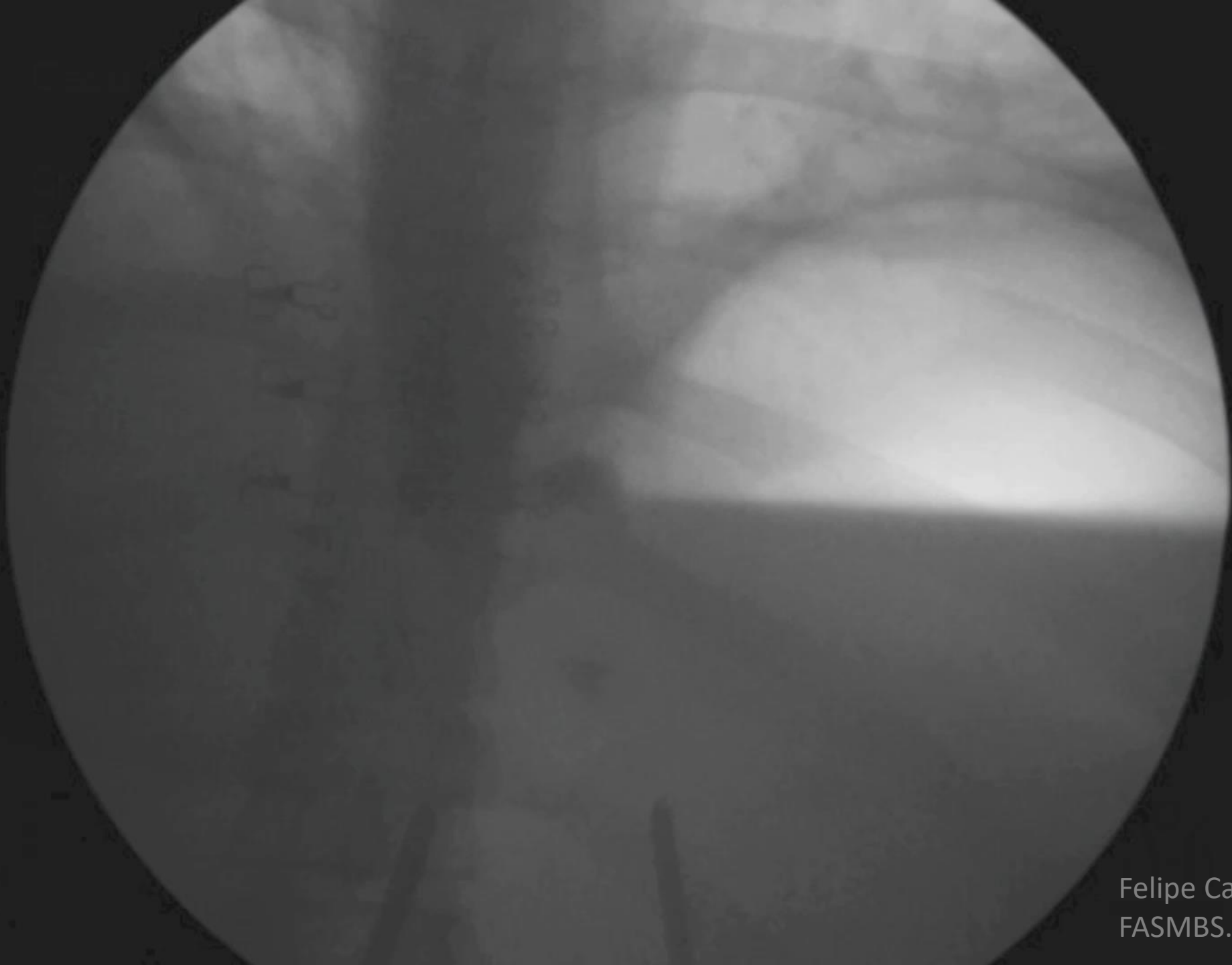
Nothing to disclose



Case 1

- 36 y/o f
- BMI 40
- Underwent uneventful Lap Gastric Plication
- POD 2 admitted to the ER:
 - Severe abdominal pain
 - Tachypnea
 - Tachycardia
 - Nausea / Vomiting
 - WBC 24.10 K/ul

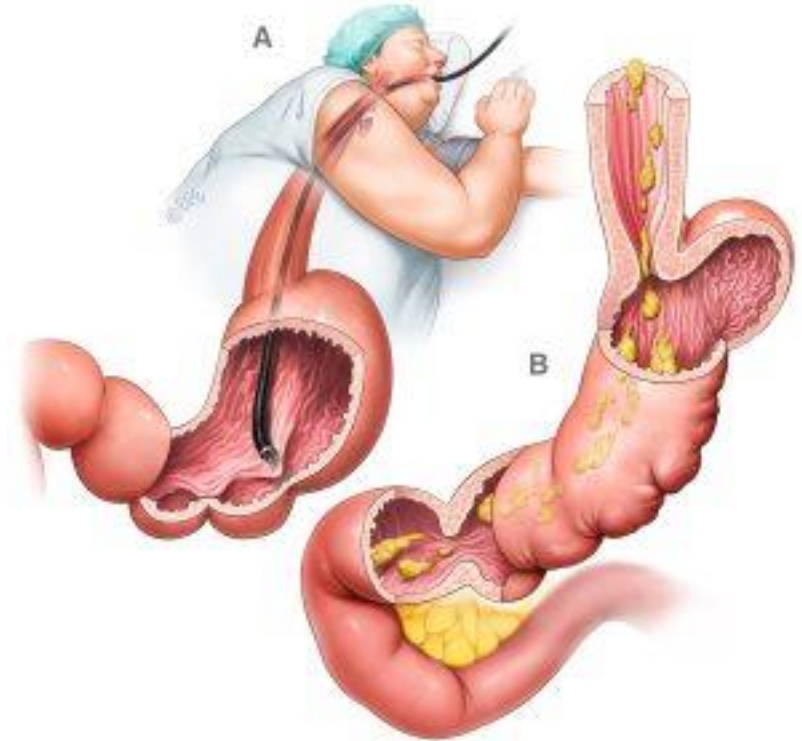




Felipe Cantu MD, FACS.
FASMBS.

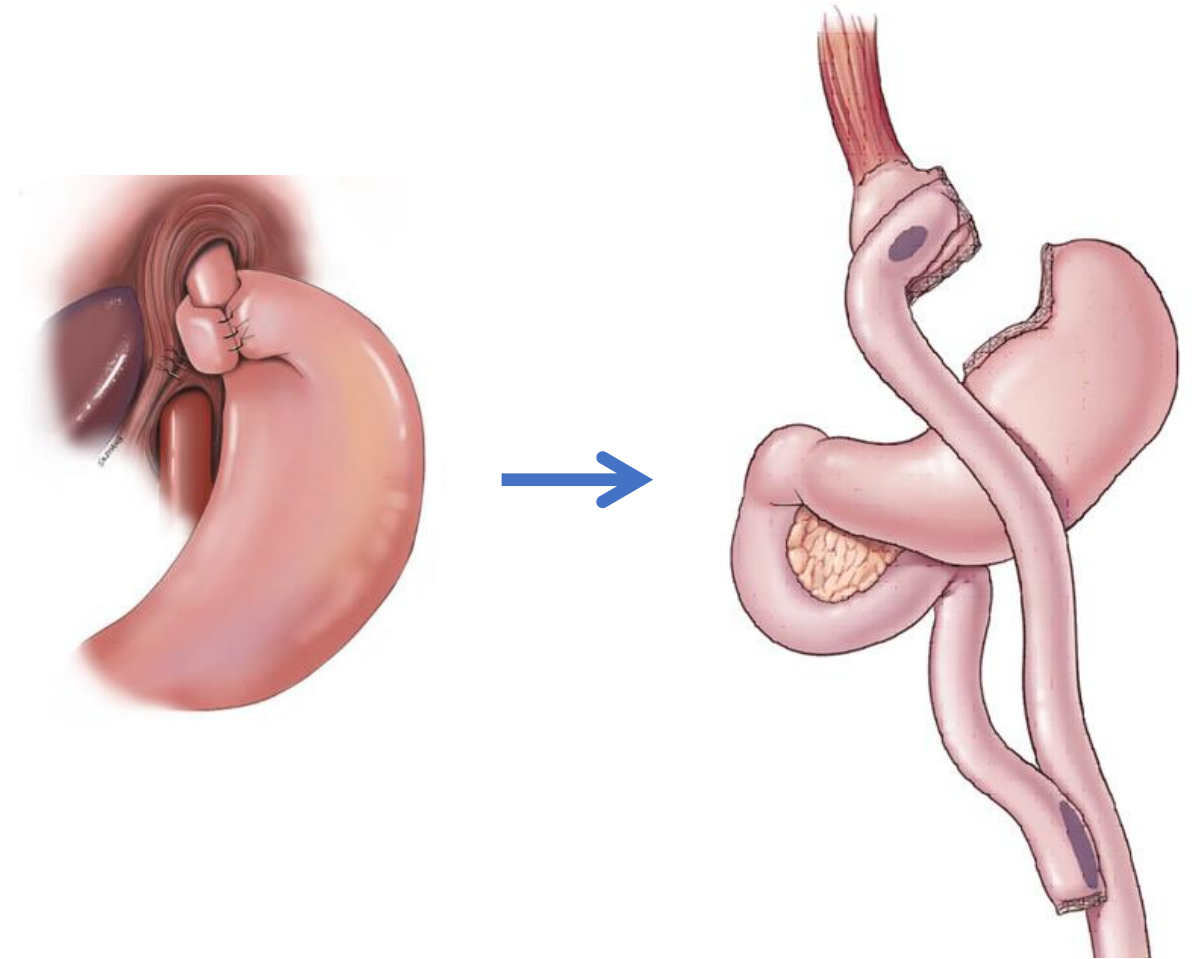
Case 2

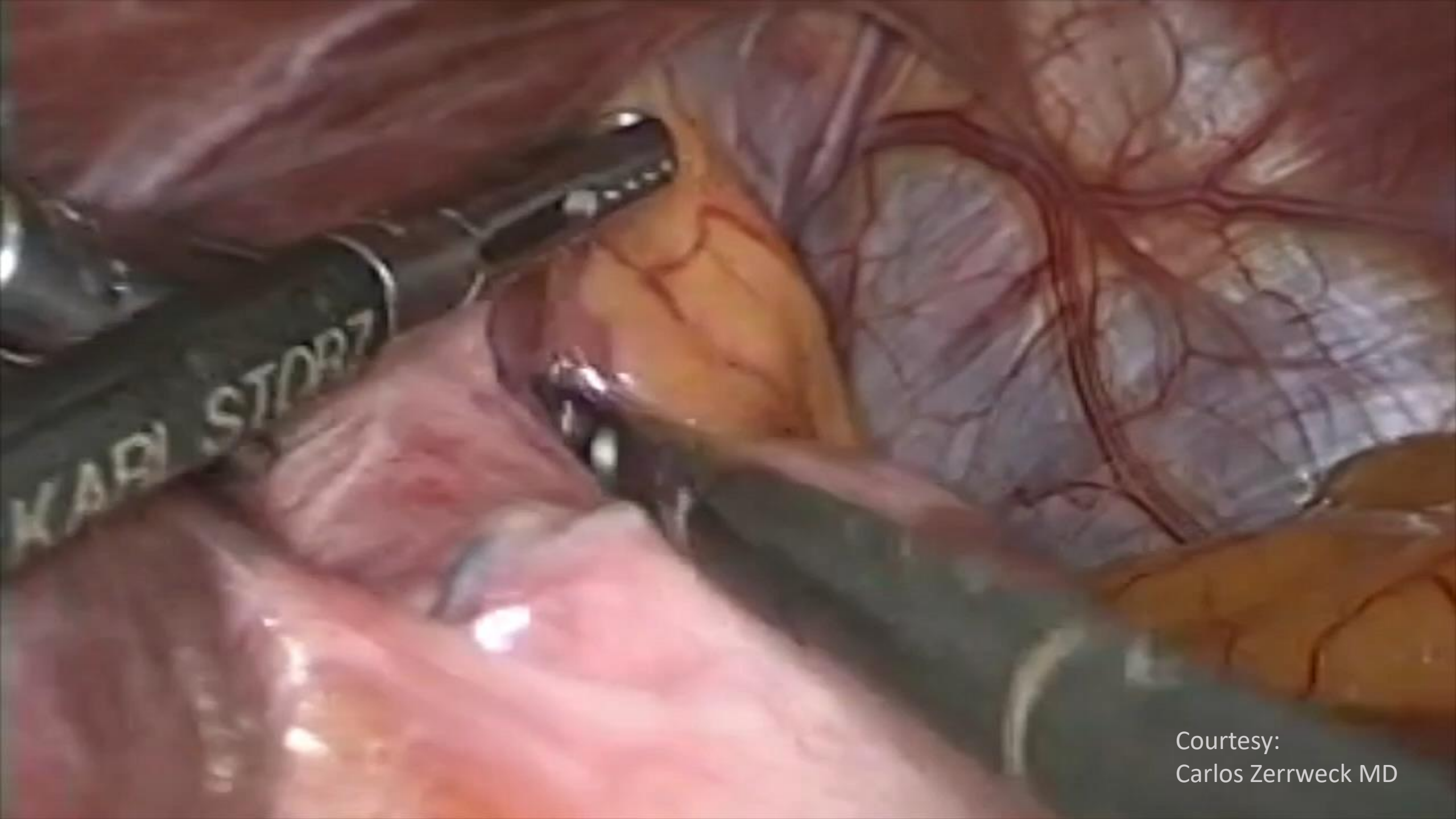
- 43 y/o f
- BMI 31.8
- Underwent uneventful Endoscopic Sleeve Gastroplasty
- POD 1:
 - Severe abdominal pain
 - Tachypnea
 - Tachycardia
 - Nausea / Vomiting



Case 3

- 46 y/o f
- BMI 42
- PSHx: Lap Nissen
- Plan:
 - Lap Roux-en-Y Gastric Bypass

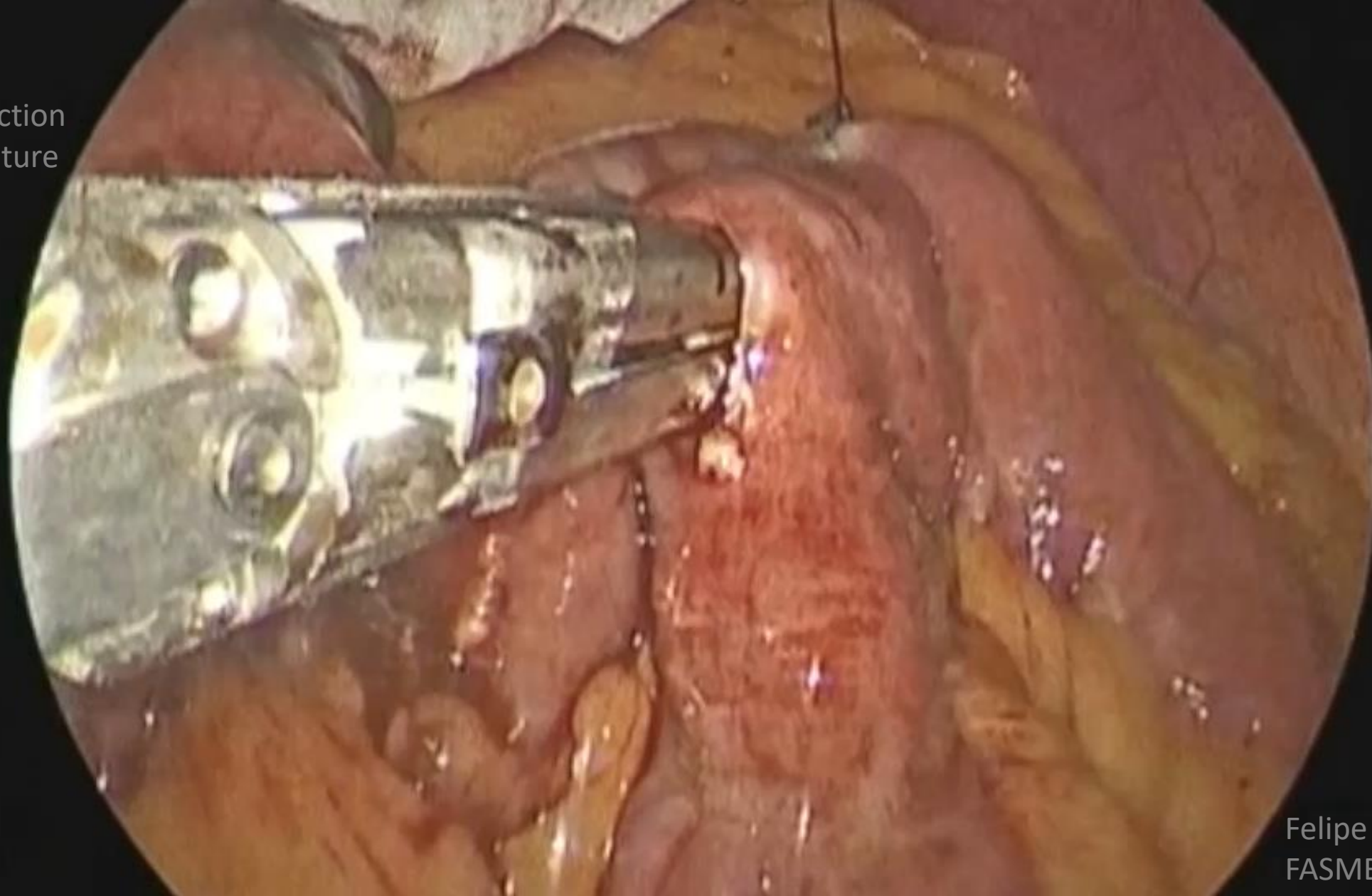




Courtesy:
Carlos Zerrweck MD

Case 4

- Lap RNY
- J-J Obstruction
- Barbed suture



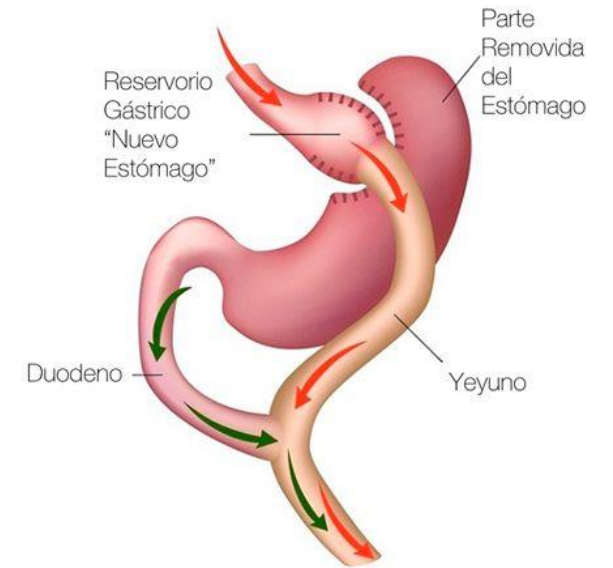
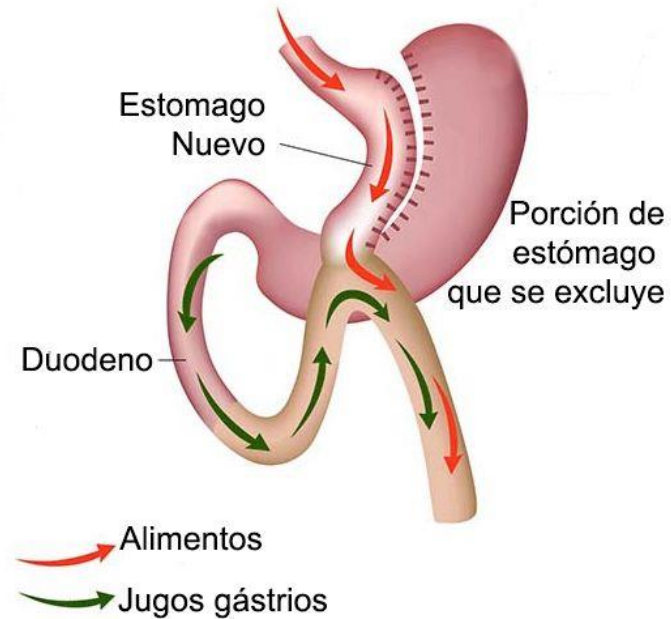Felipe Cantu MD, FACS.
FASMBS.

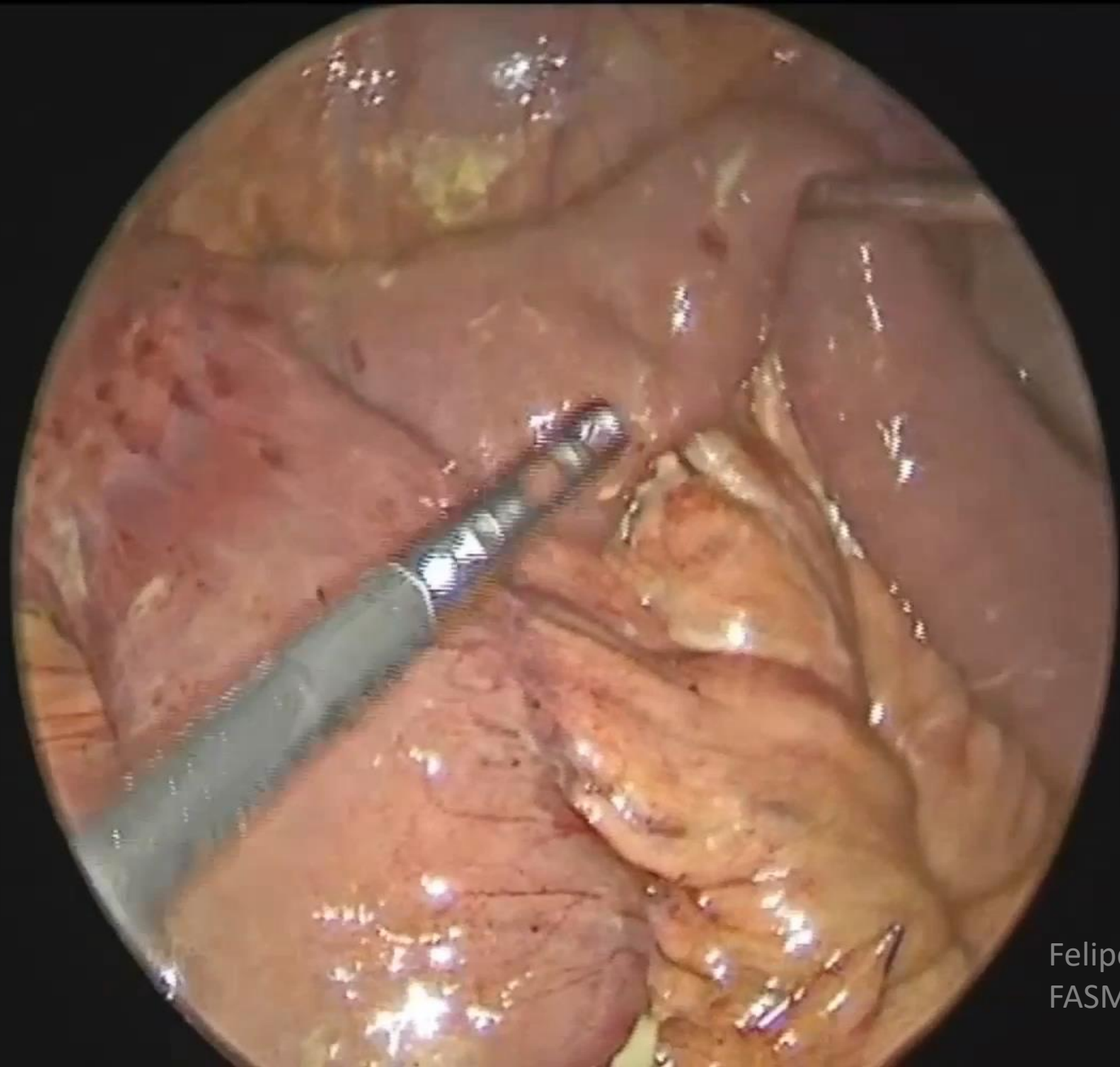
Case 5

- 42 y/o male
- 6 mo. PSHx OAGB
- Initial BMI 40
- Current BMI 28
- HPI: Fever, abdominal pain, SOB, tachycardia, WBC 20.7 K/ul.
- CT: Pneumoperitoneum and free fluid peritoneal cavity.

Felipe Cantu MD, FACS.
FASMBS.

- Perforated marginal ulcer after OAGB
- Different treatments:
 - Peritoneal lavage + omental patch.
 - Peritoneal lavage + omental patch + Braun omega J-J.
 - Peritoneal lavage + conversion to RYGBP. (resection of previous G-J)
 - Conservative treatment. AB + TPN + Drains.
 - OAGB reversal to normal anatomy.



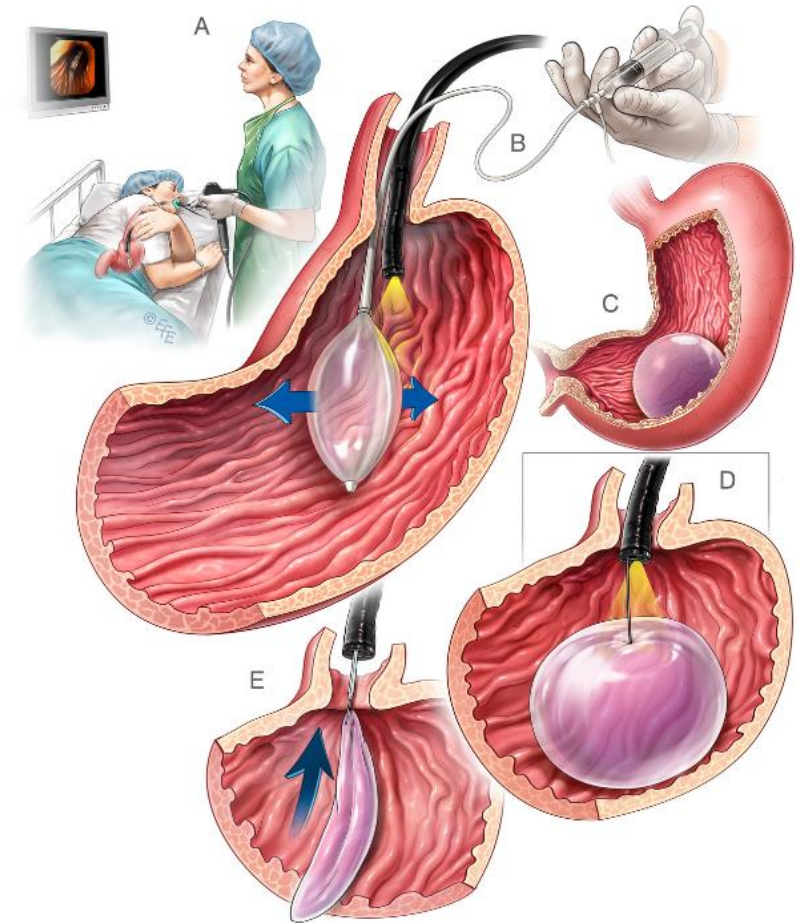



Felipe Cantu MD, FACS.
FASMBS.



Case 6

- 38 y/o female
- BMI 29.6
- Underwent uneventful Adjustable Intra-gastric Balloon placement 11 months ago.
- Plan:
 - Endoscopic removal of Intra-gastric Balloon under I.V. sedation.





Felipe Cantu MD, FACS.
FASMBS.

Disaster on Video!

Felipe J. Cantu Jr. MD, FACS, FASMBS.



A whole variety of disasters:
Get your Popcorn!



Thank You!

Felipe J. Cantú Jr. MD FACS FASMBS
Bariatric & Metabolic Surgery Professor
IFSO LAC Fellowship Program
Universidad México Americana del Norte UMAN
Reynosa, Tamaulipas, México.



XXVII Ifso World Congress



WhatsApp: +52 811 279 4637
Visítanos: ifsolac.org, ifsolac2025.com

Síguenos: ifso-lac, iacfo, ifsolac, ifsolac, @ifsolac7921

Hospital Angeles VALLE ORIENTE HA

II CONGRESO INTERNACIONAL DE CIRUGÍA BARIÁTRICA Y METABÓLICA 2025

INTERVENCIONES METABÓLICAS: MIRANDO HACIA EL FUTURO

26, 27 Y 28 DE FEBRERO DEL 2025 | MONTERREY, NUEVO LEÓN

Graduación Programa Fellowship IFSO LAC

CONGRESIONAL ESPECIALIDAD EN EVENTOS MÉDICOS

Melbourne 2024