



“Duodenal Disecction and **DI** in **SADI-S** and **DS**: Tips and Tricks”

”

- Antonio J. Torres MD, PhD, FACS, FASMBS
- Professor of Surgery
- Hospital Clínico San Carlos. Universidad Complutense de Madrid
- **President IFSO 2011-2012**
- **Chairman IFSO’s Board of Trustees 2015-2019**

Disclosures

Lectures & Consultant for

Johnson & Johnson

Medtronic

GT Metabolic


Meril

Gore Medical

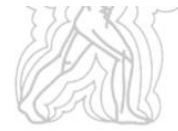

CLASSIC -DS

SADIS-OADS



“ Switch to the Switch ”



Modern Surgery: Technical Innovation

“Right-Angled” Stapled Latero-lateral Duodeno-jejunal Anastomosis in the Duodenal Switch

Andrés Sánchez-Pernaute, MD, PhD; Elia Pérez-Agudó, MD, PhD; Luis Díez-Valladares, MD, PhD; Alvaro Robin, MD; Pablo Talavera, MD; Miguel Angel Rubio, MD, PhD; Antonio Torres García, MD, PhD, FRCGS

Our Duodenal Switch (2000 - 2007)

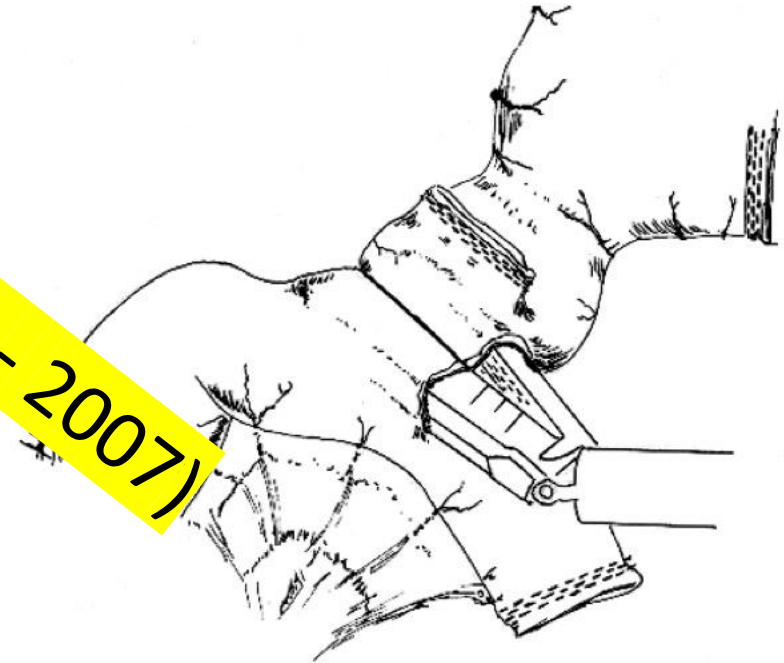
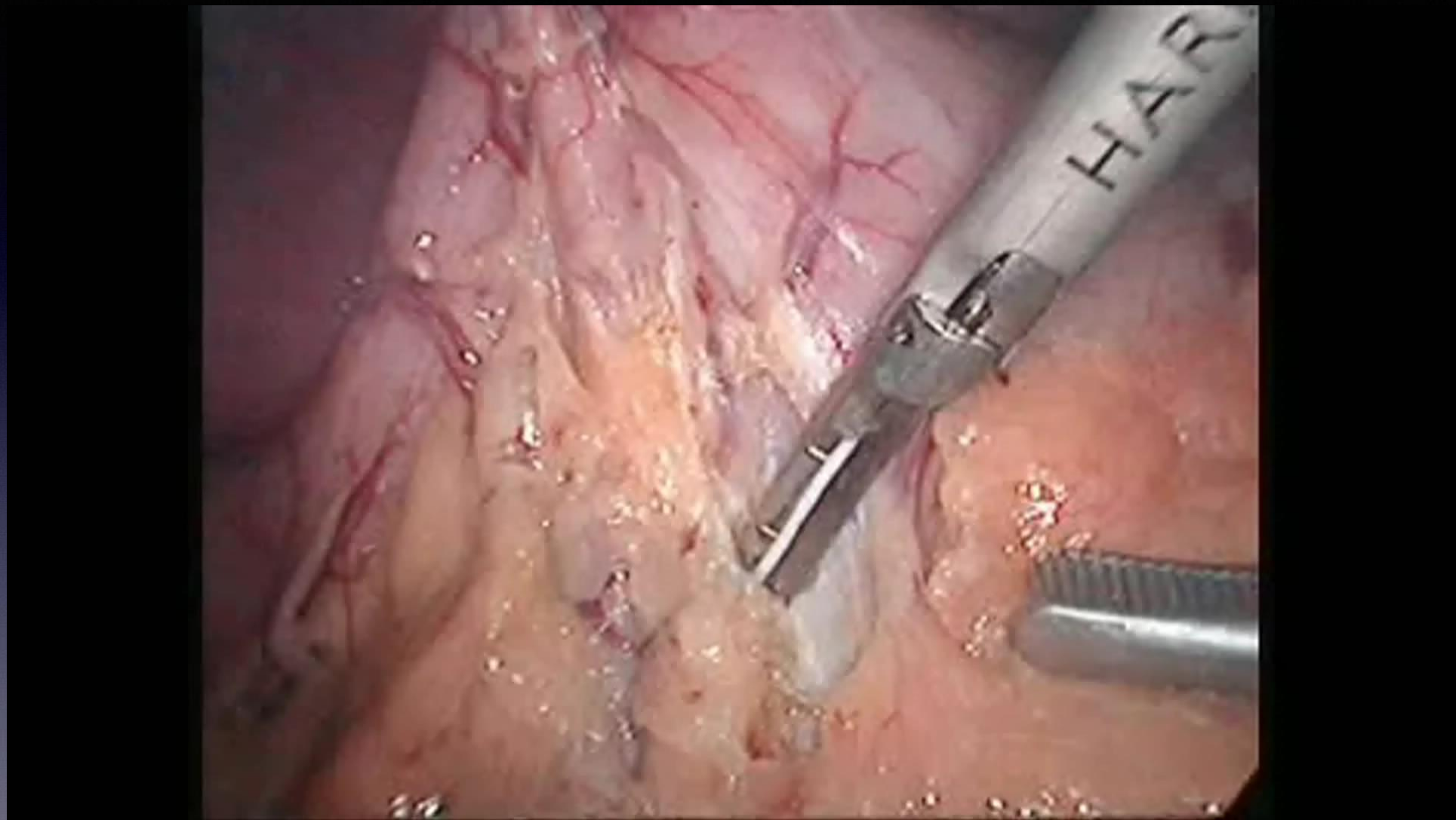
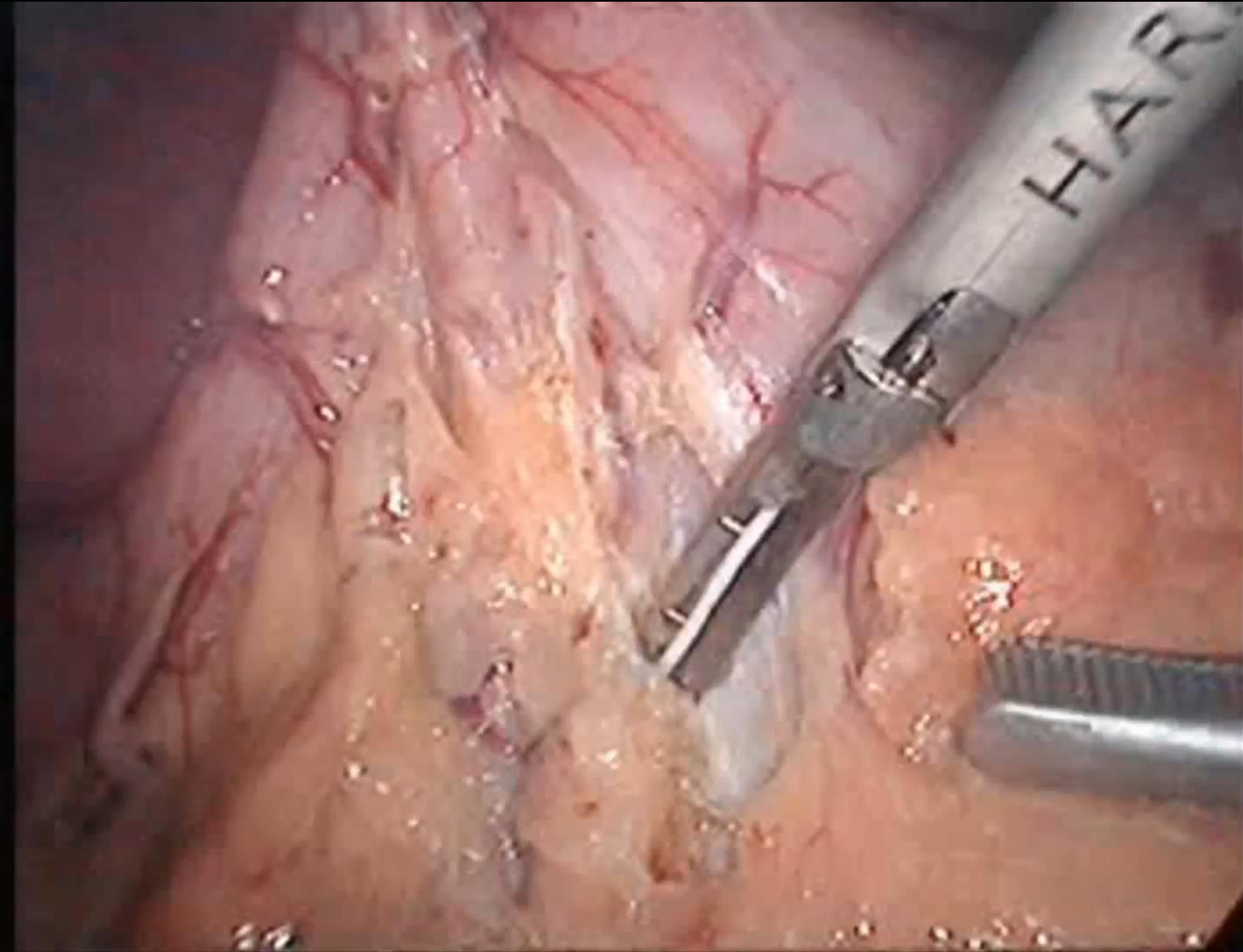


Figure 1. The ascended jejunal loop has been placed at right angles under the proximal duodenal stump. A hole has been performed in the duodenum and in the jejunum, and the linear stapler has been introduced to perform the latero-lateral anastomosis.

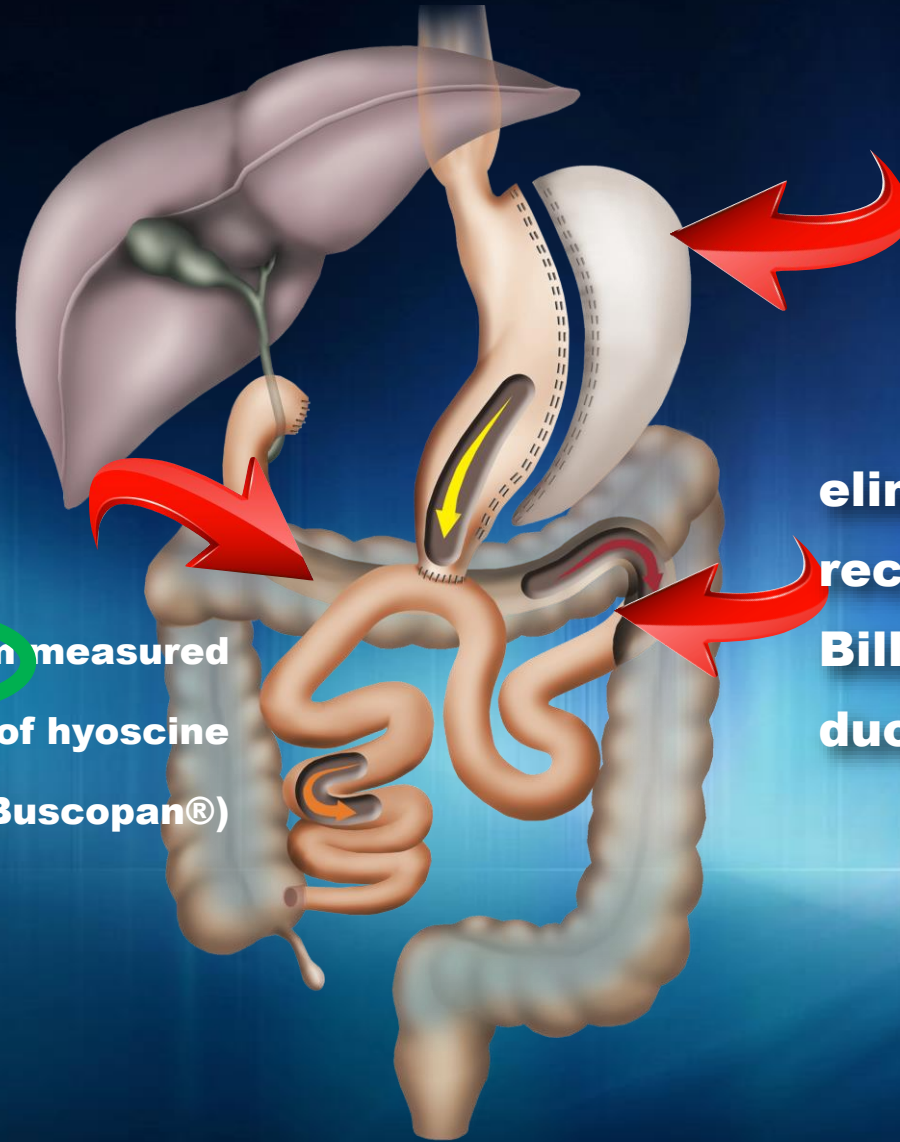
ROUX-en-Y DUODENAL SWITCH



ROUX-en-Y DUODENAL SWITCH



SADI-S



sleeve gastric resection
over a 54F bougie

eliminates the Roux- en-Y
reconstruction and includes
Billroth II-type one-loop
duodenoileostomy instead

the ileocolic junction is identified and 250 cm measured
proximally (formerly 200 cm), after infusion of hyoscine
butylbromide (Buscopan®)

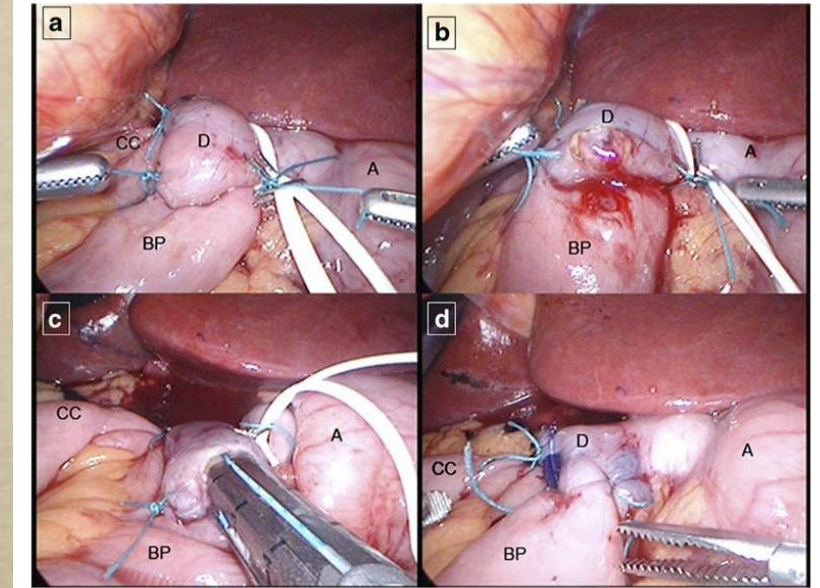


Proximal Duodenal–Ileal End-to-Side Bypass with Sleeve Gastrectomy: Proposed Technique

Andrés Sánchez-Pernaute · Miguel Angel Rubio Herrera ·
Elia Pérez-Aguirre · Juan Carlos García Pérez ·
Lucio Cabrerizo · Luis Díez Valladares · Cristina Fernández ·
Pablo Talavera · Antonio Torres



2007



OBES SURG (2007) 17:1614–1618

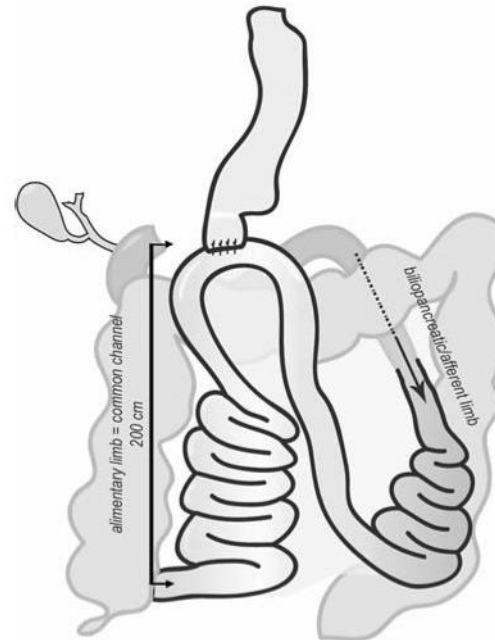
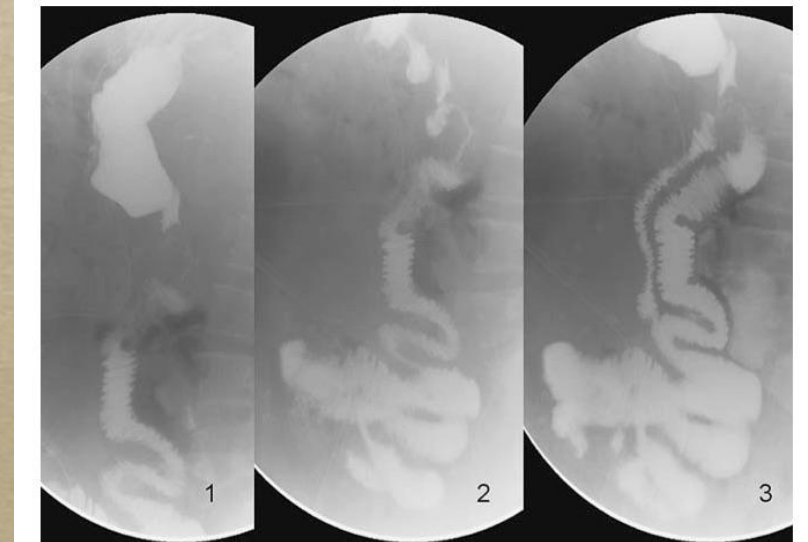
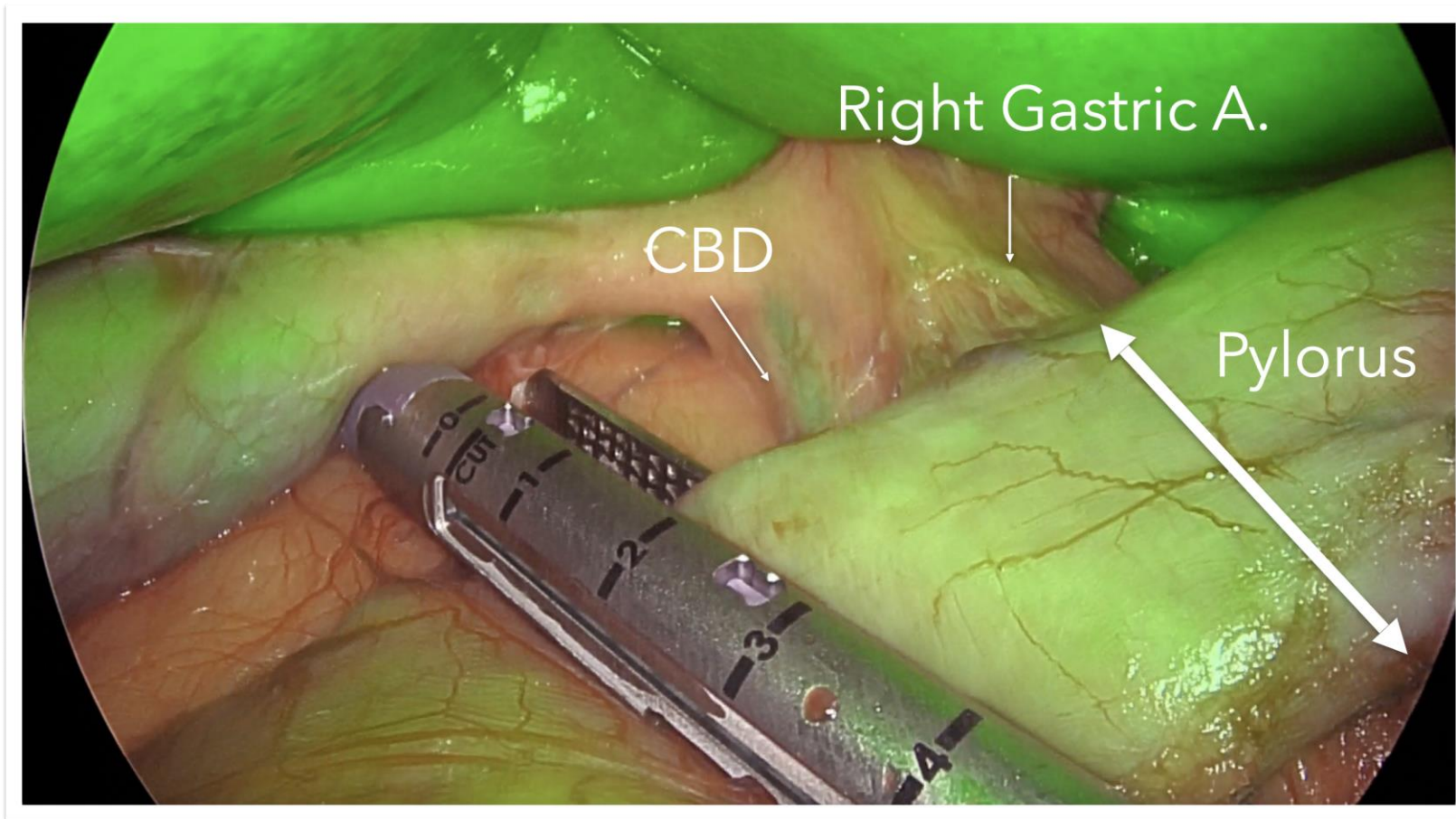


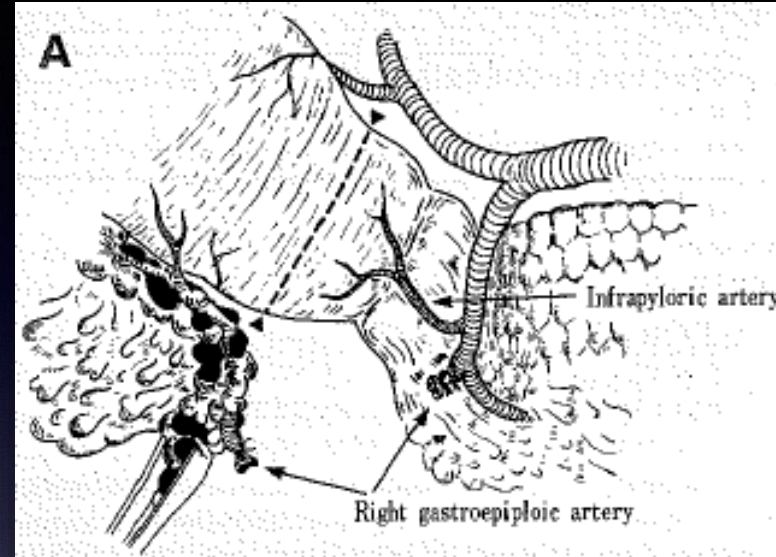
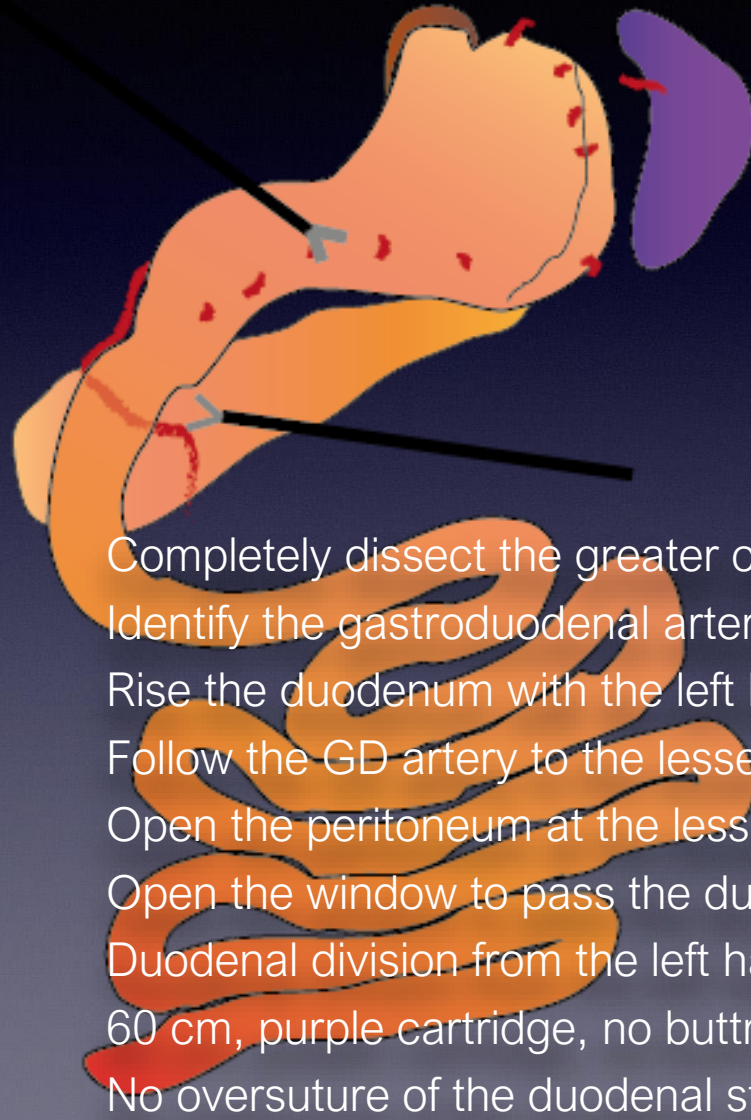
Fig. 1 The proposed technique consists on a sleeve gastrectomy followed by a loop duodeno-ileal anastomosis with a 200-cm efferent limb



With a normal pylorus, and absence of tension, one loop is enough



Duodenal Dissection & Duodenal Division



Completely dissect the greater curvature

Identify the gastroduodenal artery

Rise the duodenum with the left hand in right angles with the pancreas

Follow the GD artery to the lesser curvature

Open the peritoneum at the lesser curvature of the duodenum


Open the window to pass the duodenum from behind

Duodenal division from the left hand-side of the patient

60 cm, purple cartridge, no buttress

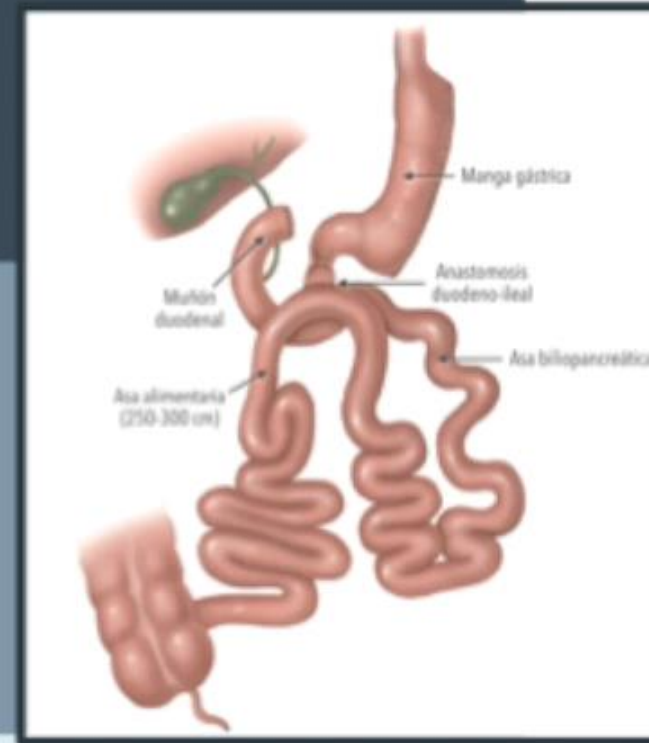
No oversuture of the duodenal stump

SADIS: Duodenal Disecction and DI Anastomosis



SADI-S 250 HANDSEWN VS MECHANICAL ANASTOMOSIS

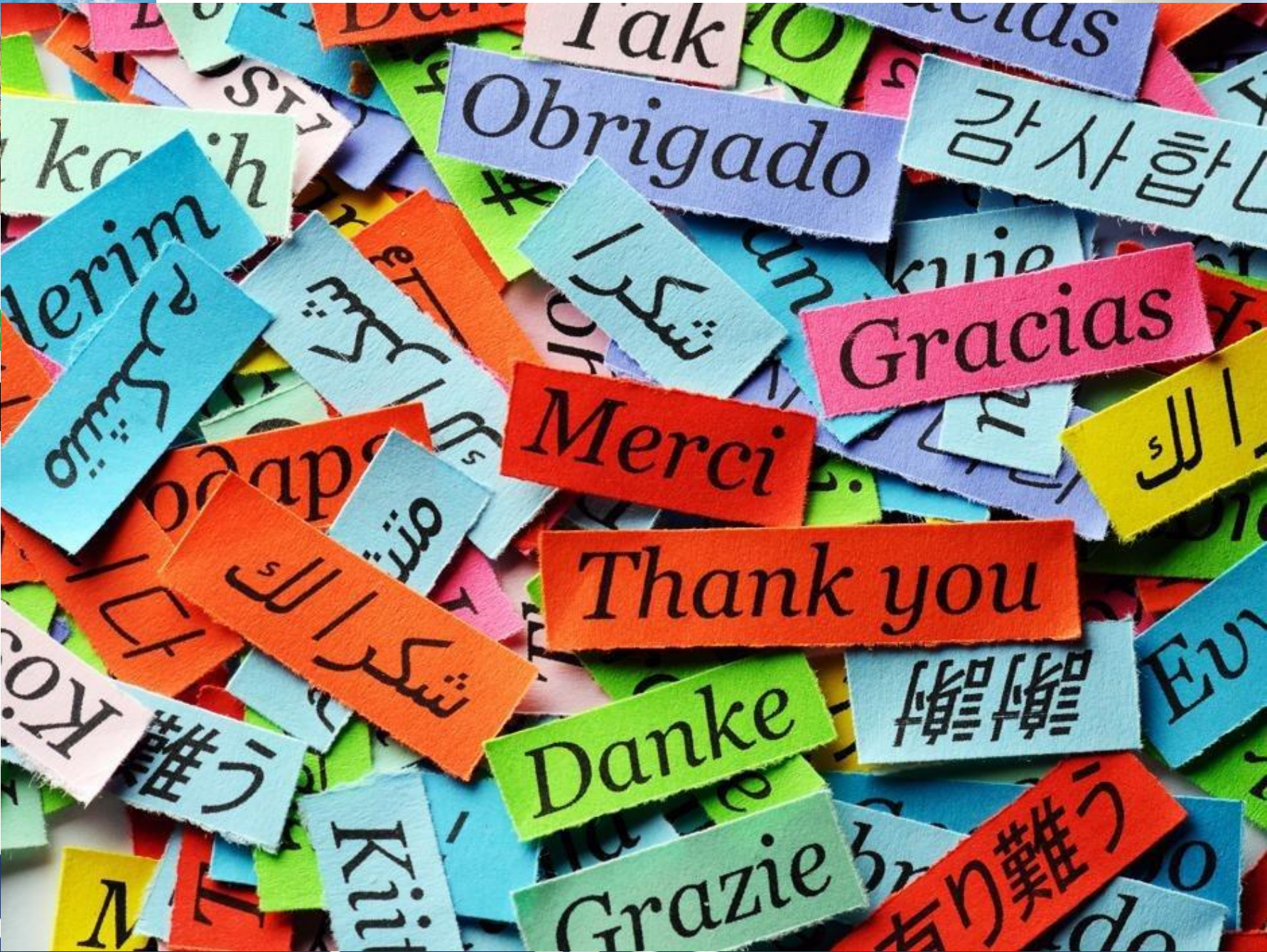Technical issues



SADI-S

UPDATED SURGICAL STRATEGIES

INTEGRATE YOUR...
IFSO
 MELBOURNE 2024
 XXVII IFSo World Congress
 3 - 6 September 2024
 Melbourne Convention and Exhibition Centre
 www.ifso2024.org
 Congress Co-Presidents
 Ahmad Ali & Harry Frydenberg



”D
 Tip
 ”

DS:



