

Butterfly Gastroplasty to RYGB due to failed weight loss

AHMED ABDELSALAM; MD, MRCS

*Associate Professor of General and Laparoscopic Surgery, Cairo
University*

Disclosure

- Nothing to disclose

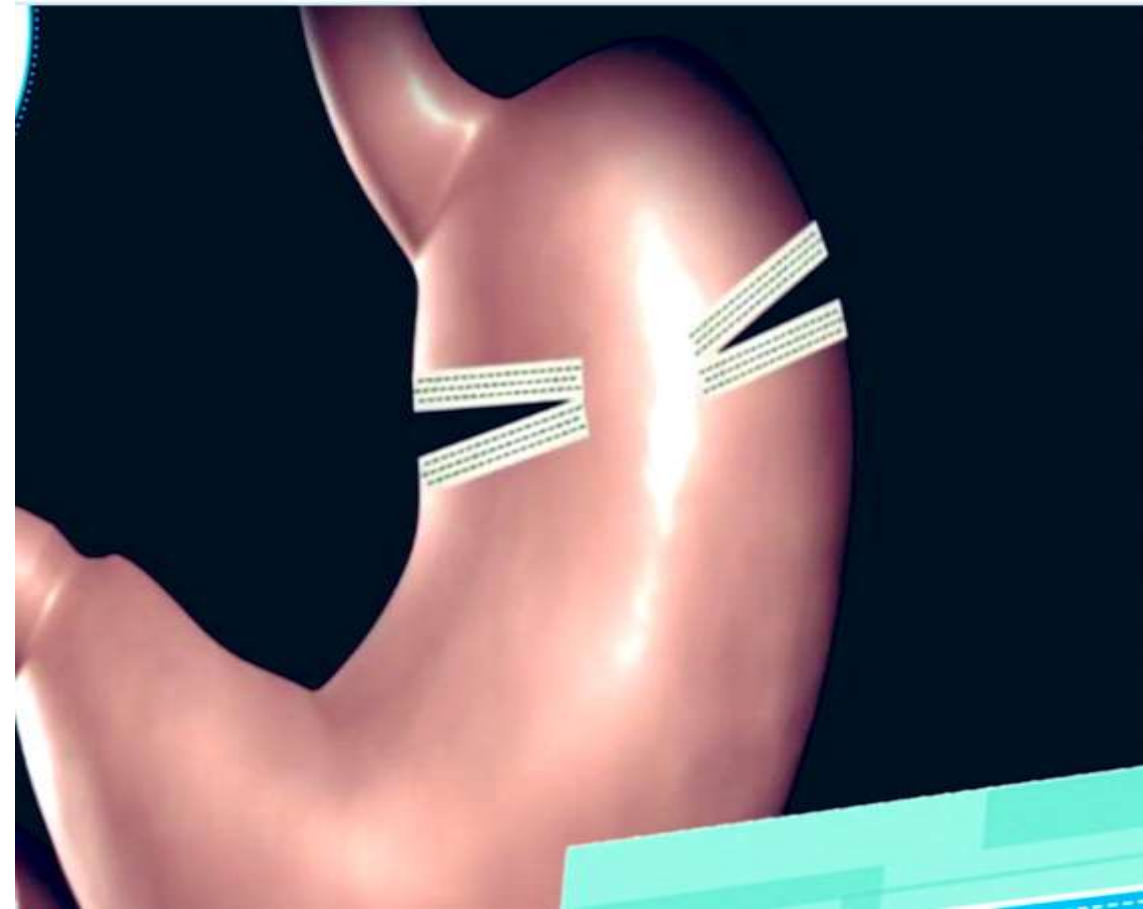



Clinical presentation



- 30 years old female
- History of Butterfly Gastroplasty done in
- BMI at presentation 32 kg/m²
- The patient presented with frequent GERD and weight regain.
- Sweet tooth.

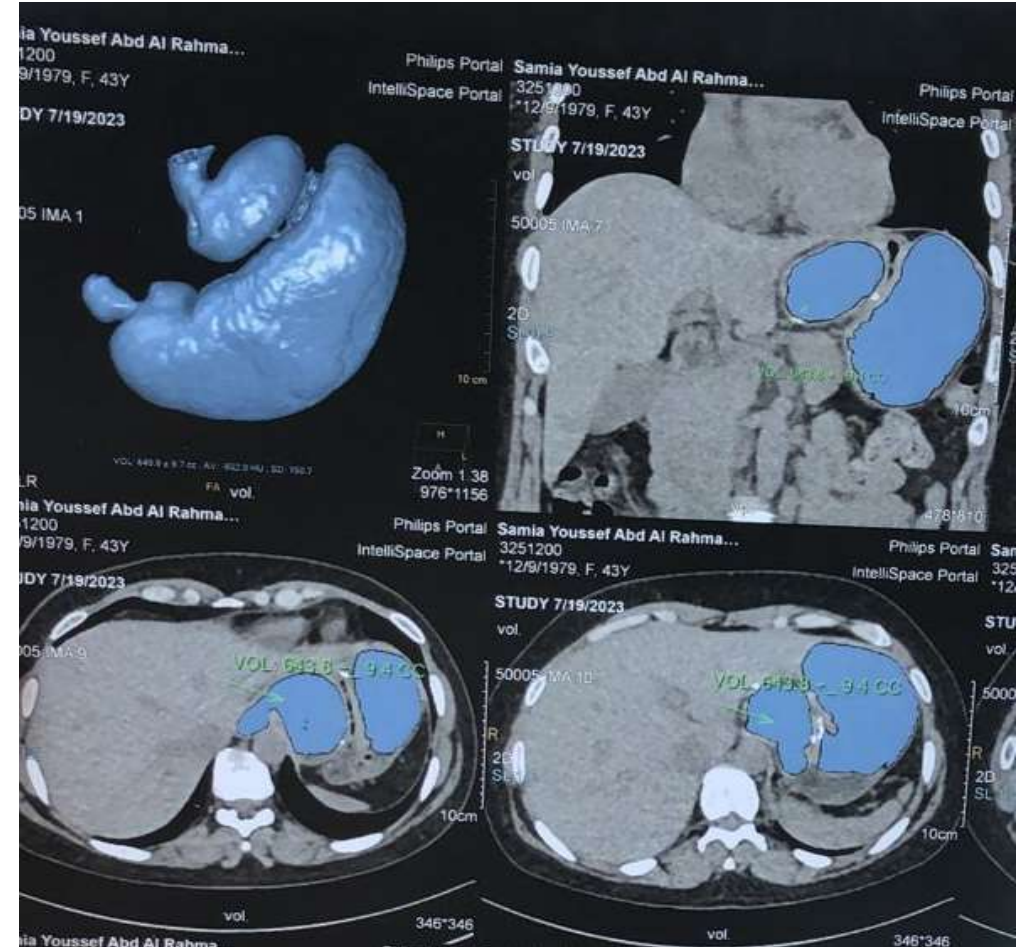
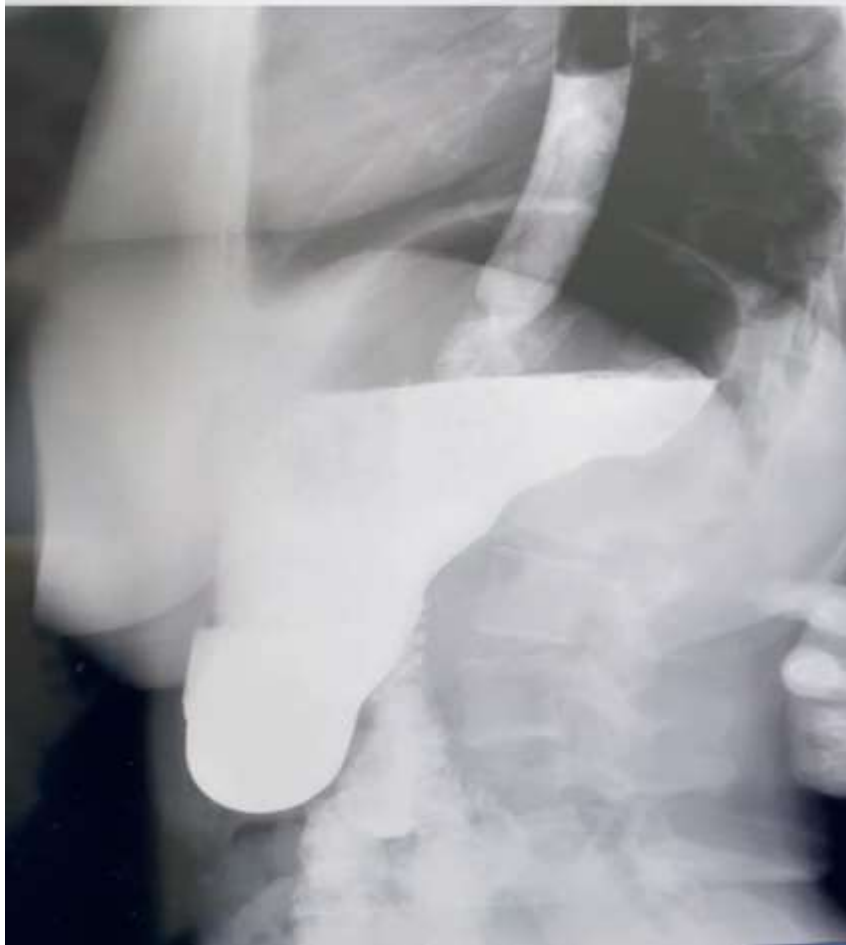Butterfly Gastroplasty




Pre-operative work-up

Labs: Hb 10 g/dl, albumin 4 g/dl

Preoperative CT gastric volumetry was done.

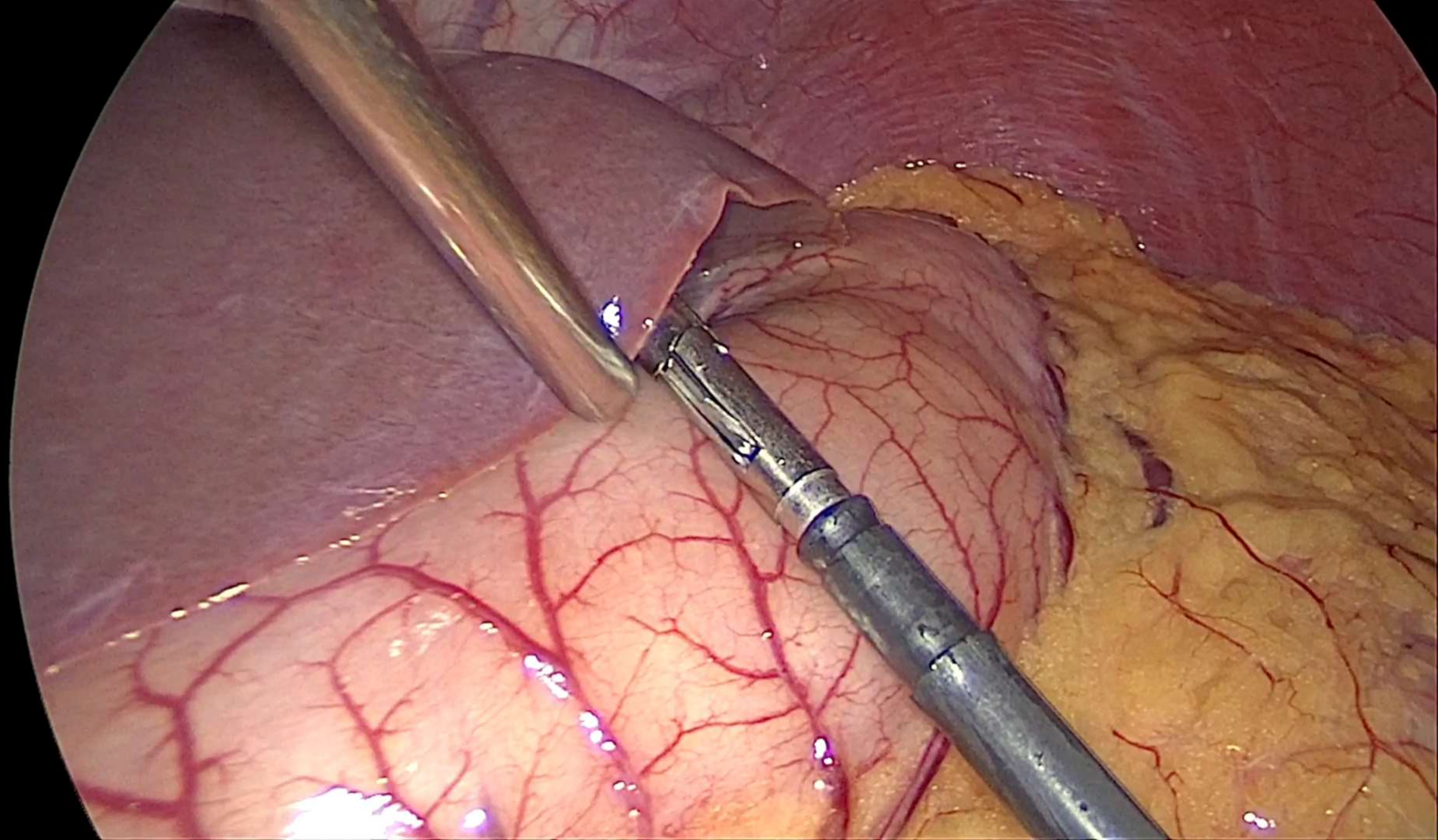




Operative Plan

To convert the butterfly gastroplasty to RYGB






Postoperative outcome

- The patient discharged POD 2 following uneventful recovery.
- Follow-up showed improved GERD symptoms and satisfactory weight loss.

Conclusion

- Laparoscopic conversion of failed butterfly gastroplasty to RYGB was feasible.
- It may be followed by higher complication rates especially leakage because of fear of ischemia due to vertical and transverse stapling of the stomach



THANK YOU

