



Brain Volumetric Changes one year after sleeve gastrectomy

Benjamin Clapp MD, FASMBS¹, Hugo Sandoval PhD¹, Laura O'Dell PhD²,
Deborah Clegg, PhD¹

1. Texas Tech School of Medicine, El Paso TX, USA
2. University of Texas at El Paso, USA

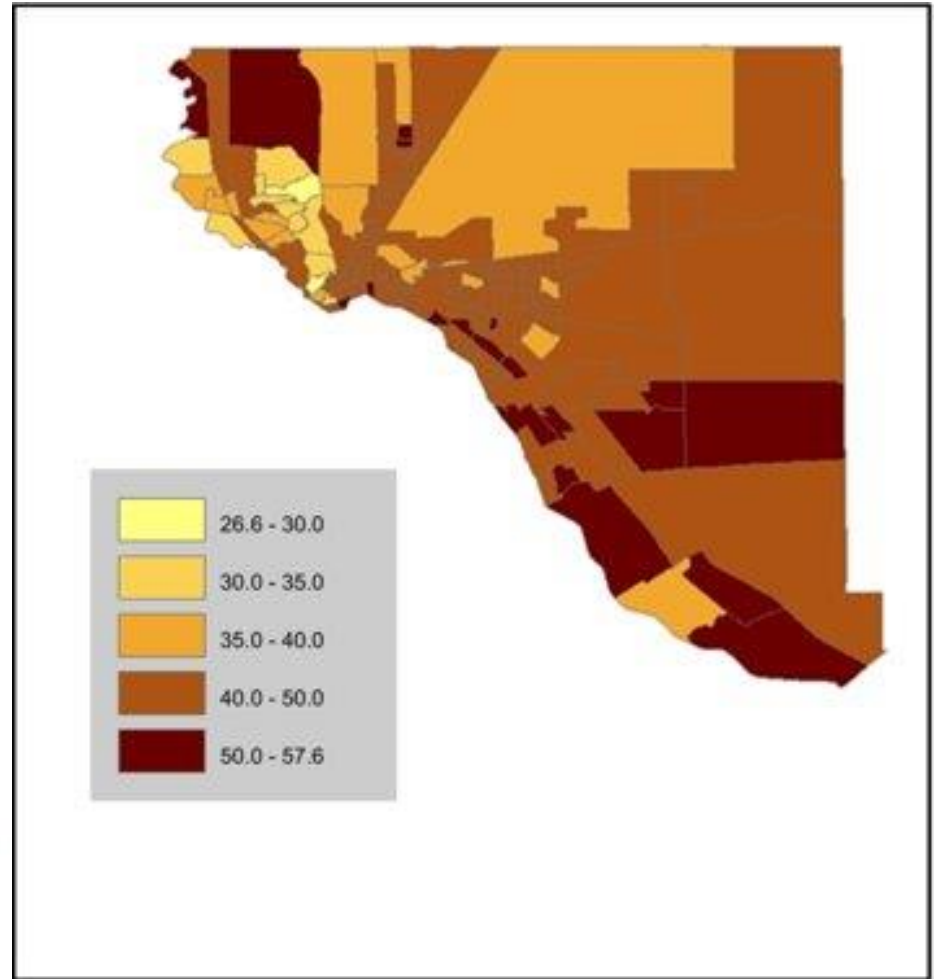
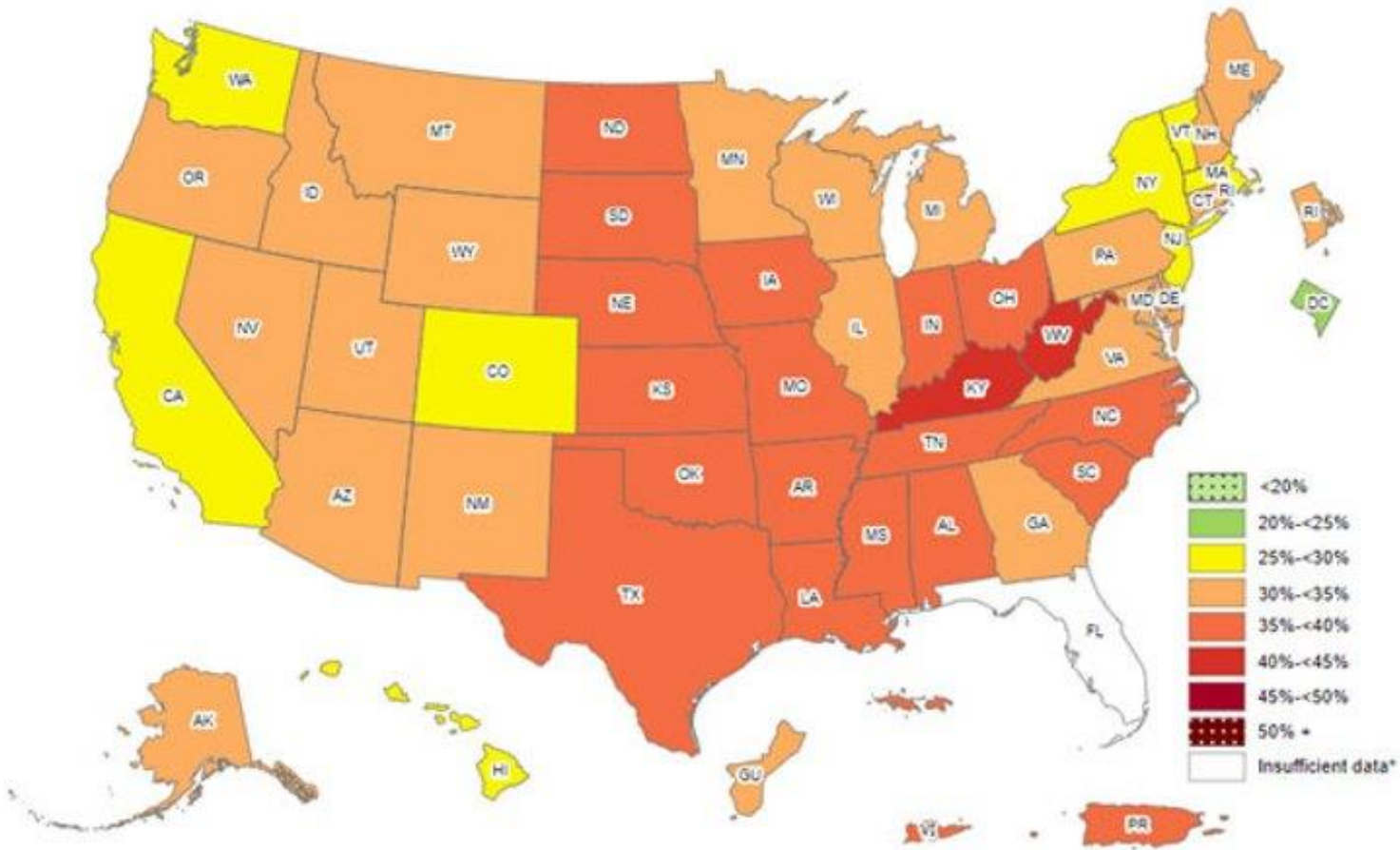
Disclosures

- Dr Clapp – consultant for Medtronic, Intuitive
- Dr Clegg – no disclosures
- Dr Sandoval – no disclosures
- Dr O'Dell – no disclosures

Introduction

- Obesity is one of the most significant health concerns of the twenty-first century.
- One of the most efficacious mechanisms to reduce body weight is the sleeve gastrectomy.

Obesity rates



Salinas, Jennifer J., et al. "An electronic medical records study of population obesity prevalence in El Paso, Texas." *BMC Medical Informatics and Decision Making* 22 (2022): 46.

Aim

- Analyze the postoperative anatomical changes one year after sleeve gastrectomy (SG) in Hispanic females (HF).

Methods

- A total of 19 SG Hispanic female patients (average age 39) participated in the study.
- MPRAGE anatomical scans were acquired using a 3 T Siemens Skyra scanner before surgery and 1 year after SG.

Inclusion Criteria

- Hispanic females who were undergoing bariatric surgery
- Age 21-50
- BMI greater than or equal than 35 kg/m²
- Right-handed and nonsmoking

Exclusion criteria

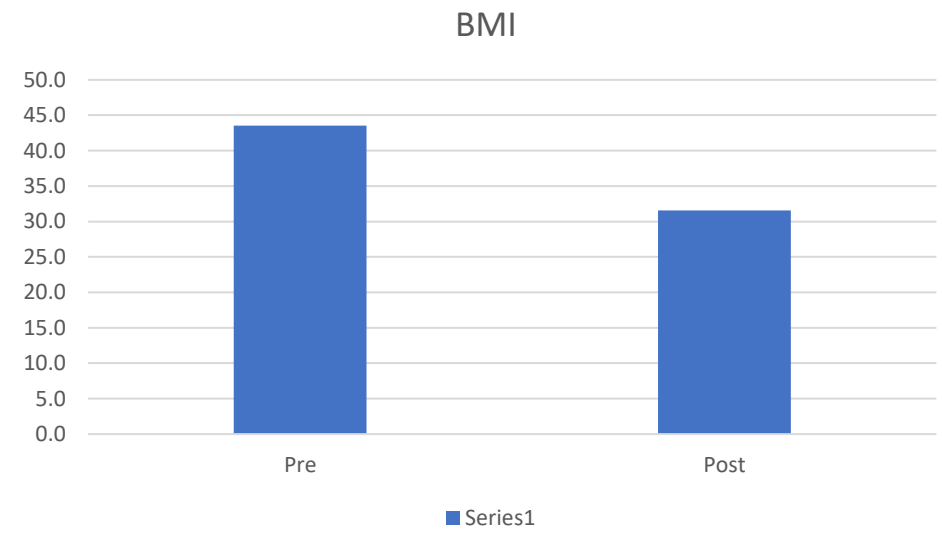
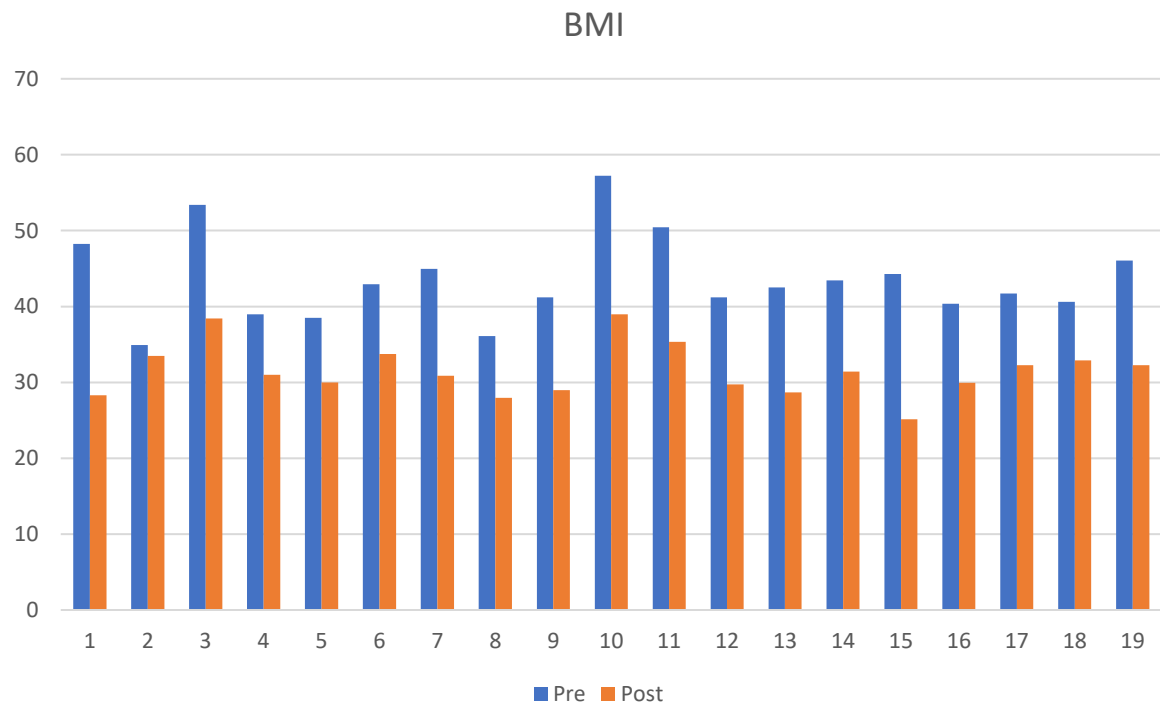
- Claustrophobia
- Metallic implants
- History of alcohol or drug use in the last 2 years
- Previous bariatric surgery
- Type 1 diabetes mellitus
- Current psychiatric diagnoses, use of psychiatric drugs, benzodiazepines, opiates, anti-obesity medications
- Patients unlikely to comply
- Pregnancy

Methods

- Cortical reconstruction and volumetric segmentation was performed with the Freesurfer image analysis suite, which is documented and freely available for download online (<http://surfer.nmr.mgh.harvard.edu>).
- This processing method includes motion correction and averaging, removal of non-brain tissue using a hybrid watershed/surface deformation procedure, segmentation of the subcortical white matter and deep gray matter volumetric structures including hippocampus, amygdala, caudate, putamen, ventricles.

Results

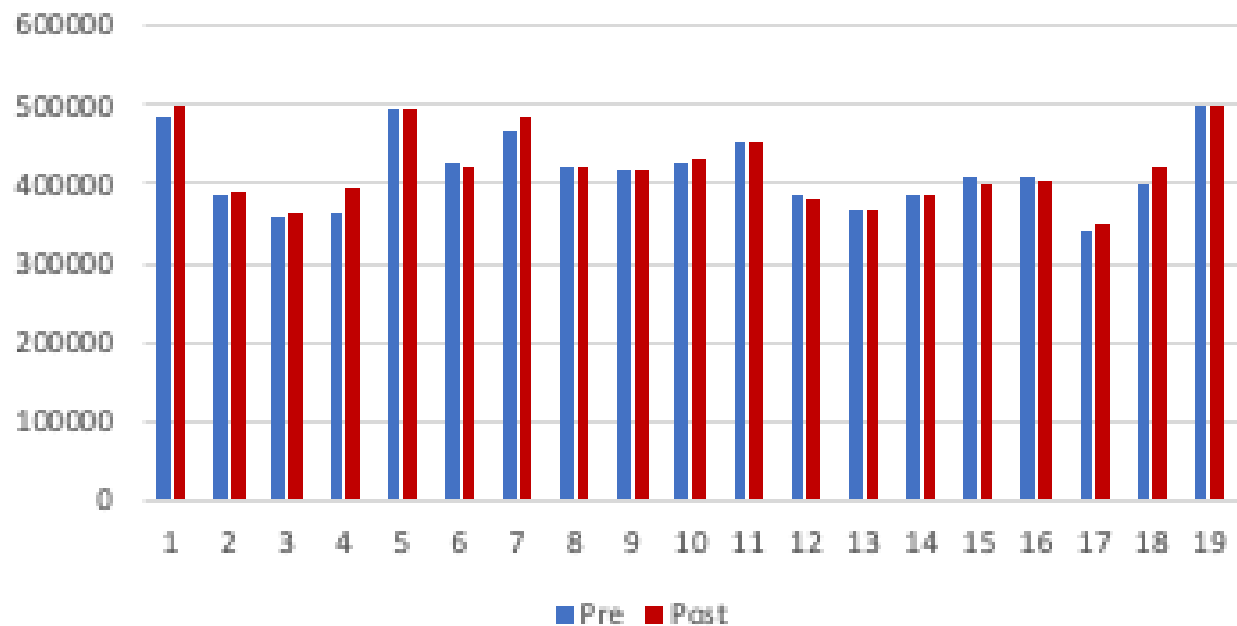
- Our results indicate SG in Hispanic females results in the following structural changes:
 - Increased white matter volumes
 - Cerebral White Matter (left and right hemispheres)
 - Posterior Corpus Callosum
 - Left Cerebellum
 - Gray matter volume changes
 - Left Hippocampus increased
 - Left Putamen and Right Caudate decreased
 - BMI decreased
 - Starting average of 44 kg/m² decreasing to 32 kg/m²



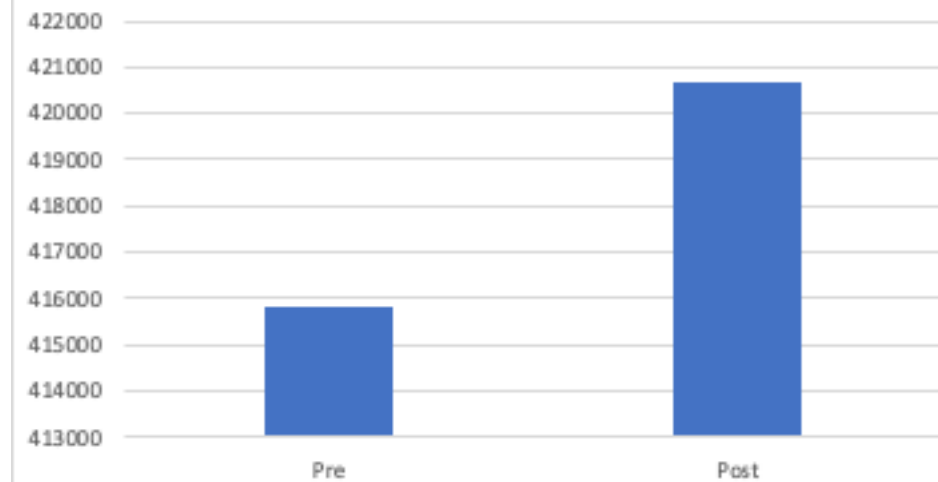
	Pre	Post
Average	44	32
STDEV	6	3
P		0.000000001

White Matter Changes

Cerebral White Matter Volume (cubic mm)

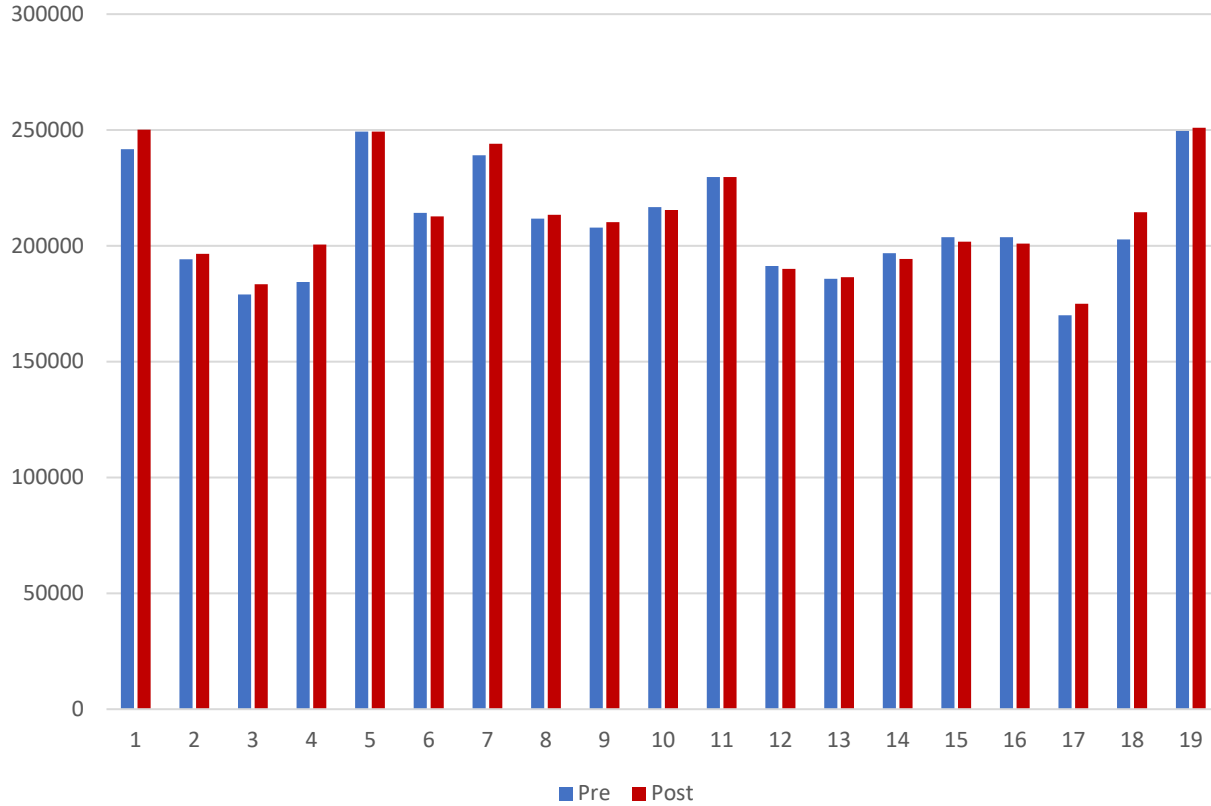


Cerebral White Matter

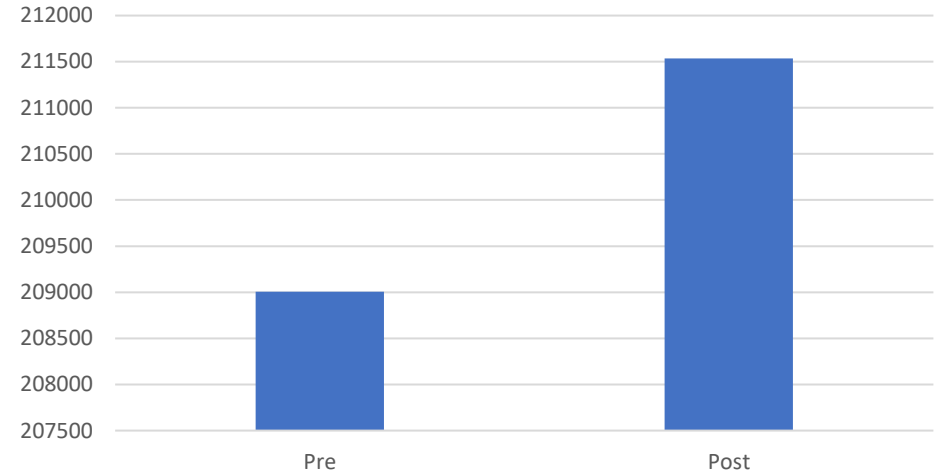


	Pre	Post
Average	415827	420649
STDEV	46788	46317
P		0.0273

Left Hemisphere Cerebral White Matter (cubic mm)

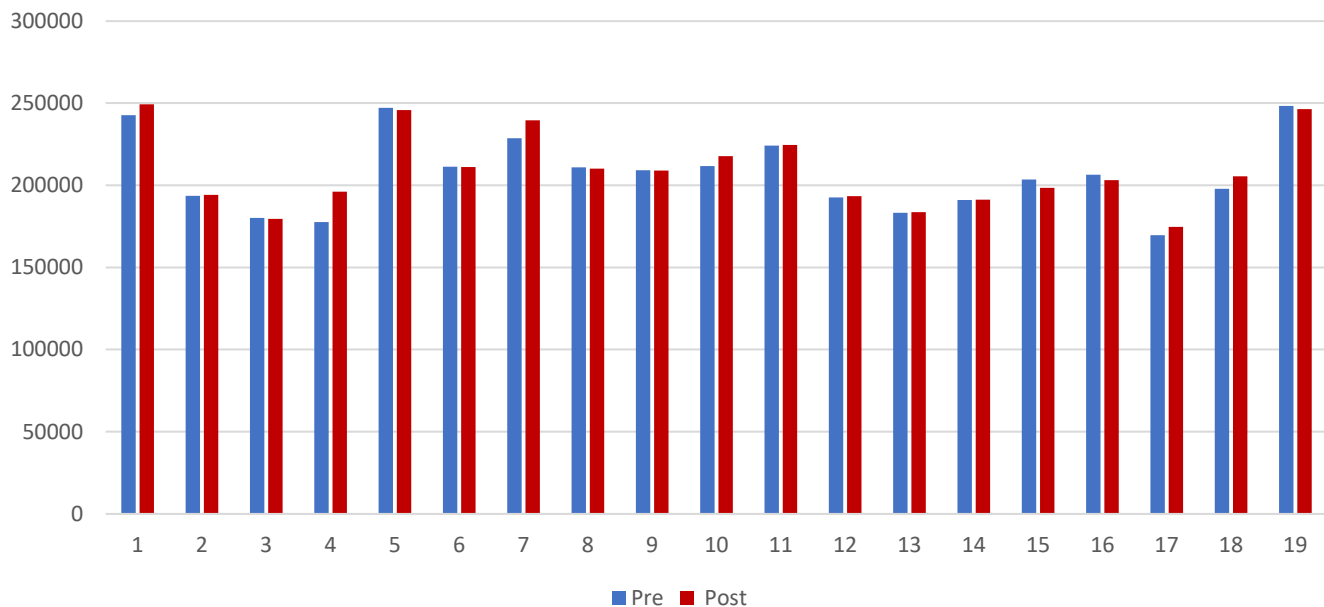


Left Hemisphere Cerebral White Matter

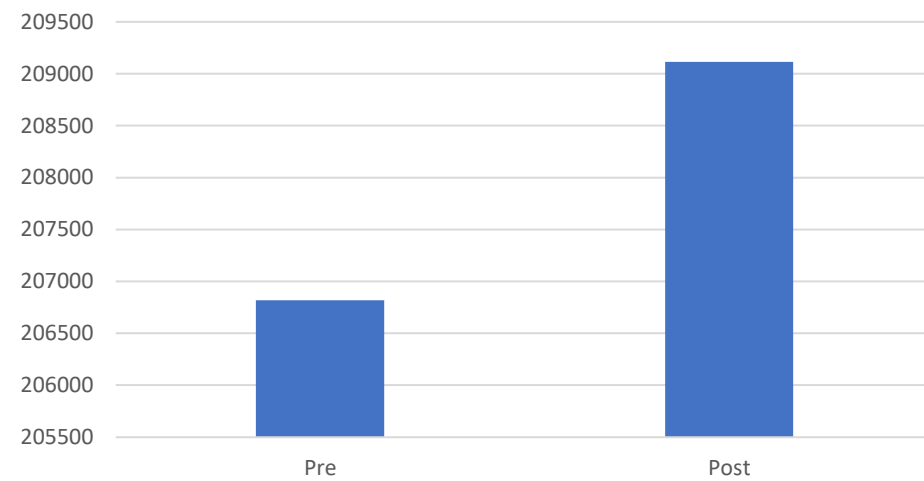


	Pre	Post
Average	209008	211535
STDEV	23685	23522
P		0.0219

Right Hemisphere Cerebral White Matter (cubic mm)

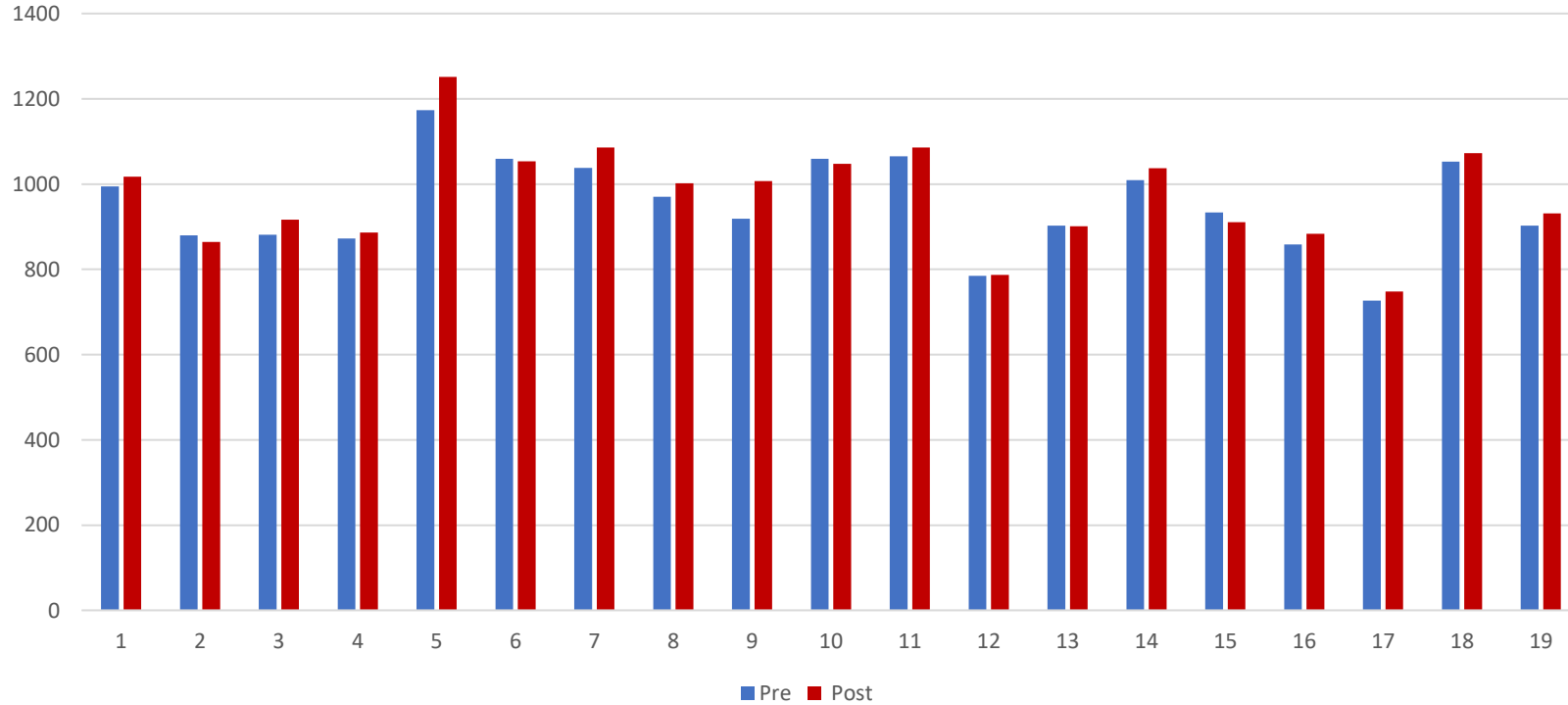


Right Hemisphere Cerebral White Matter

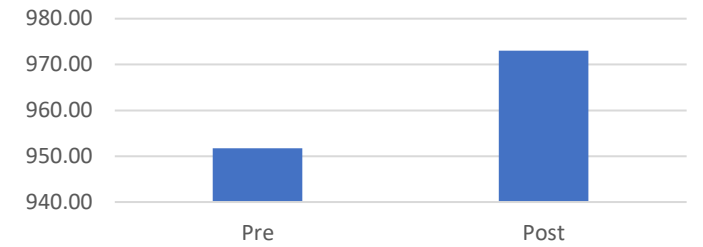


	Pre	Post
Average	206819	209114
STDEV	23227	22883
P		0.047

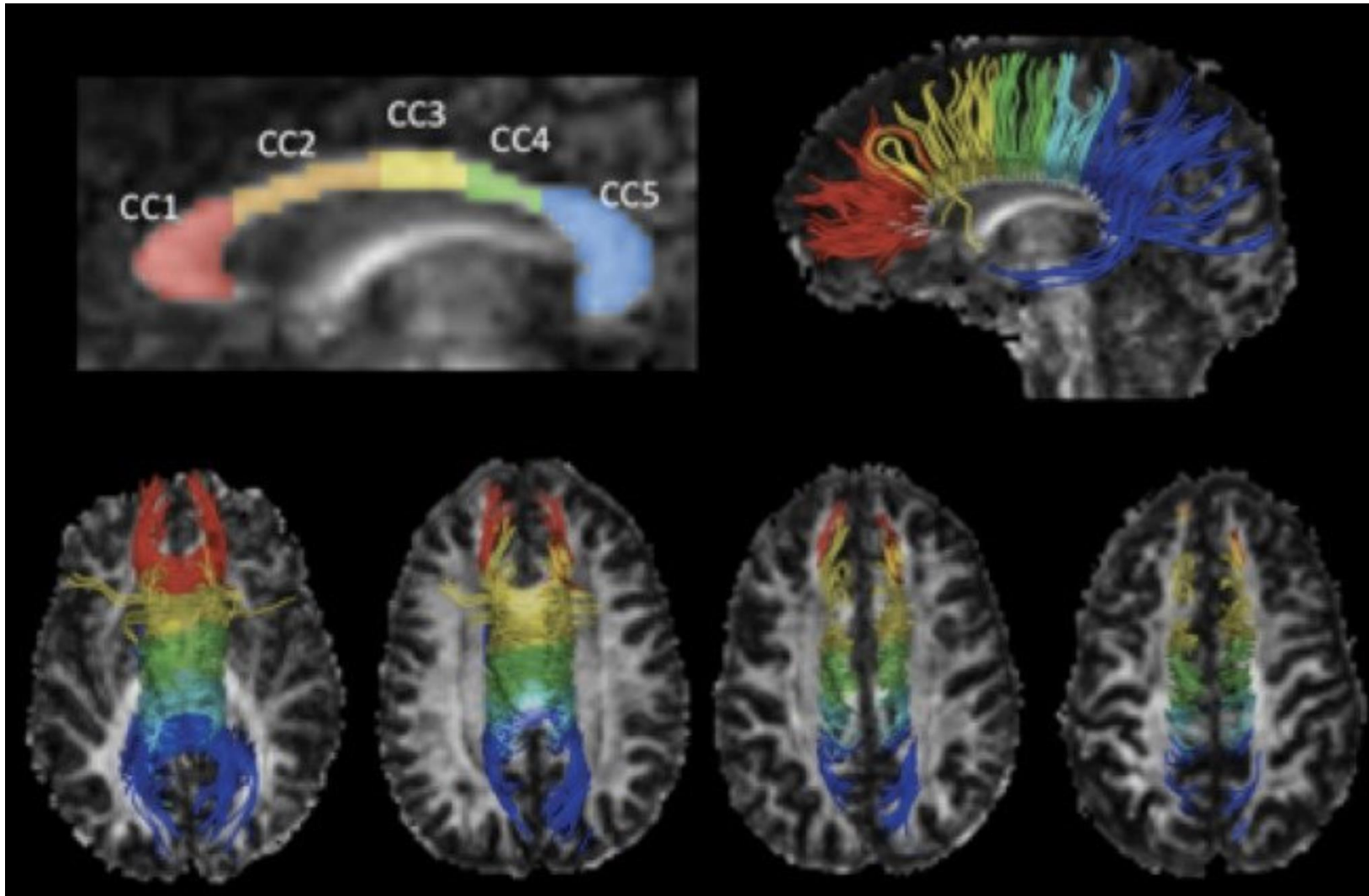
Posterior Corpus Callosum (cubic mm)



Posterior Corpus Collosum

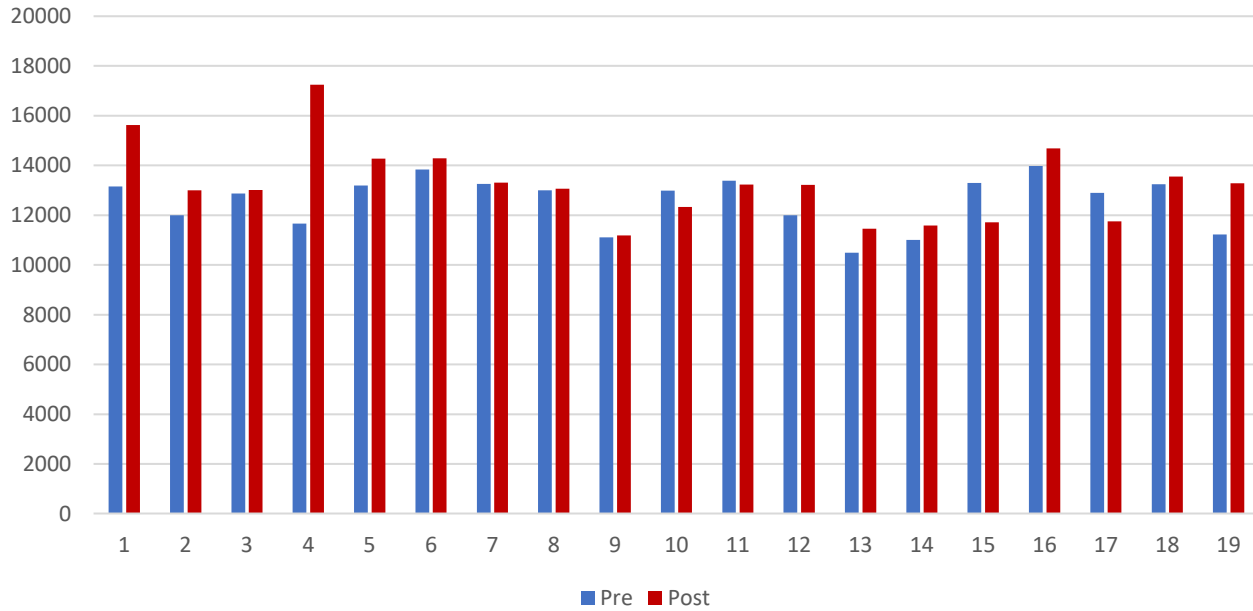


	Pre	Post
Average	952	973
STDEV	110	120
P		0.0024

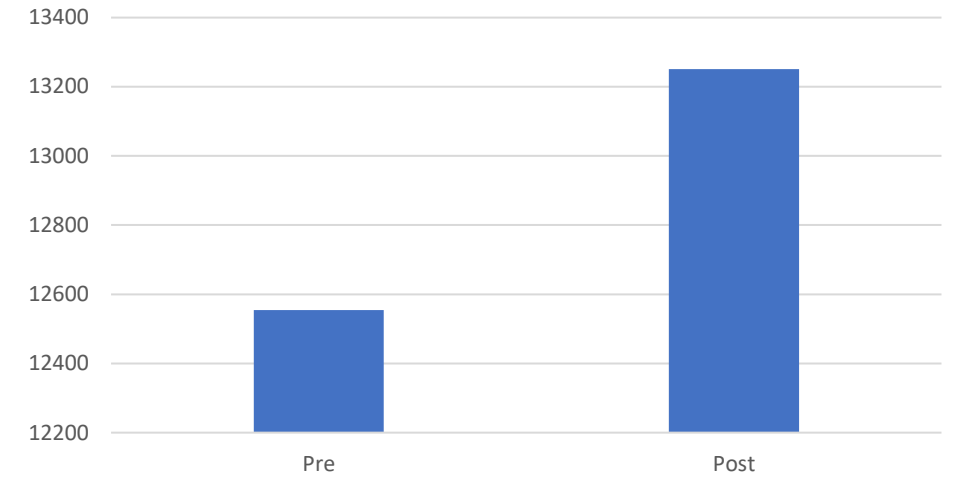


https://www.researchgate.net/figure/Corpus-callosum-segmentation-and-tractography-The-FA-map-and-the-CC-segmentation-model-fig1_256611450

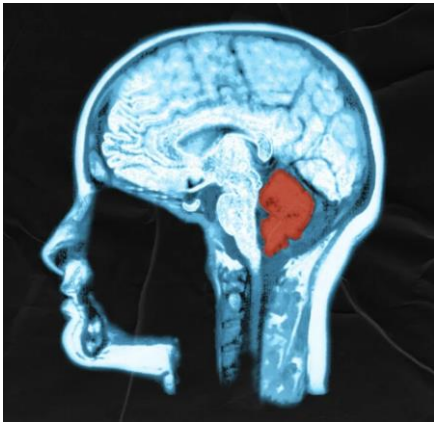
Left Cerebellum White Matter (cubic mm)



Left Cerebellum White Matter

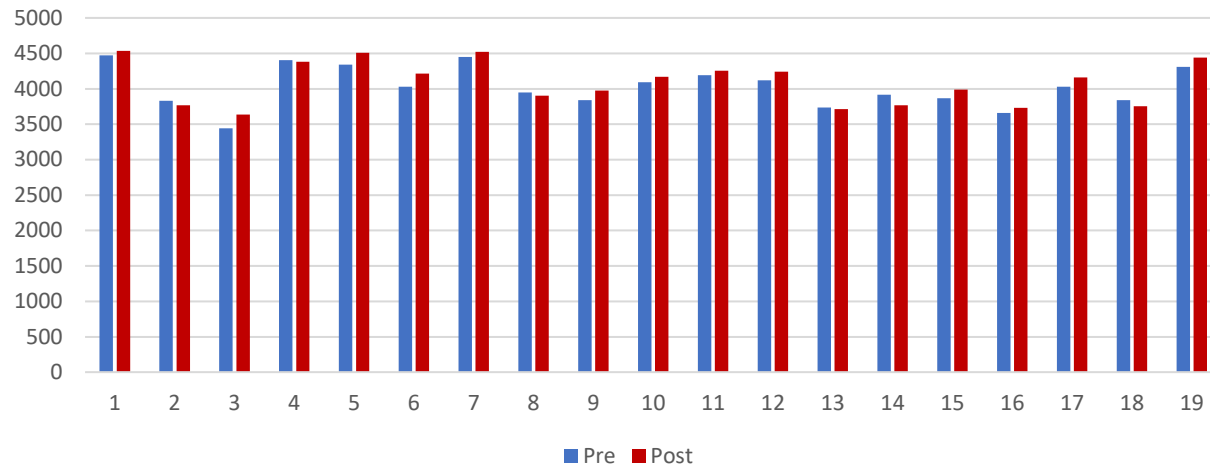


	Pre	Post
Average	12554.2105	13250.3737
STDEV	1032.82464	1523.4597
P		0.0318

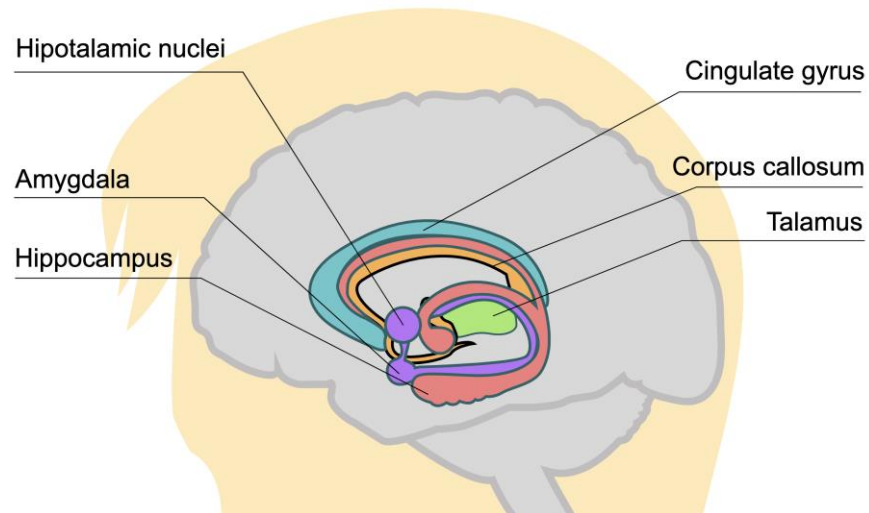
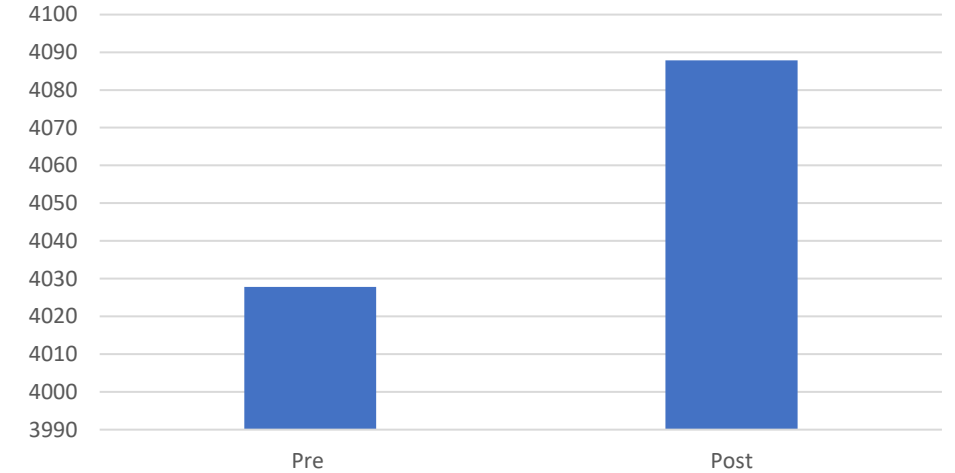


Gray Matter Changes

Left Hippocampus (cubic mm)

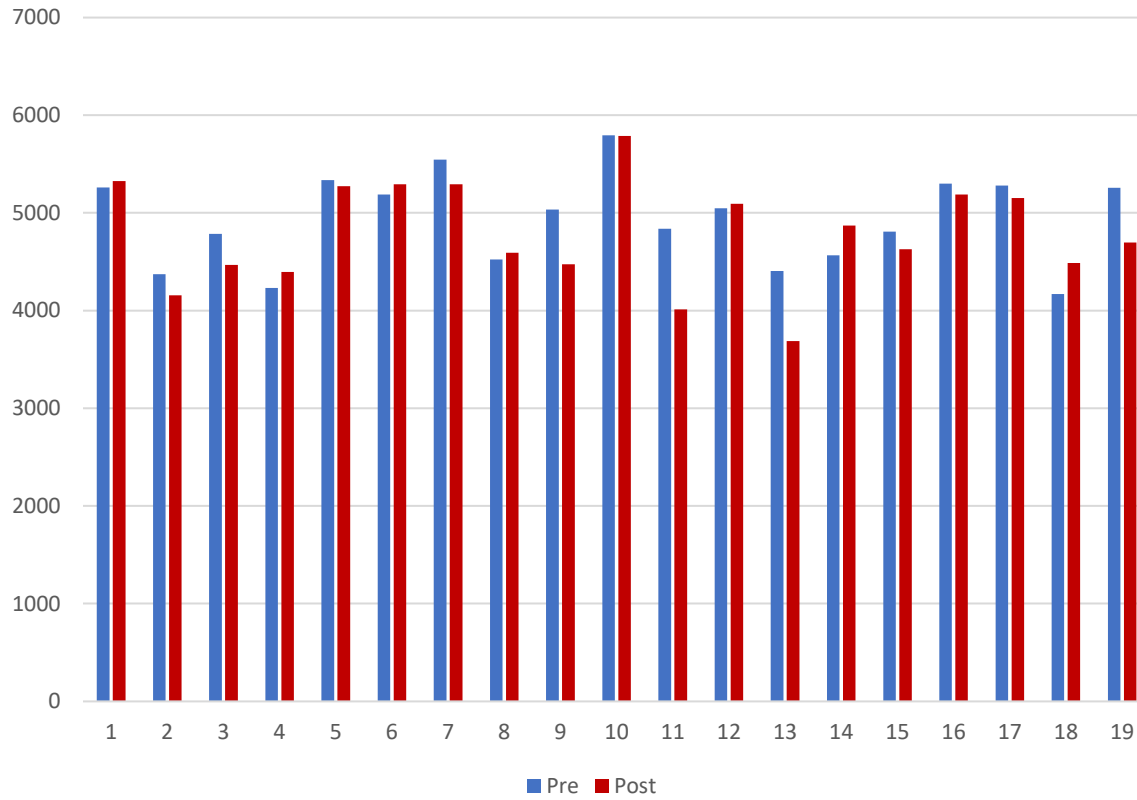


Left Hippocampus

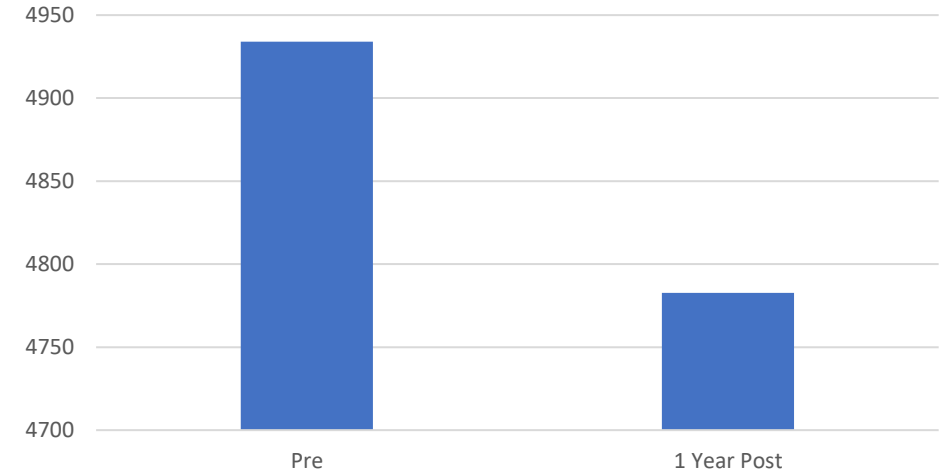


	Pre	Post
Average	4027	4087
STDEV	283	307
P		0.00821

Left Putamen (cubic mm)

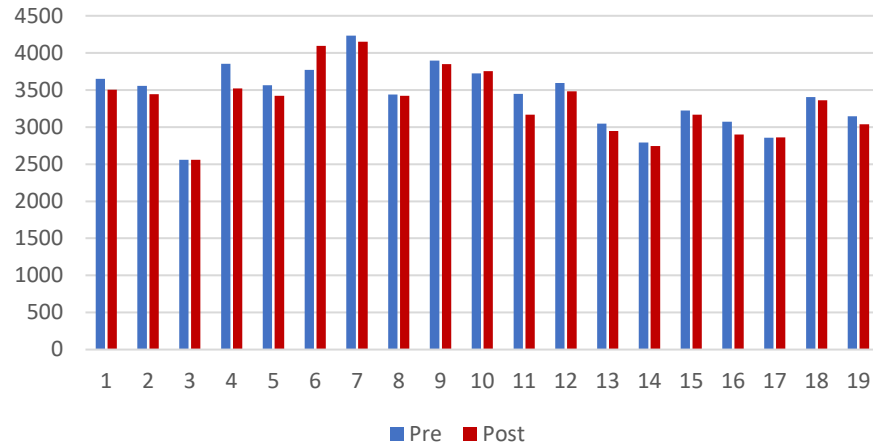


Left Putamen

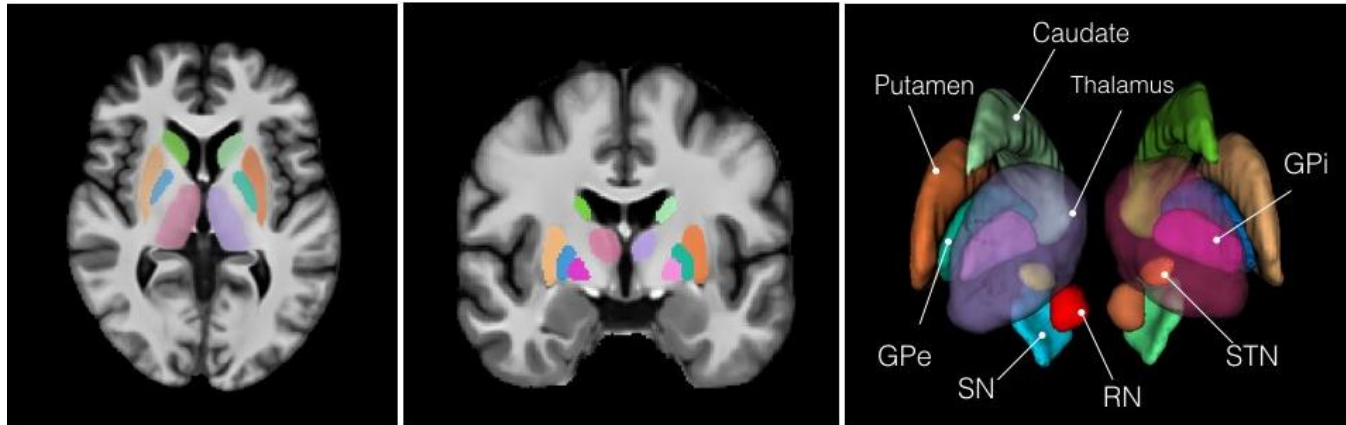
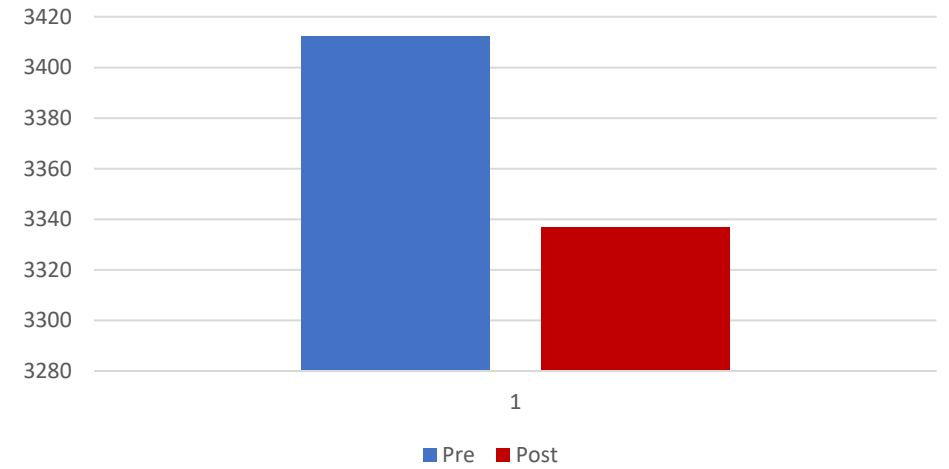


	Pre	Post
Average	4934	4783
STDEV	463	535
P		0.029

Right Caudate (cubic mm)



Right Caudate



	Pre	Post
Average	3412	3337
STDEV	425	438
P		0.0121

Clinical Relevance

- This study provides evidence of the neurological changes that take place 1 year after SG.
- They provide evidence of how the brain pathology observed in patients with obesity can be reversed with SG.
- The role of these brain networks and how and if they are related with weight loss requires future investigation.

Conclusions

- Structural changes in white matter volumes (cerebral white matter, posterior corpus callosum, left cerebellum), gray matter volumes (hippocampus, caudate, putamen) take place after SG.
- These changes may influence perceptions and relationships with food, body habitus, and feelings associated with eating and other neurological physiology.

Questions?

