

Management of Challenging Surgical Complications - Learning from real cases How to avoid disasters in MBS?

Almino Cardoso Ramos MD

MSc, PhD, FACS, FASMBS, FIFSO

Gastro-Obeso-Center/Sao Paulo/Brazil – Medical Director

IFSO President 2018-2019

President Brazilian Society for Bariatric and Metabolic Surgery –

SBCBM – 2013-2014

Consultant Surgeon Weight Loss Journey – Ecuador

Consultant Surgeon Elias Ortiz & Co - Mexico



Elias Ortiz & Company
MEXICO WEIGHT LOSS SPECIALISTS



XXVII Ifso World Congress



Melbourne 2024

No disclosures related to this presentation



XXVII Ifso World Congress



Melbourne 2024

Session 1.2.1 – 13:30am – 15:00pm – Room 203

Management of Challenging Surgical Complications - Learning from real cases - How to avoid disasters in MBS

Chair: Almino Ramos

Moderators: George Hopkins, Marina Kurian

Discussants: Shashank Shah (India-APC) Cristine Stier (Germany-EC) Ashraf Haddad (Jordania-MENAC) Pablo Omelanzuk (Argentina-LAC) Khaled Gawdat (Egypt-MENAC) Antonio Torres (Spain-EC)

Learning methodology: To present each clinical case in an escalating way of approach, exploring the different scenarios, looking for the consensus about the safest solution for the different complications presented.

Goal: After discussion of each case to evaluate what have been done and what could have been done in different perspectives for the patients, always looking for prevention and better solutions



Elias Ortiz & Company
MEXICO WEIGHT LOSS SPECIALISTS

XXVII Ifso World Congress



Melbourne 2024

Session 1.2.1 – 13:30am – 15:00pm – Room 203

Management of Challenging Surgical Complications - Learning from real cases - How to avoid disasters in MBS

Chair: Almino Ramos

Moderators: George Hopkins, Marina Kurian

Discussants: Shashank Shah (India-APC) Cristine Stier (Germany-EC) Ashraf Haddad (Jordania-MENAC) Pablo Omelanzuk (Argentina-LAC) Khaled Gawdat (Egypt-MENAC) Antonio Torres (Spain-EC)

Case 1: Female, 32 years old, BMI 36 kg/m² – Starting with severe abdominal pain in POD 4 after a LSG

Case 2: Female, 50 years old, BMI 52 kg/m² – Unexpected intraoperative severe bleeding in the dissection of the greater curve in a LSG

Case 3: Male, 53 years old, BMI 27 kg/m², RYGB 18 months ago, presenting chronic abdominal pain in the last months but now with 18h of severe acute pain and tachycardia



XXVII Ifso World Congress



Melbourne 2024

Case 1: Female, 32 years old, BMI 36 kg/m² – Starting with severe abdominal pain in POD 4 after a LSG

**Jan 08, 2021 – Laparoscopic Sleeve Gastrectomy with intraop identification of a 3 cm HH
LSG done over a 36 Fr bougie
Starting 5 cm from the pylorus
Invaginating stapler line suture reinforcement
Crura repair
Jackson Pratt drainage**

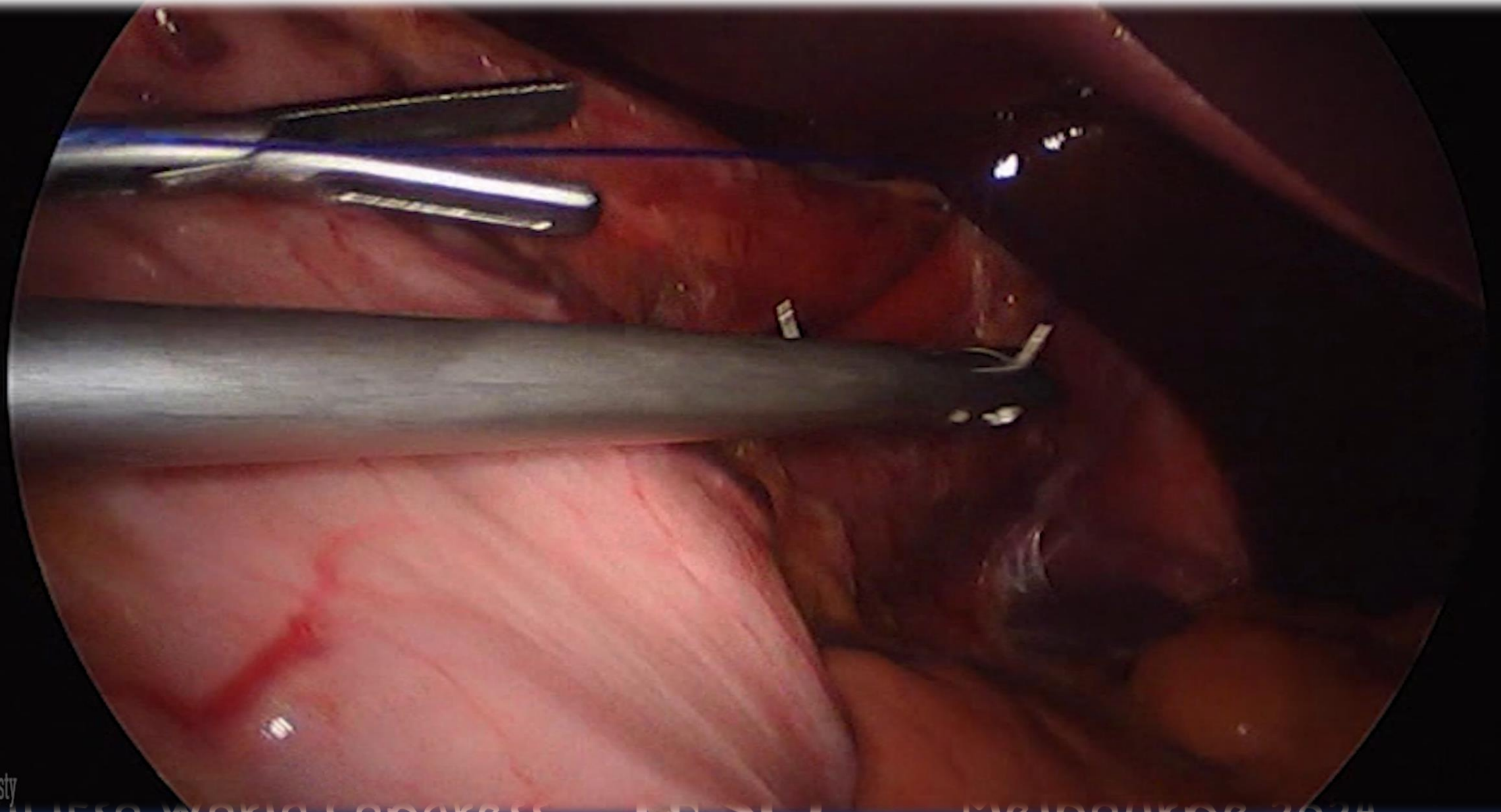
Jan 09, 2021 – Fluoroscopy – Easy progression of the radiologic contrast with no leaks

Jan 10, 2021 - Hospital discharge

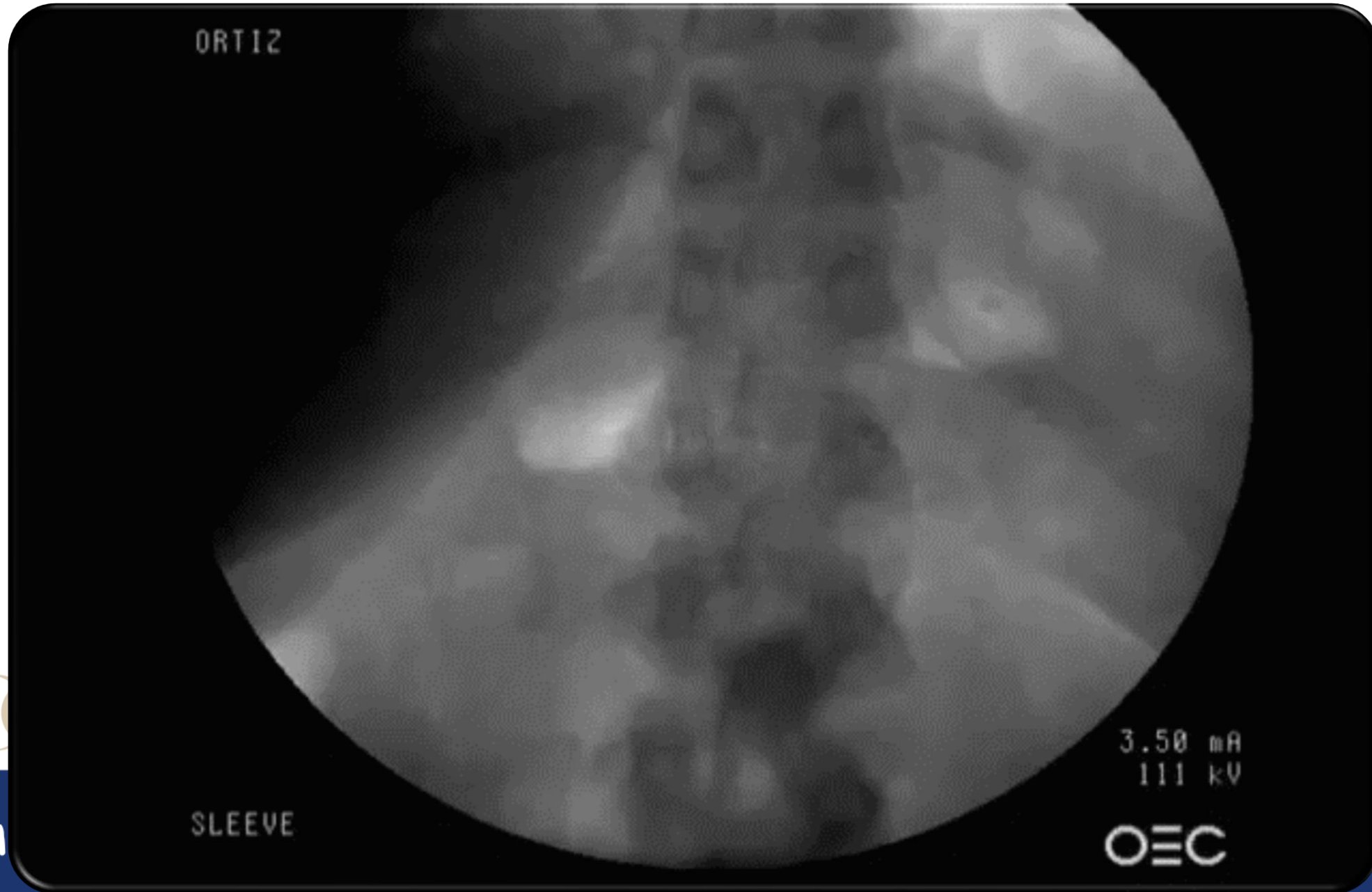

Elias Ortiz & Company
MEXICO WEIGHT LOSS SPECIALISTS

January 8, 2021 – LSG + Crura Repair



Jan 09, 2021 – Fluoroscopy



ORT12

3.50 mA
111 kV

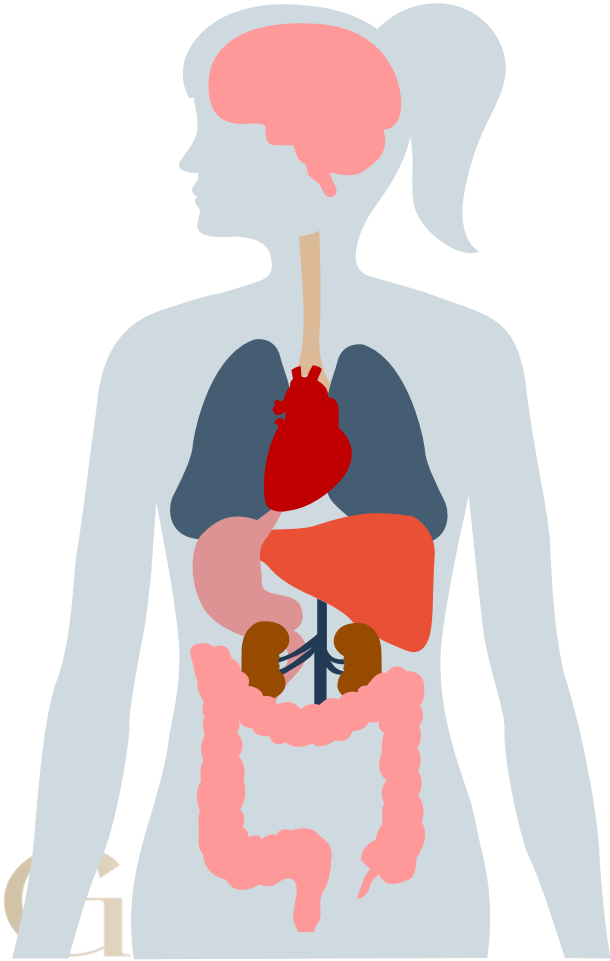
SLEEVE

OEC

GO

iz & Company
HT LOSS SPECIALISTS

XXVII



Jan 12 – 4 POD

Severe abdominal pain

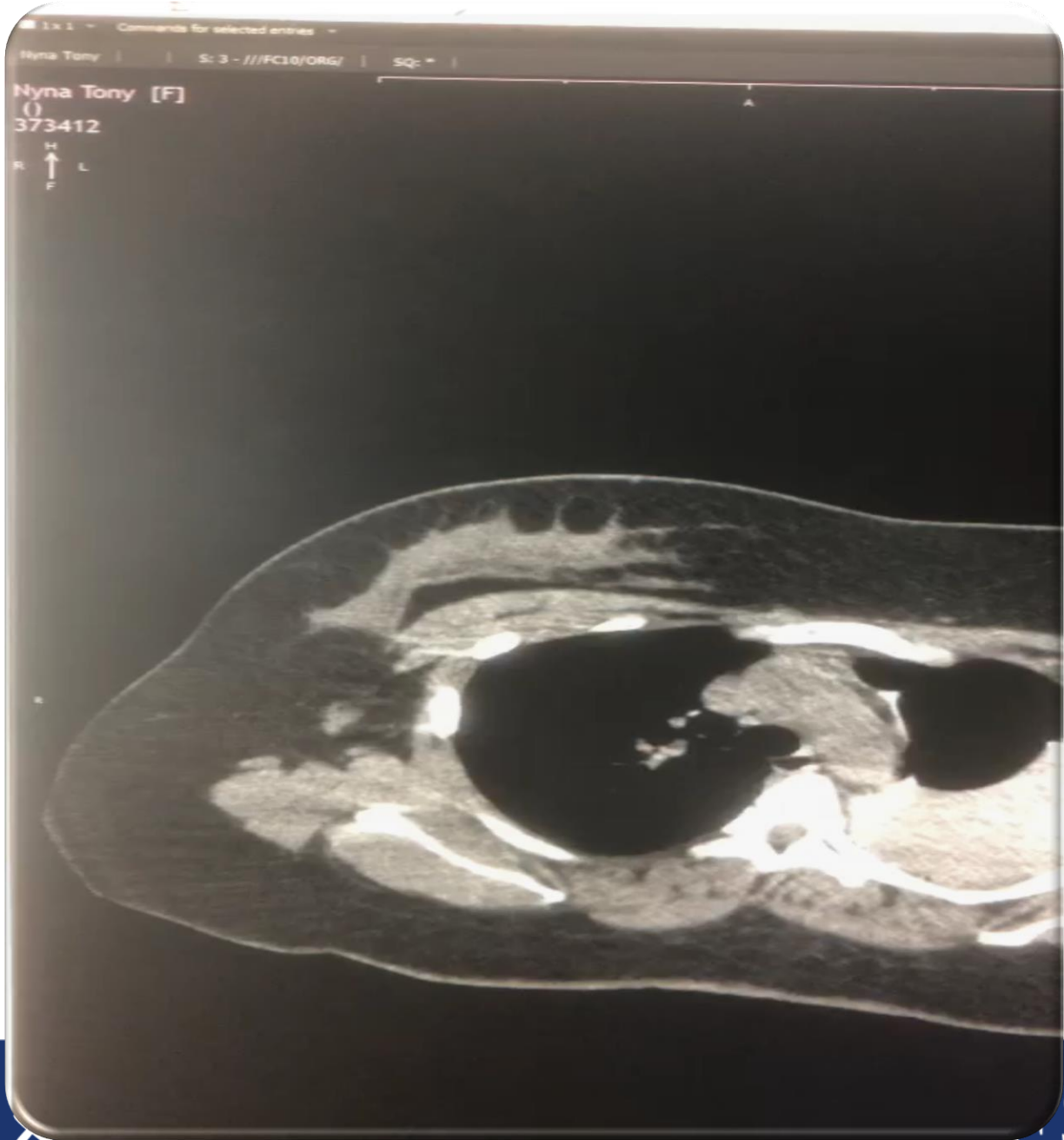Taquicardia

Nausea



Elias Ortiz & Company
MEXICO WEIGHT LOSS SPECIALISTS

Jan 12 - Rehospitalization



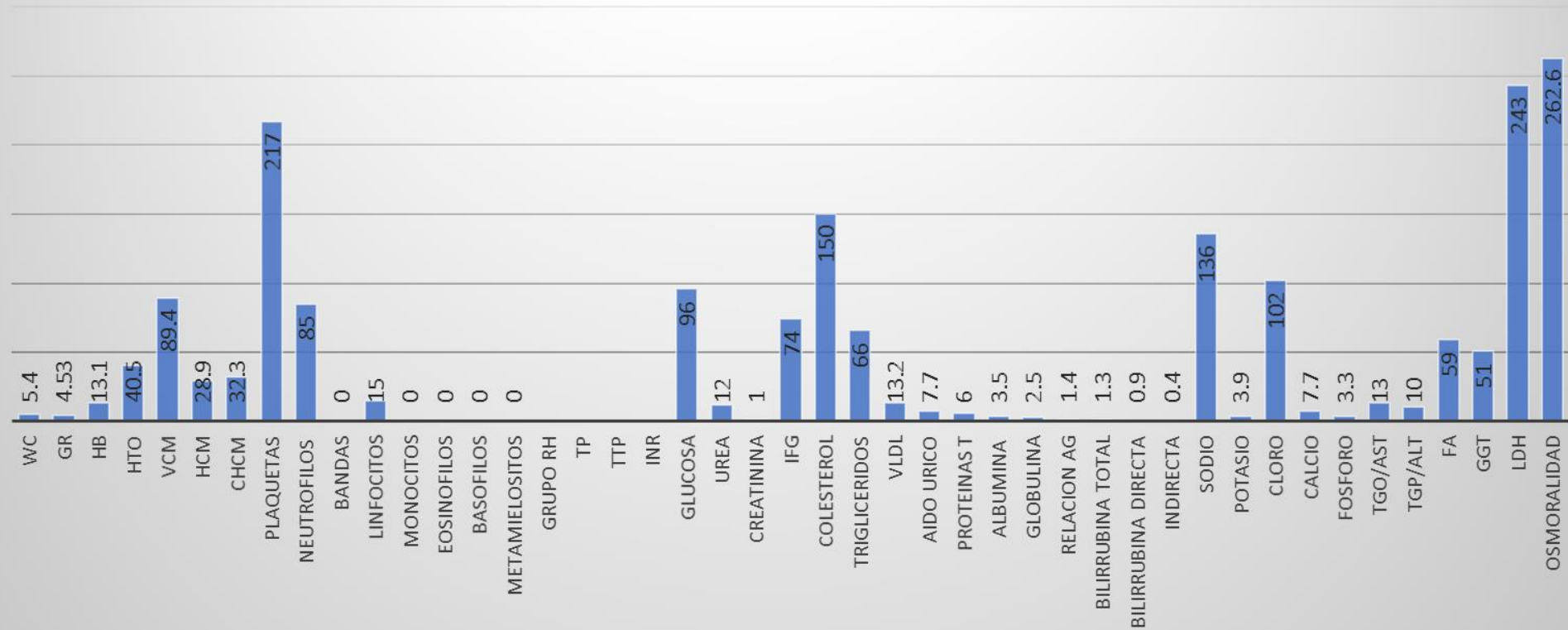
Elias Ortiz & Company
MEXICO WEIGHT LOSS SPECIALISTS

SO
MELBOURNE 2024

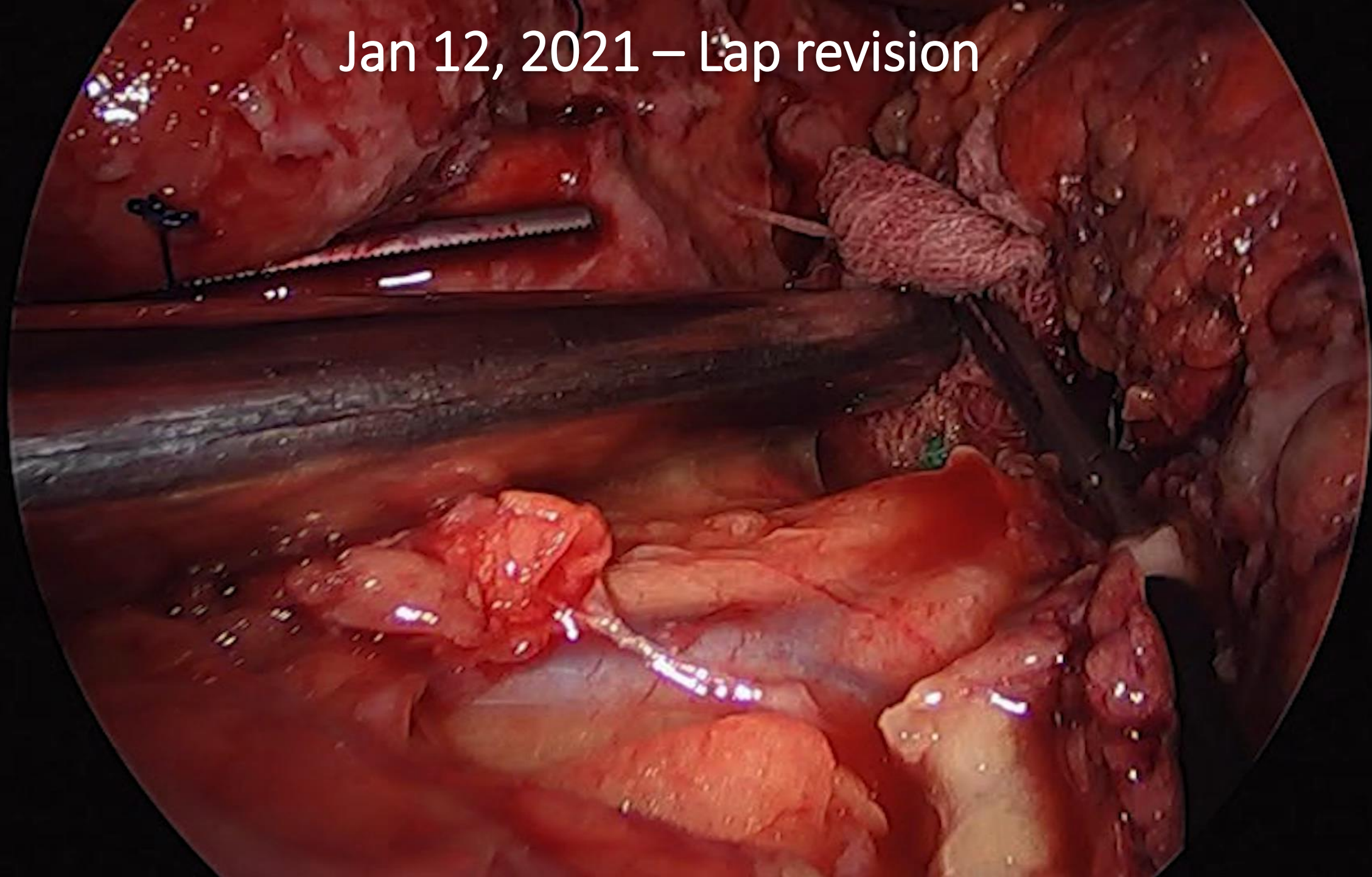
Melbourne 2024

Jan 12, 2021 - Rehospitalization

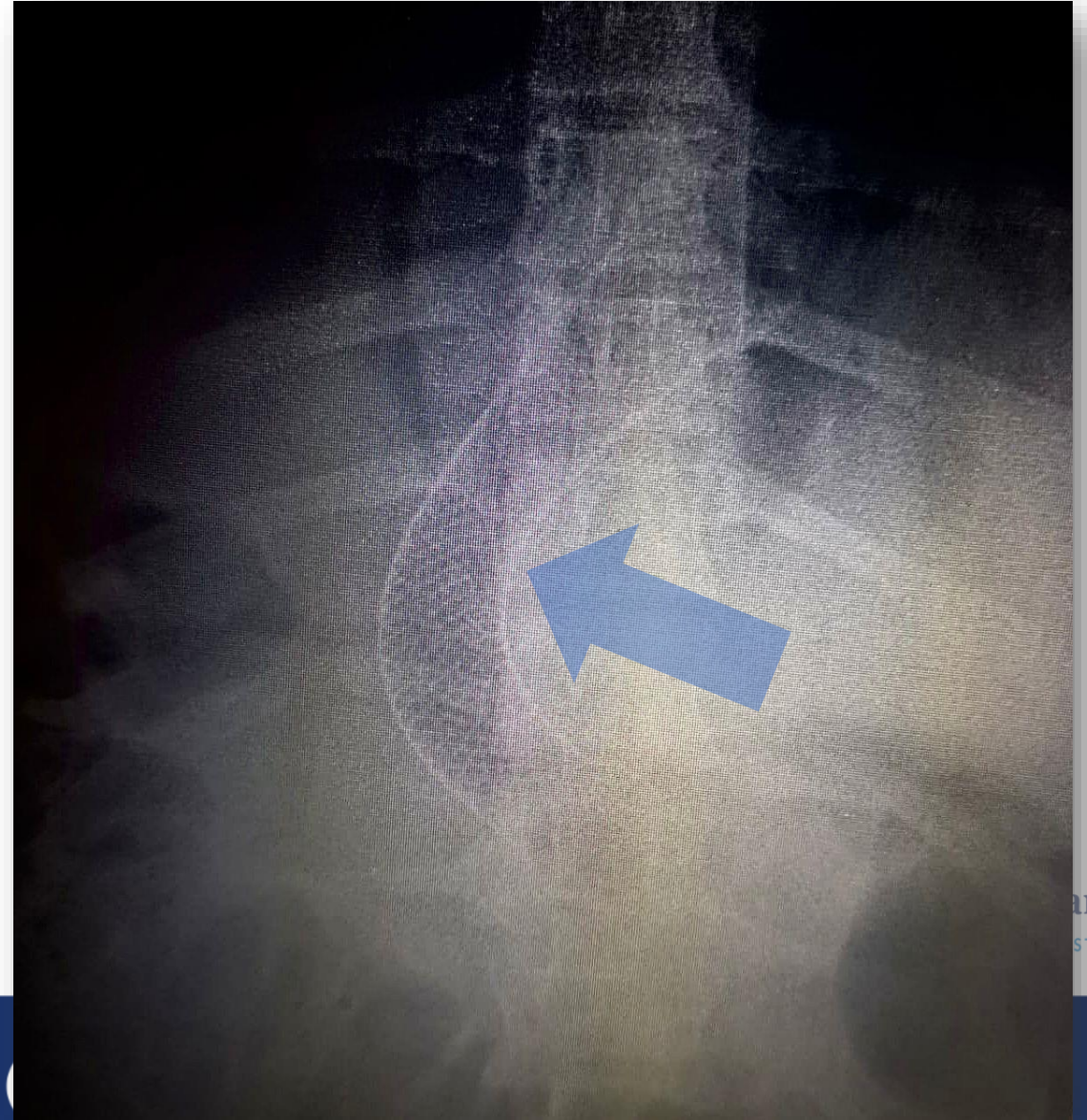
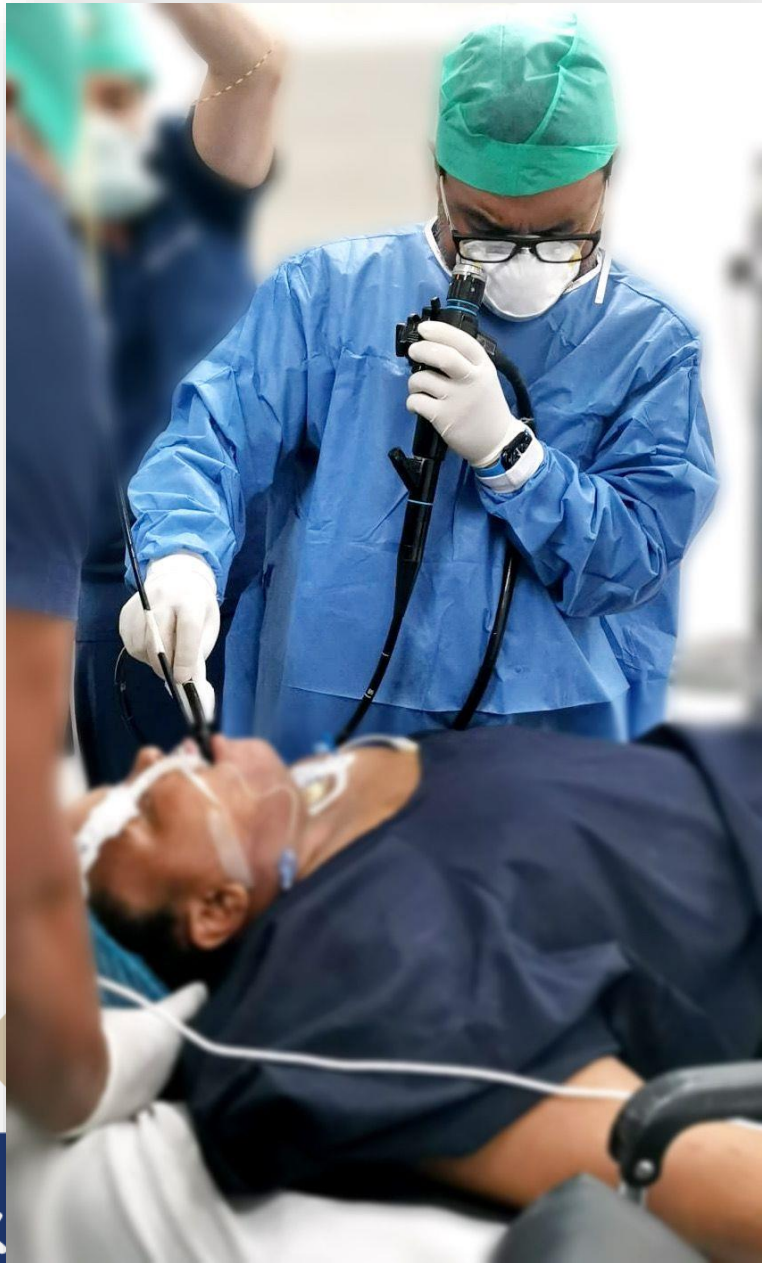
LABS 01/12/2021



Jan 12, 2021 – Lap revision

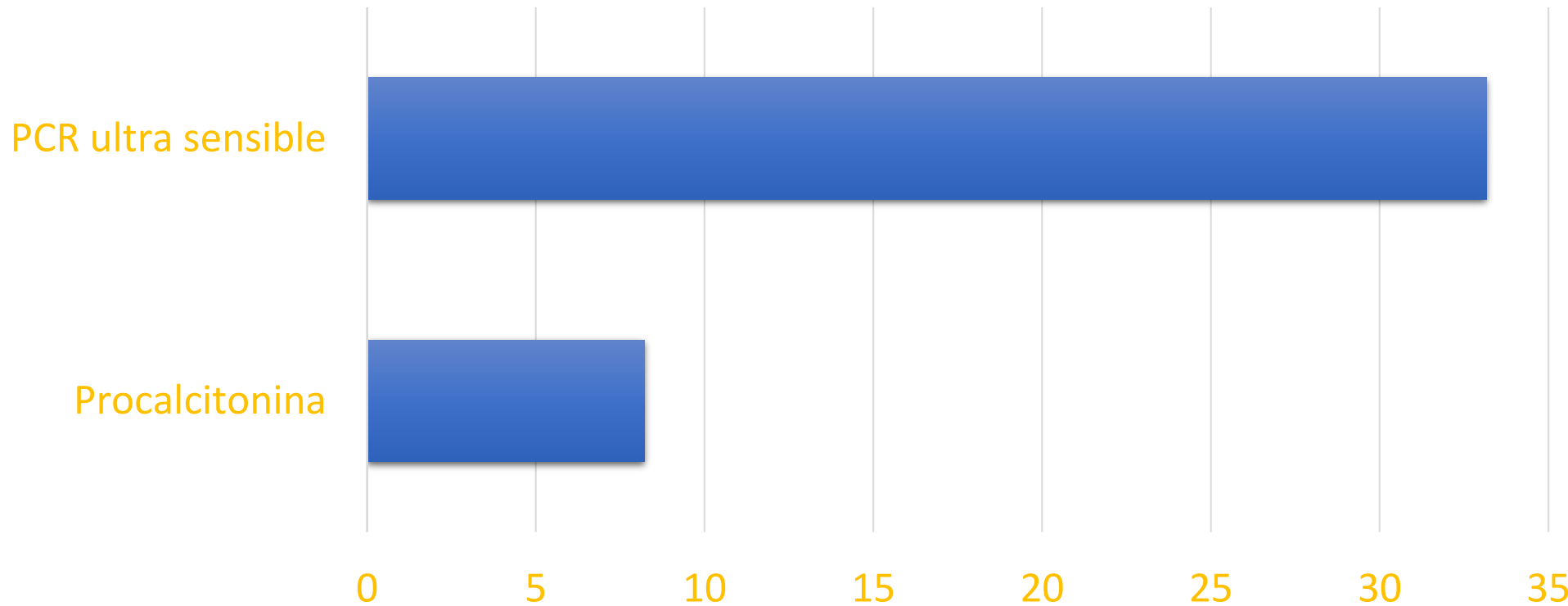


Jan 13, 2021 – Endoscopic Stent

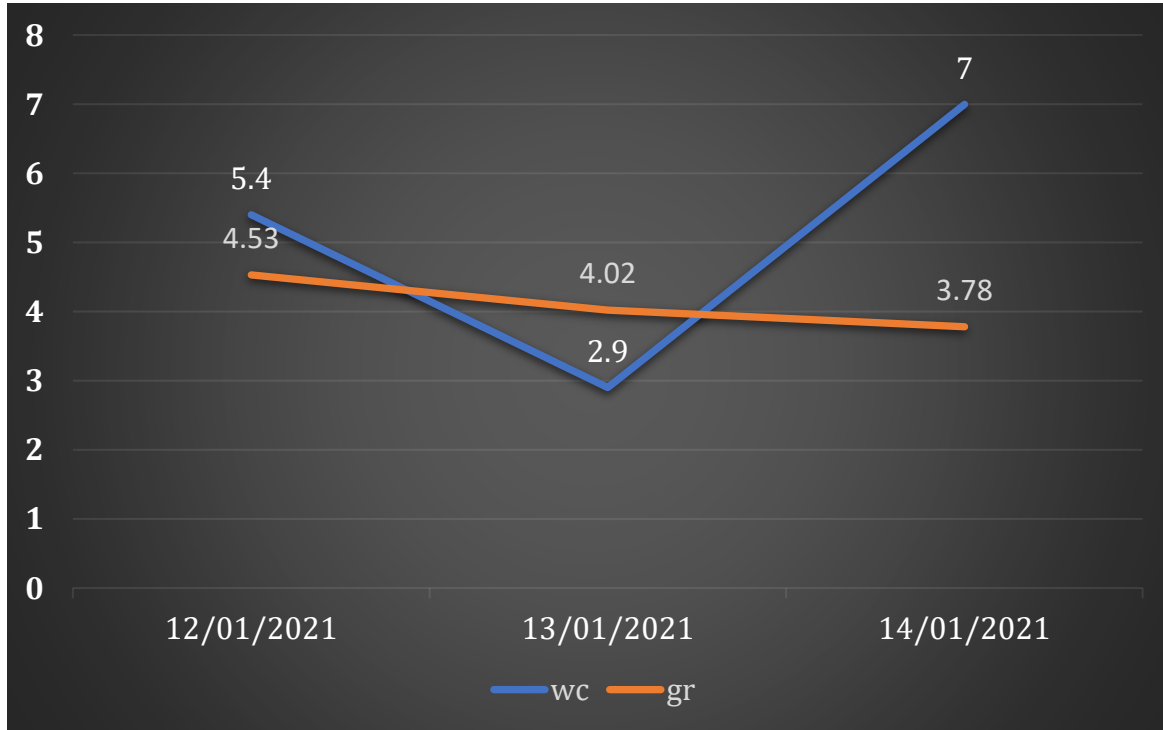


gress

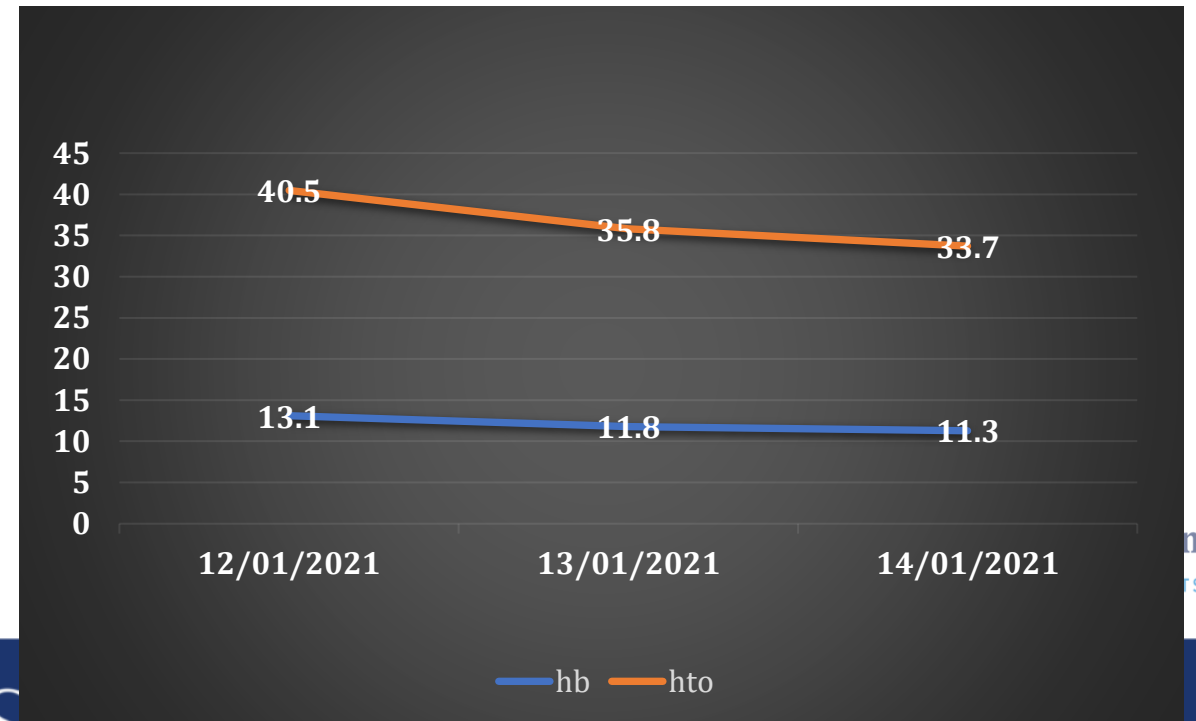
Jan 13, 2021 Sepsis Markers



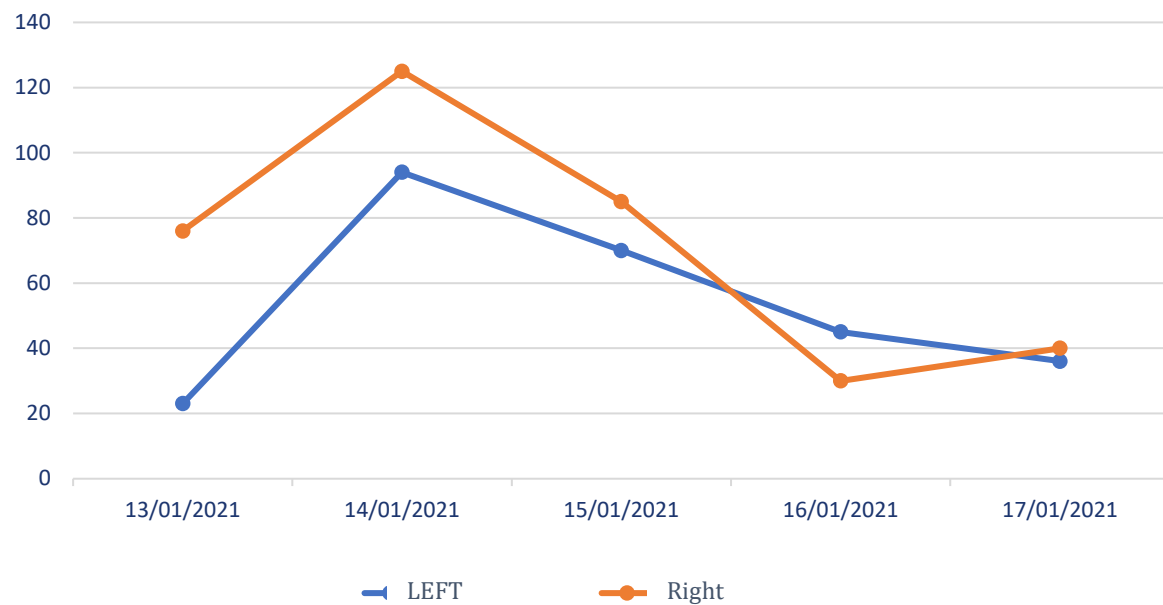
Leukocytes Jan 14, 2021



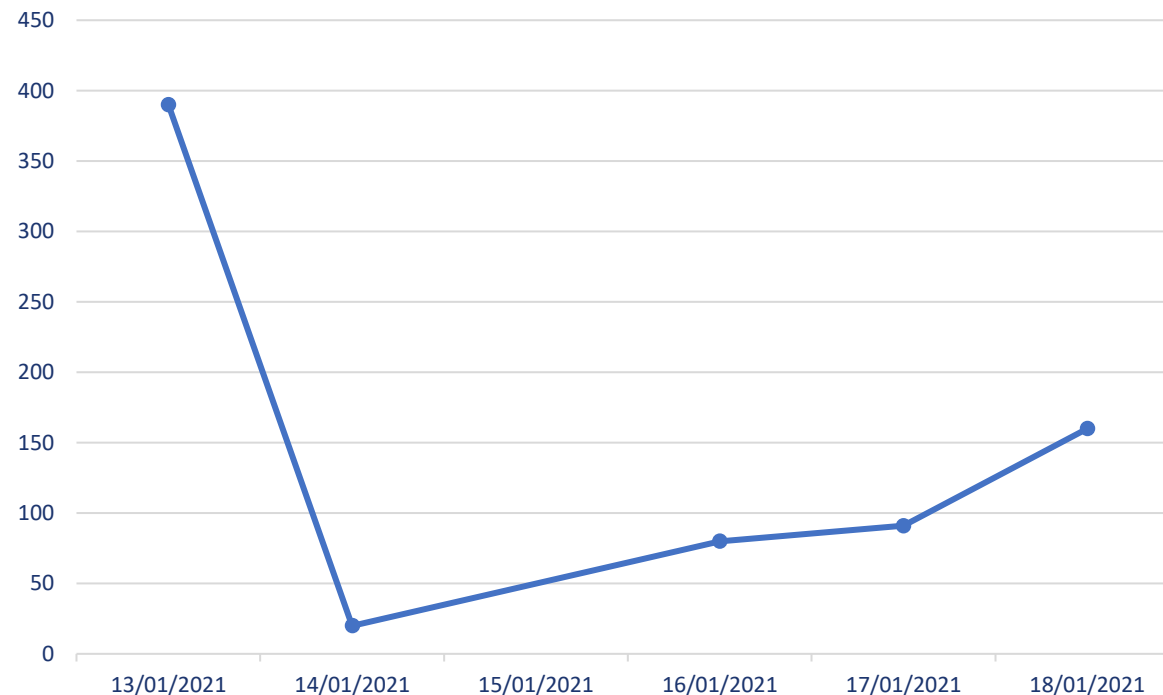
Ht / Hb Jan 14, 2021



Abdominal Drainage

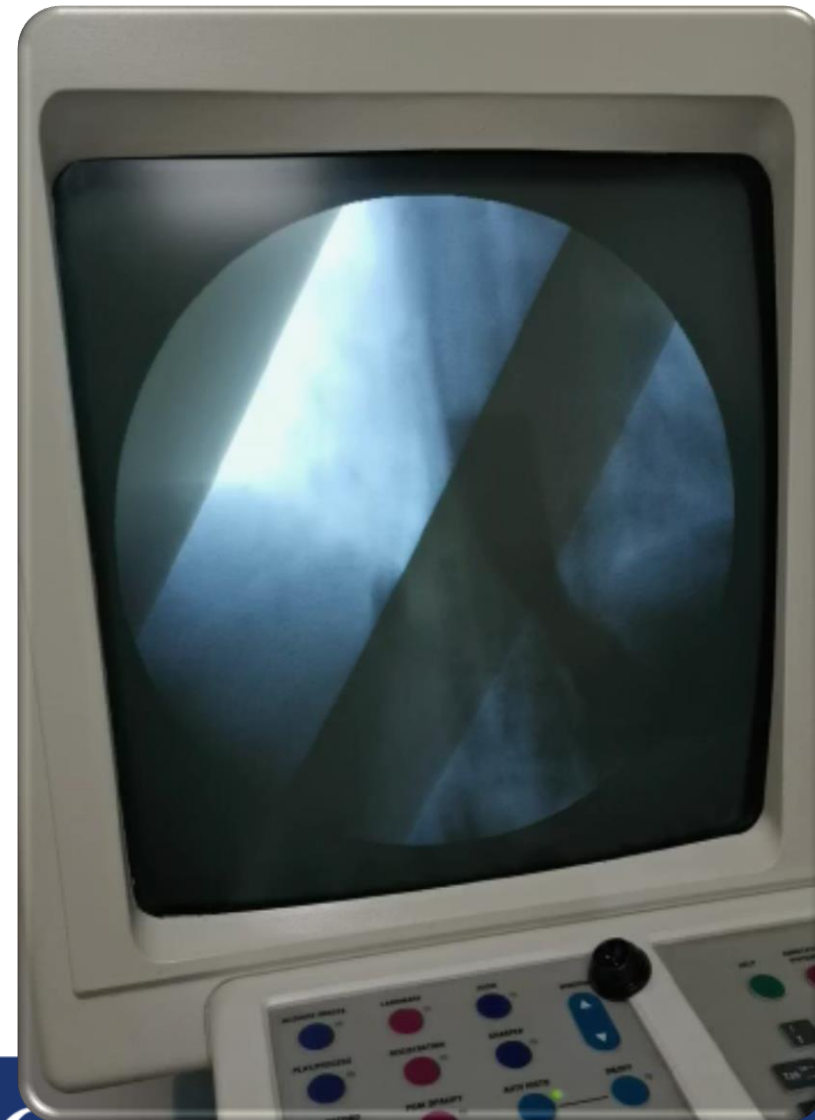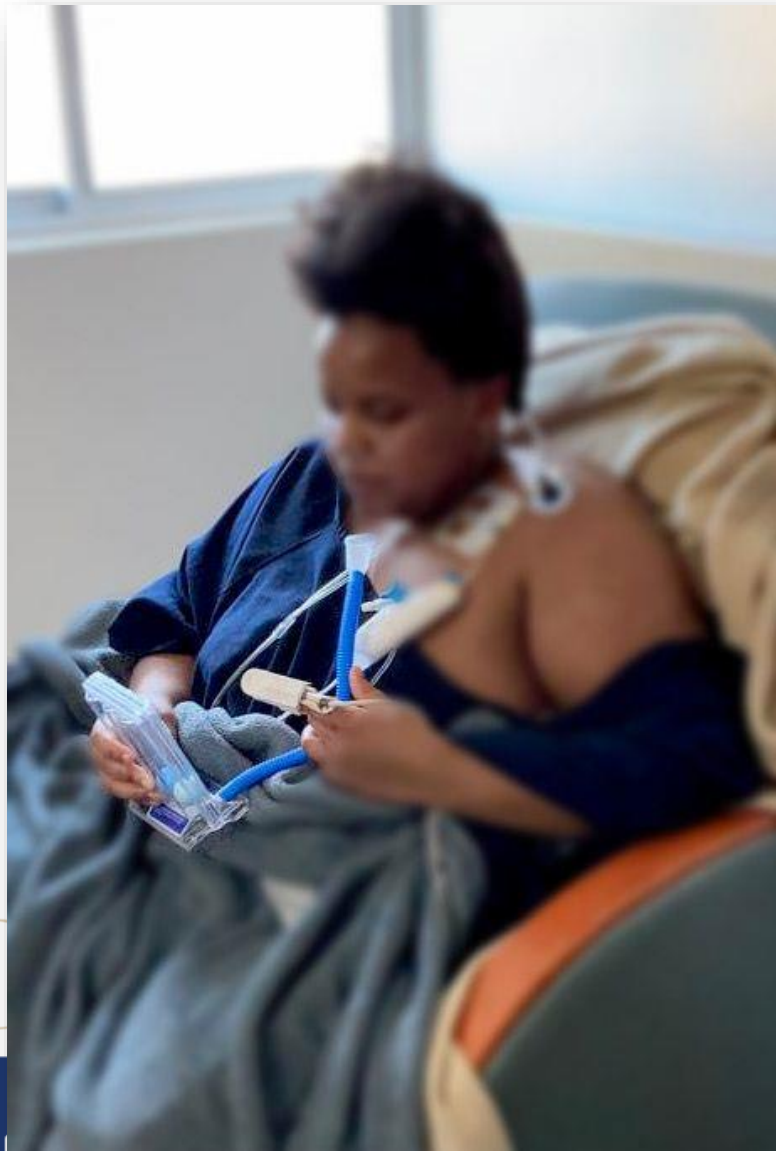


Left Pleural Drainage



Elias Ortiz & Company
MEXICO WEIGHT LOSS SPECIALISTS

Jan 18, 2021 – Patient Stable



as Ortiz & Company
ICO WEIGHT LOSS SPECIALISTS

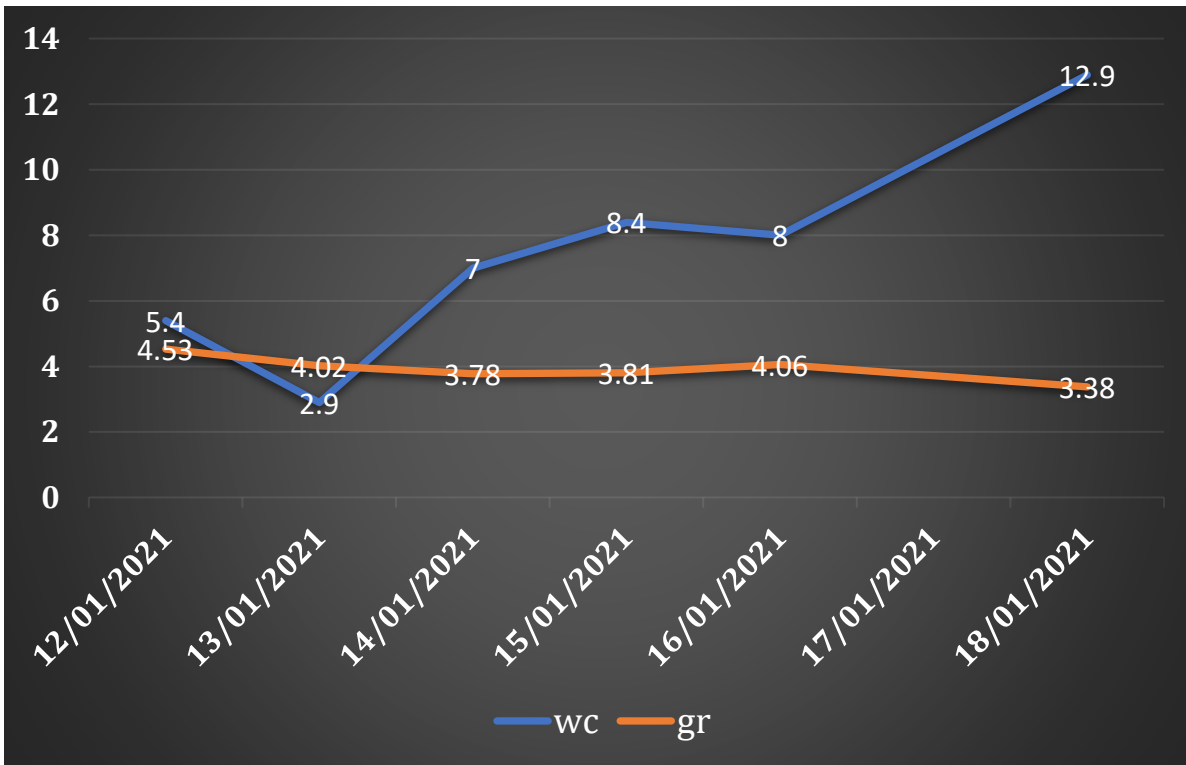
GO

XXVII IFSO World Congress

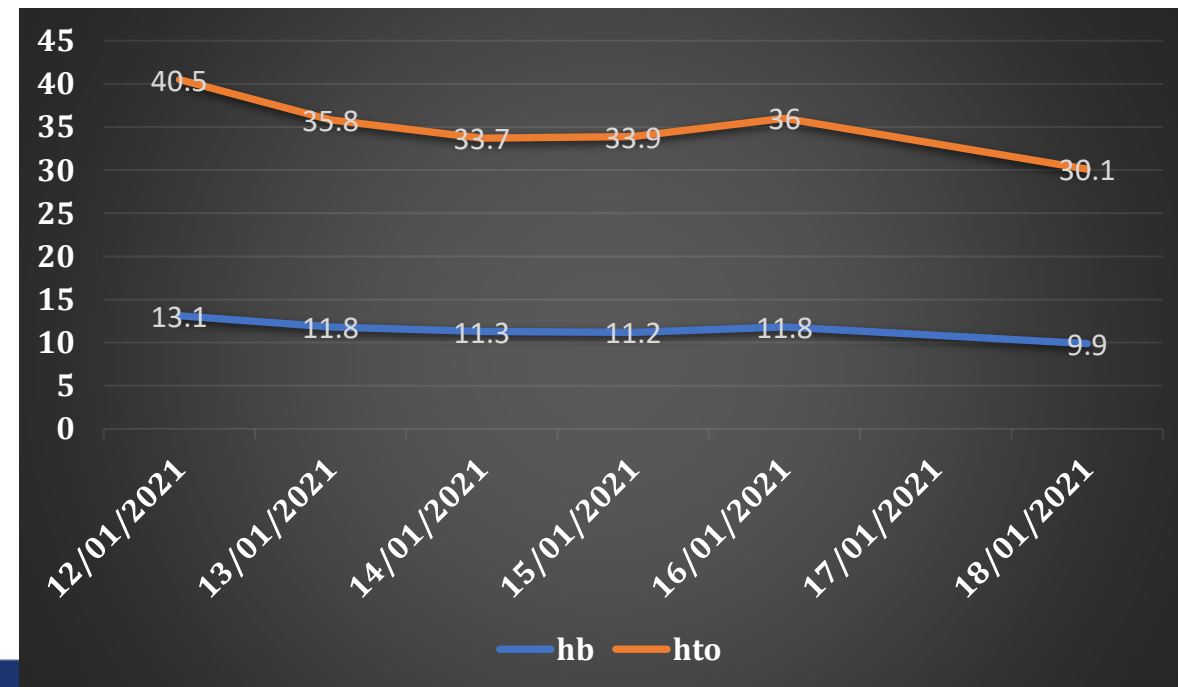


Melbourne 2024

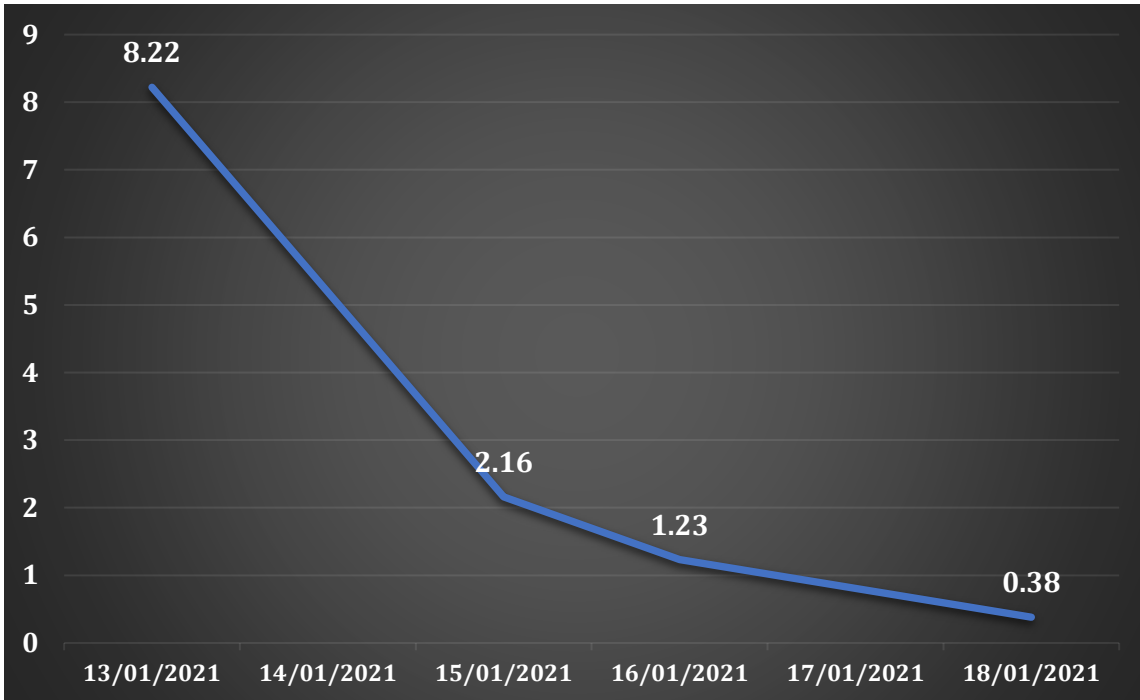
Leukocites



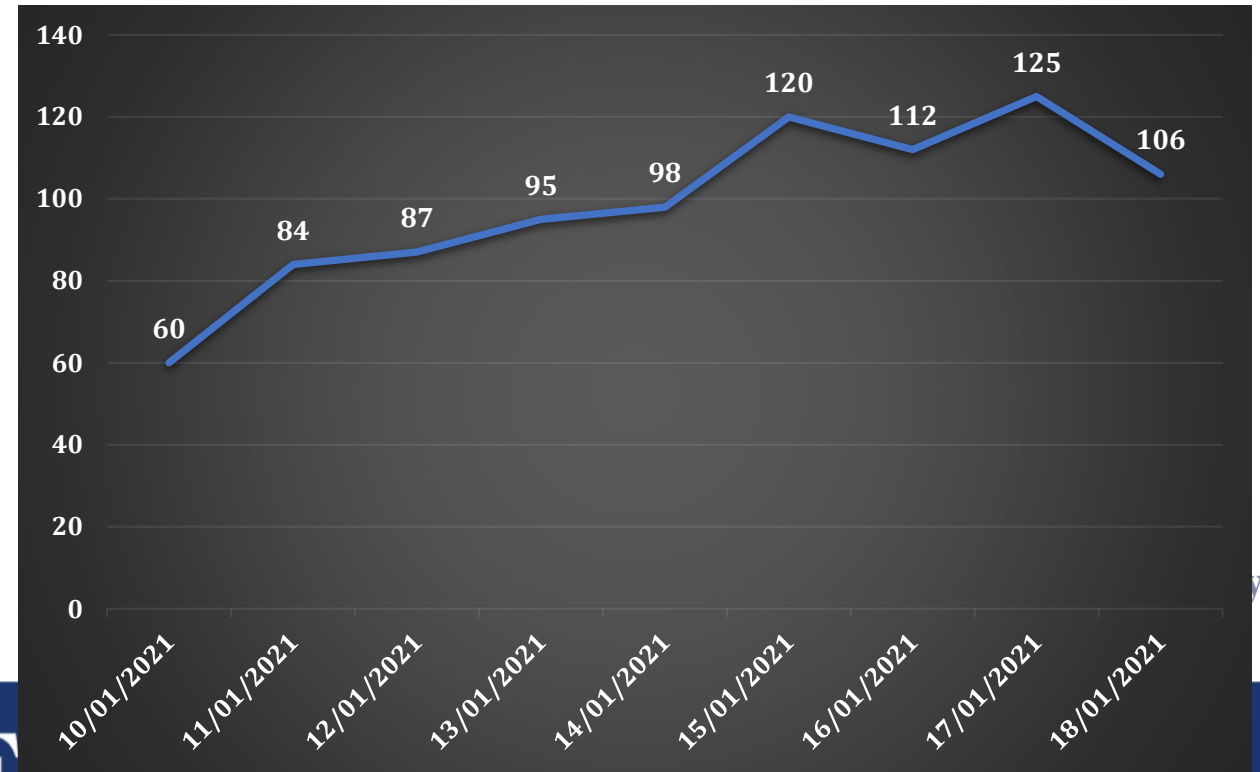
Red Count



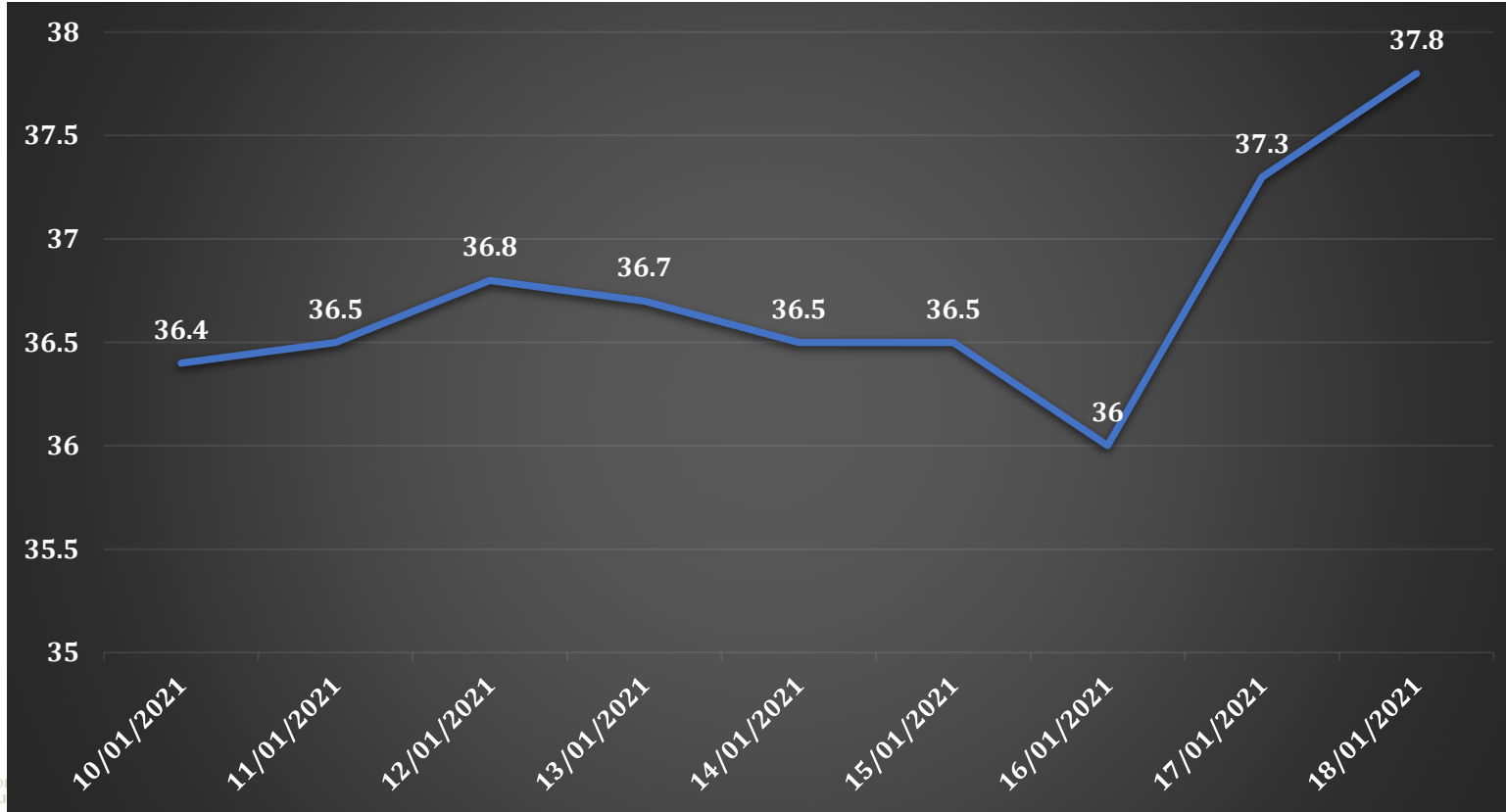
PROCALCITONIN



Heart Rate



Temperature



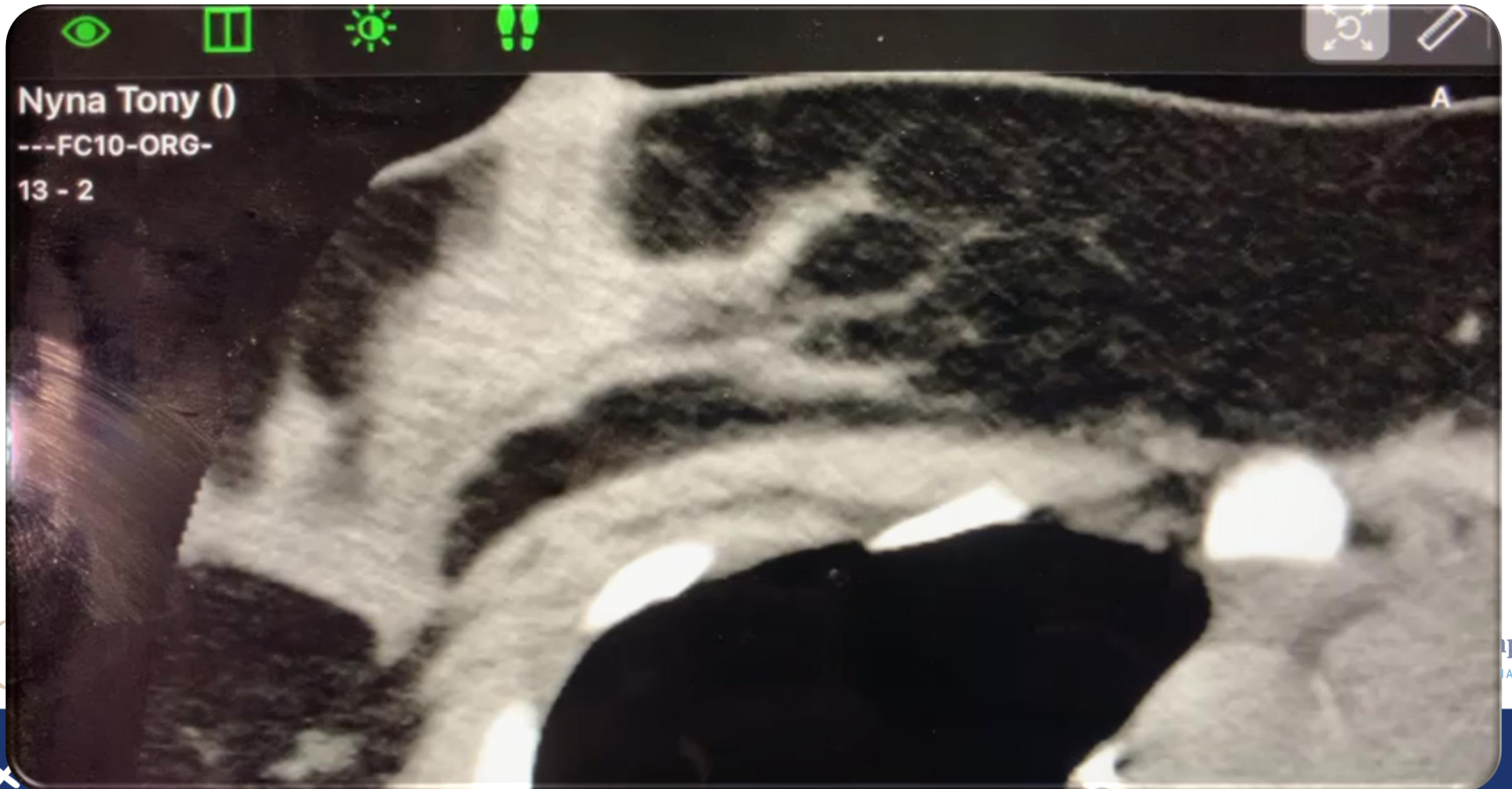
Elias Ortiz & Company
MEXICO WEIGHT LOSS SPECIALISTS

XXVII Ifso World Congress

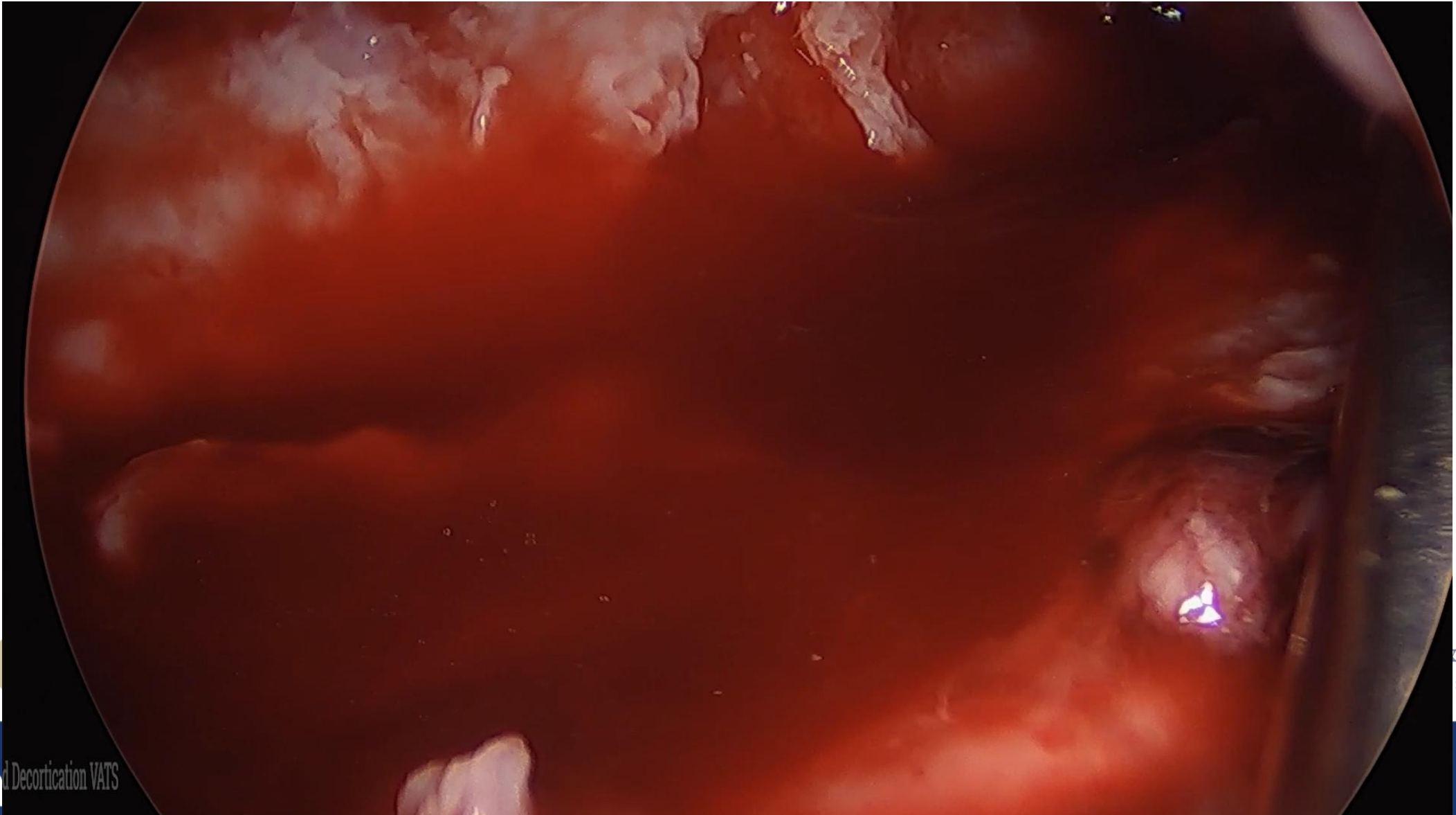


Melbourne 2024

CT Scan Jan 19, 2021



Jan 20, 2021 – VATS – Decortication - Drainage


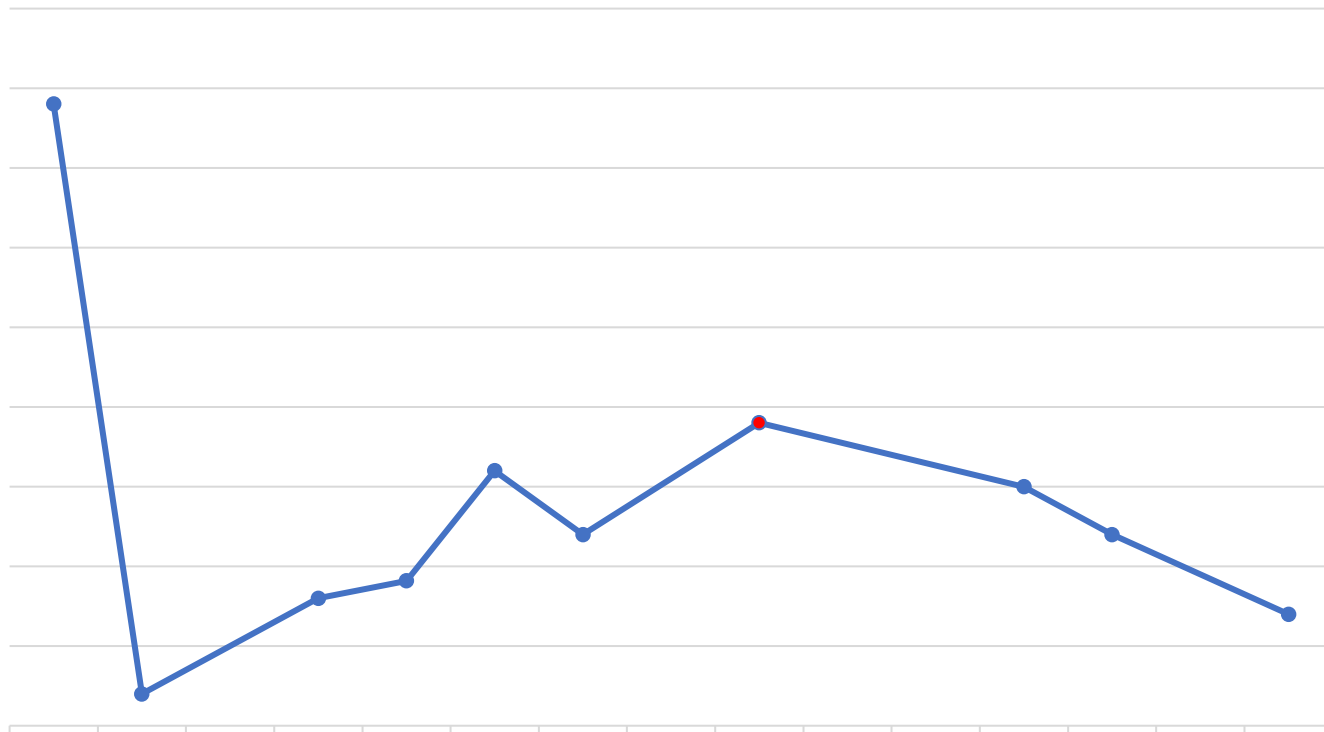


GO

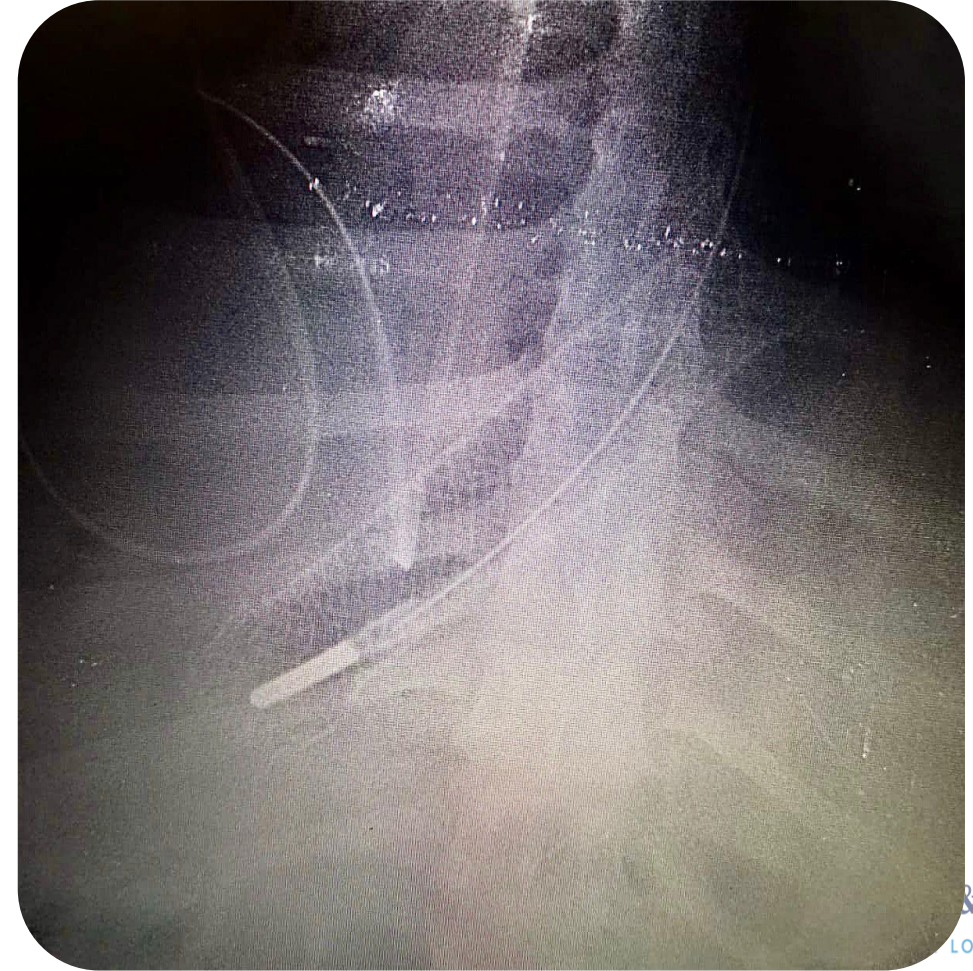
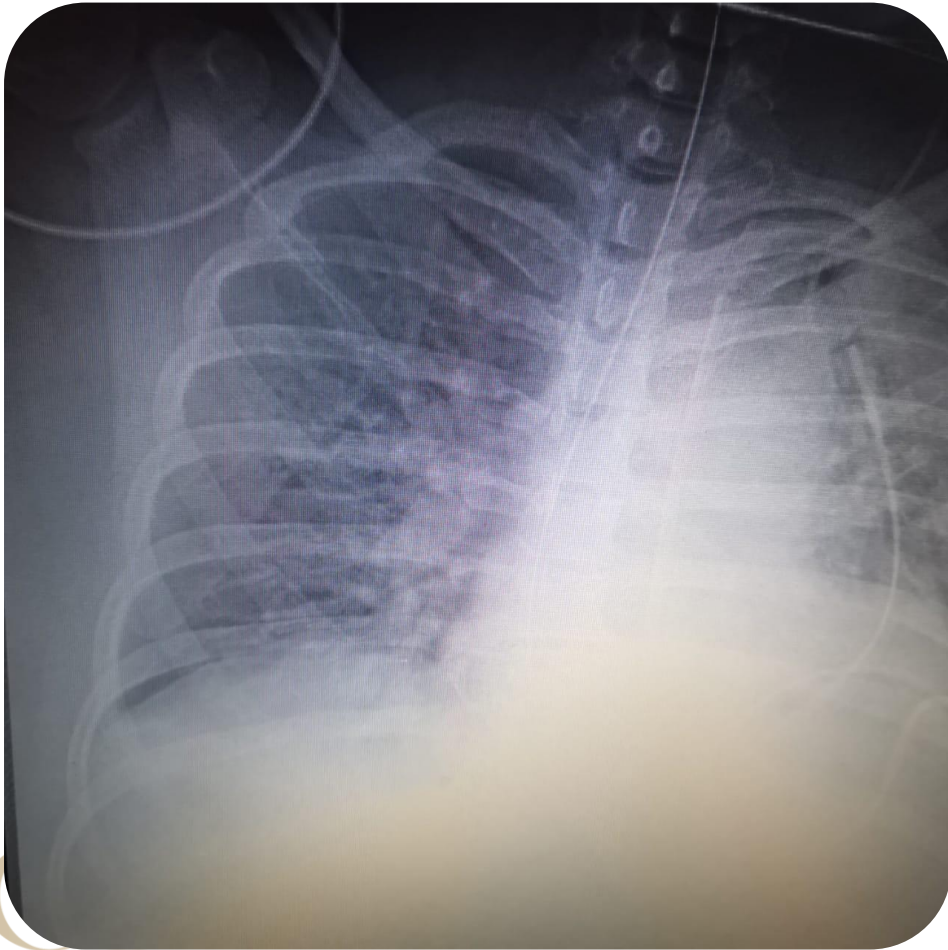
xxv
Decortication VATS

Company
SS SPECIALISTS

REDAX Left Thoracic Drainage



Jan 20,2021 - Repositioning Stent



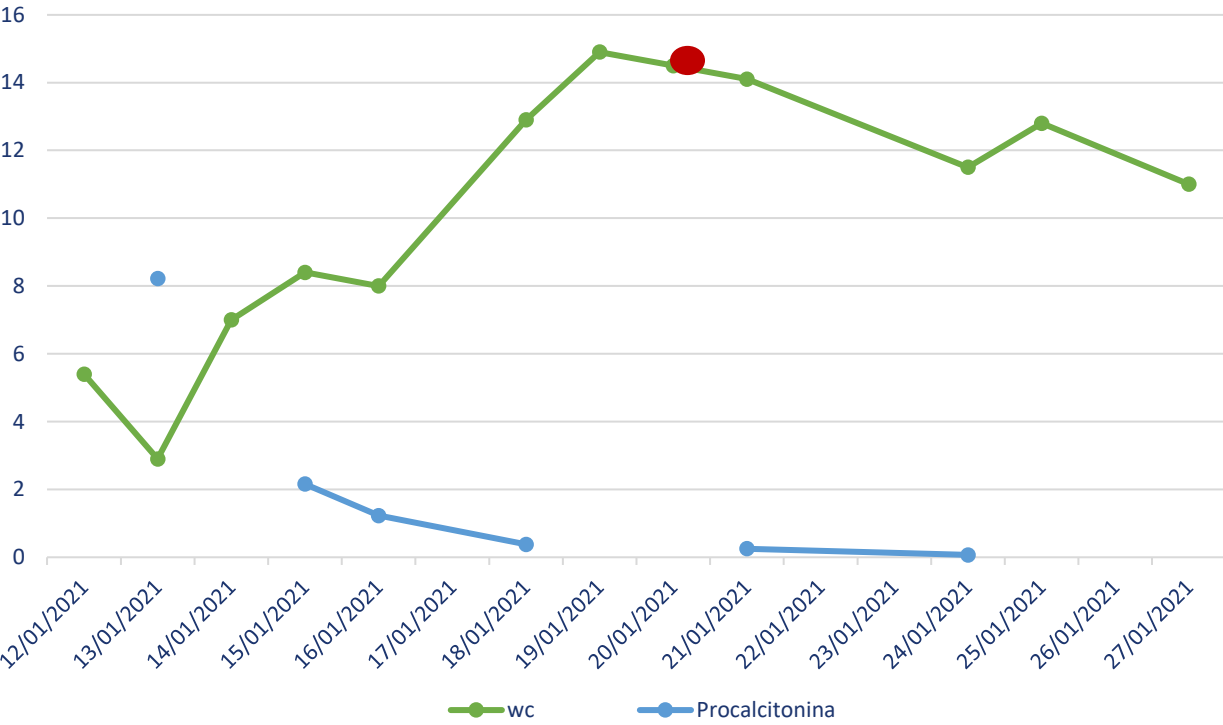
Antibiotics & Cultures

ANTIBIOTICO	Dias
Levofloxacino	3
Piperacillina	9
Meropenem	10
Fluconazole	5

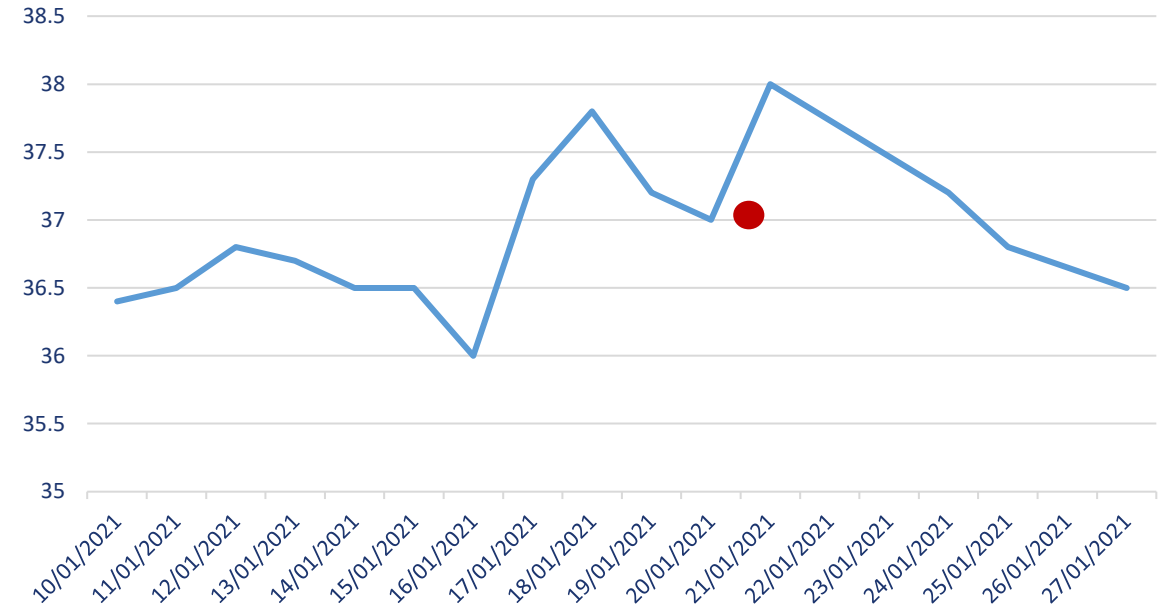
Cultivo de derrame pleural	RESULTADO	Fecfha
Candida albicans	POSITIVE	01/22/2021
Enterococo feacalis	POSITIVE	01/22/2021
Cocos Gram Positivos	POSITIVE	01/22/2021



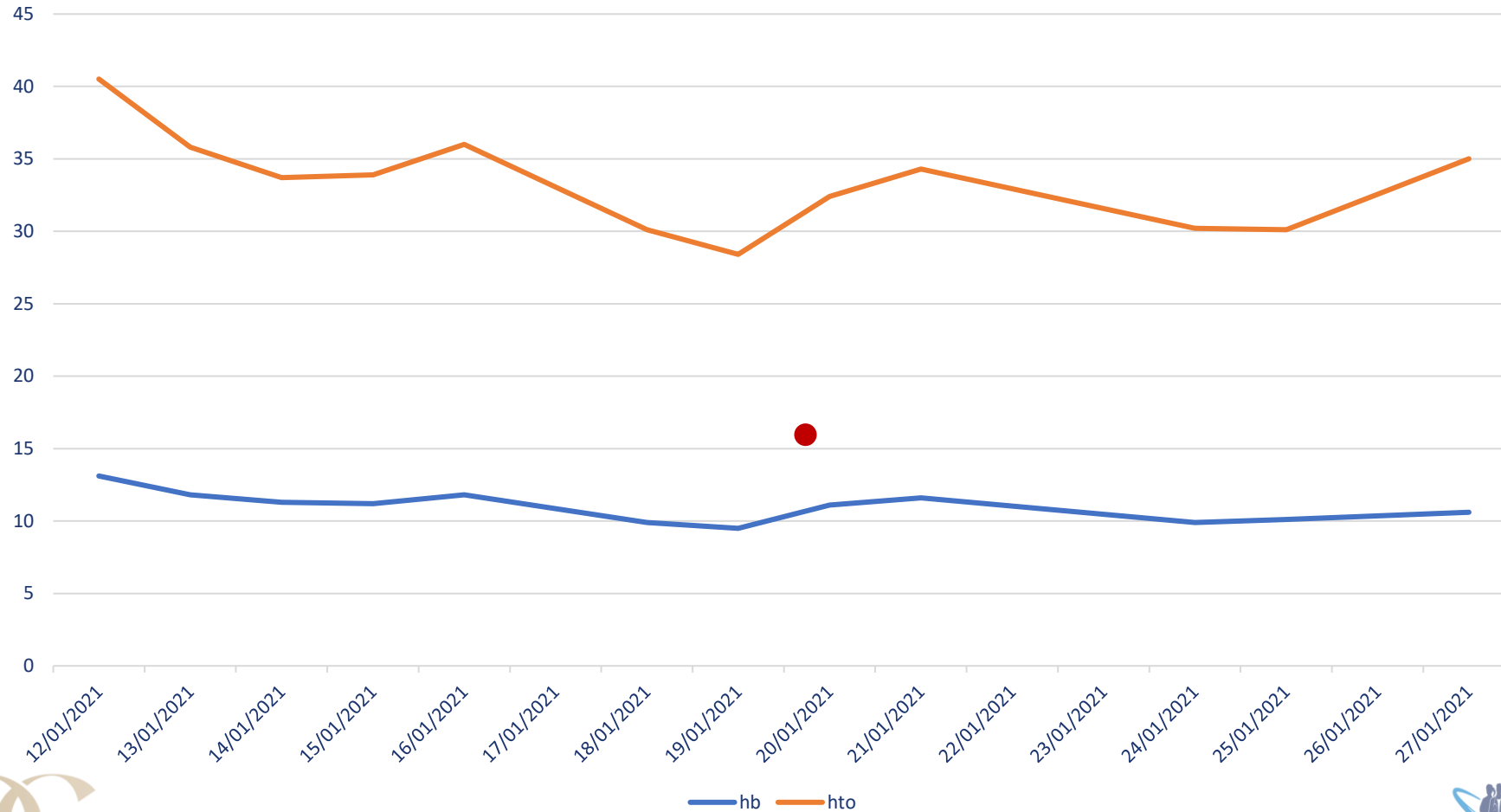
Inflammatory Parameters



Temperature



Red Count



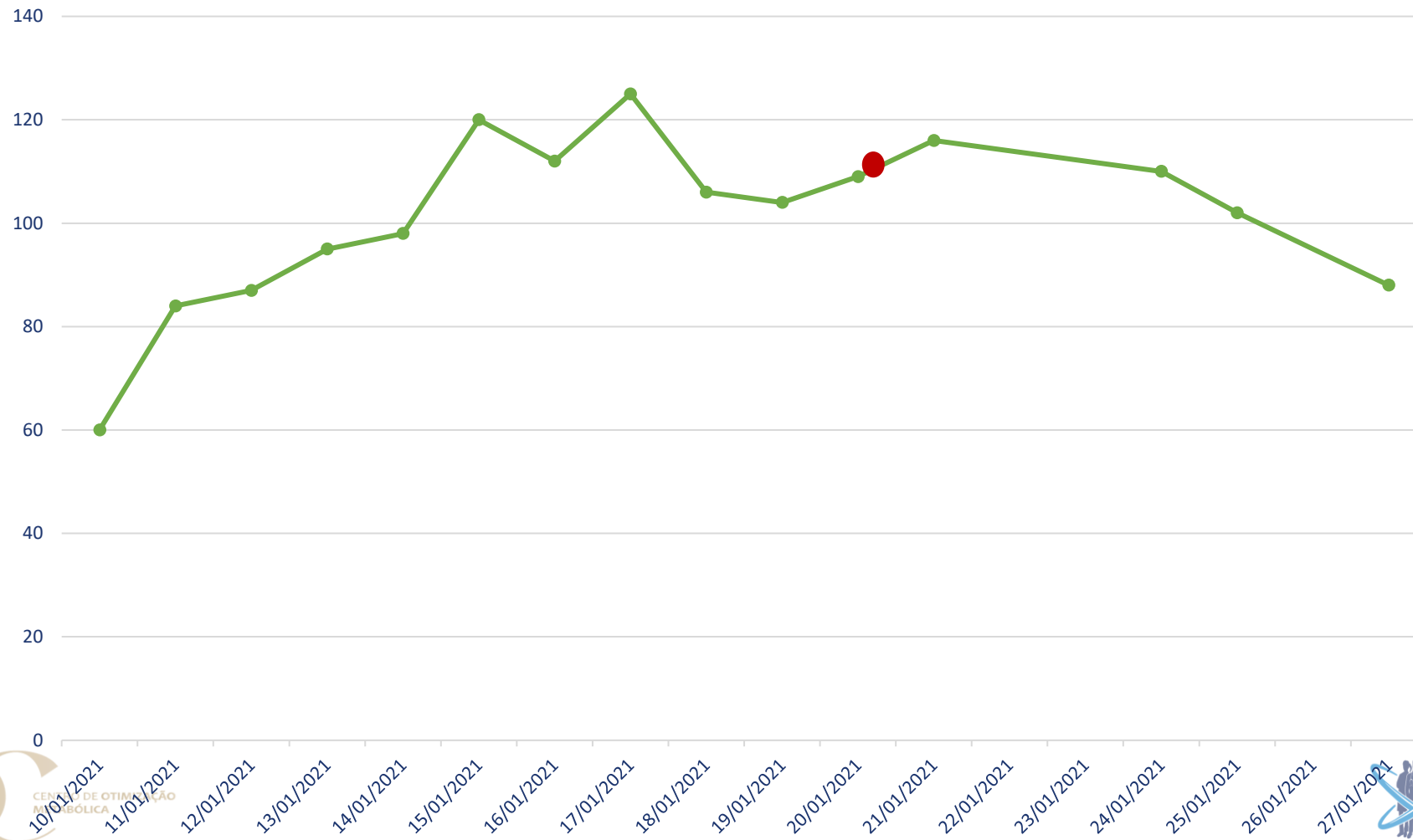
Elias Ortiz & Company
MEXICO WEIGHT LOSS SPECIALISTS

XXVII Ifso World Congress



Melbourne 2024

Heart Rate



CENTRO DE OTIMIZAÇÃO METABÓLICA



Elias Ortiz & Company
MEXICO WEIGHT LOSS SPECIALISTS

XXVII Ifso World Congress



Melbourne 2024



GCC
CENTRO DE OTIMIZAÇÃO
METABÓLICA

☐ Jan 8 - Surgery

☐ Jan 28 - Discharge

☐ BMI 30



Elias Ortiz & Company
MEXICO WEIGHT LOSS SPECIALISTS

XXVII Ifso World Congress

IFSO
MELBOURNE 2024

Melbourne 2024



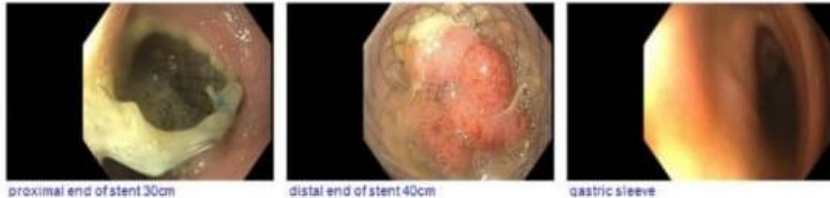Thomas Jefferson University Hospital
132 South 10th Street
Philadelphia, PA 19107
215-955-8900

Esophagogastroduodenoscopy with Stent Report

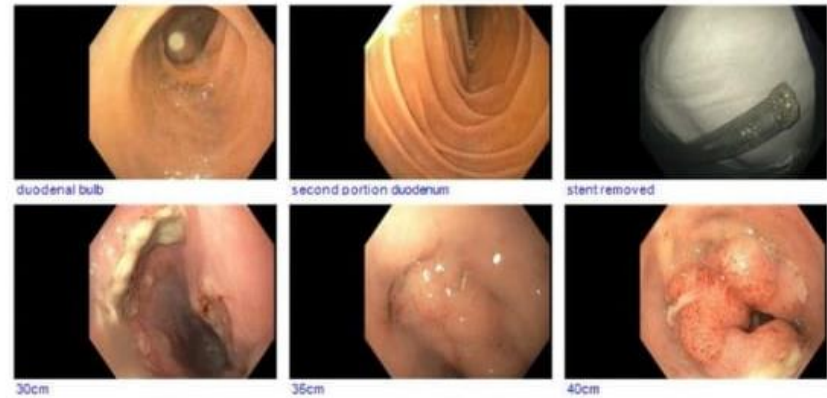Date: 2/8/2021 7:35 AM
Patient Name: NYNA TONEY **Gender:** Female
MRN: 405259648 **DOB (age):** 8/9/1988 (32)
Account Number: 102312544
Patient Type: Inpatient
Endoscopist(s): Thomas Kowalski, MD
Referring Physician: ALEC C. BEEKLEY, MD
Walnut Towers 211 S 9TH Street Suite 402, PHILADELPHIA, PA 19107
(215) 955-0020 (phone)
(215) 503-7577 (fax)
Anesthesia Provider: Jefferson Anesthesia Provider
ASA Class: P2 - 2/8/2021 7:57 AM Jefferson Anesthesia Provider,
Instrument(s): GIF-HQ190-8782(2518782)
GIF2TH180-1271(2501271)
Total Medications: see anesthesia record
Indications: Perforation of esophagus: 530.4 - K22.3
Imaging result abnormal: 793.99 - R93.89
Bariatric surgery status: V45.86 - Z98.84

History of Present Illness:

The history and physical was reviewed, the patient was examined and no change has occurred in the patient's condition since the history and physical was completed.



Feb 8, 2021 – Stent Removal



Procedure:

The procedure, indications, preparation and potential complications were explained to the patient, who indicated understanding and signed the corresponding consent forms. General anesthesia was administered by nurse anesthetist. Continuous pulse oximetry and blood pressure monitoring were used throughout the procedure. Supplemental oxygen was used. Patient was placed in prone position. The endoscope was introduced through mouth and advanced under direct visualization until second part of the duodenum reached. Retroflexion was performed. Patient tolerance to the procedure was good. The procedure was not difficult. CO2 was used throughout the procedure.

Limitations/Complications: There were no apparent limitations or complications

Findings:

Esophagus *Additional esophagus findings* There was a previous esophageal stent. The proximal end of the stent was located 30cm from the incisors. There was ulceration at the proximal end of the stent but no evidence of perforation. The GE junction was 35cm from the incisors. There was dimpling adjacent to a suture line at 35cm but no clear fistulous opening. The distal end of the stent was 40cm from the incisors.

Stomach *Additional stomach findings* There was narrowing of the gastric lumen consistent with a previous sleeve gastrectomy. There was significant erythema and edema of the gastric mucosa where the distal end of the esophageal stent had contacted the wall of the stomach leading to luminal compromise. The endoscope could be passed through the edematous area with minimal resistance.

Duodenum Normal duodenum.

Other Interventions: The previous esophageal stent was removed.



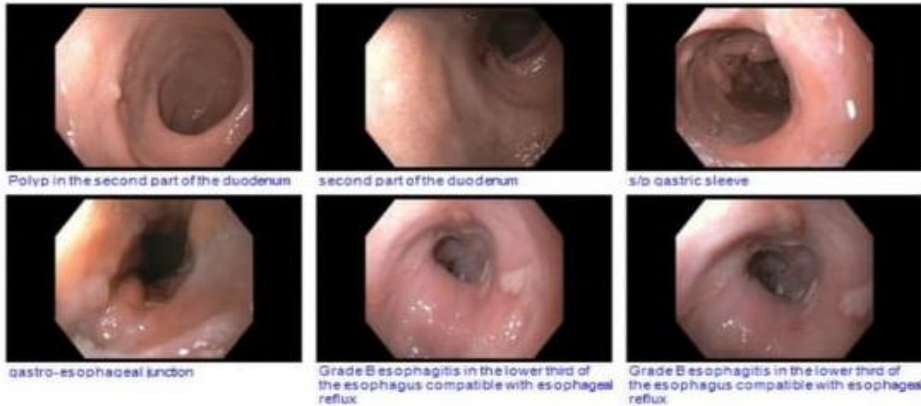Thomas Jefferson University Hospital
132 South 10th Street
Philadelphia, PA 19107
215-955-8900

Esophagogastroduodenoscopy Report

Date: 3/22/2021 10:27 AM
Patient Name: NYNA TONEY **Gender:** Female
MRN: 405259648 **DOB (age):** 8/9/1988 (32)
Account Number: 107938484
Patient Type: outpatient
Endoscopist(s): Monjur Ahmed, MD
Anesthesia Provider: Jefferson Anesthesia Provider
ASA Class: P2 - 3/22/2021 12:11 PM
Instrument(s): GIF-HQ190-9045(2859045)
Indications: Dysphagia: 787.20 - R13.10

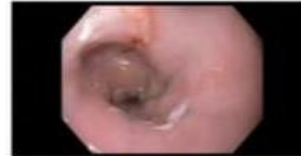History of Present Illness:

The history and physical was reviewed, the patient was examined and no change has occurred in the patient's condition since the history and physical was completed.



NYNA TONEY (405259648, 8/9/1988) - Esophagogastroduodenoscopy, 3/22/2021

Mar 22, 2021 Endoscopy



Grade B esophagitis in the lower third of the esophagus compatible with esophageal reflux.

Procedure:

The procedure, indications, preparation and potential complications were explained to the patient, who indicated understanding and signed the corresponding consent forms. MAC was administered by nurse anesthetist. Continuous pulse oximetry and blood pressure monitoring were used throughout the procedure. Supplemental oxygen was used. Patient was placed in left lateral decubitus position. The endoscope was introduced through mouth and advanced under direct visualization until second part of the duodenum reached. Retroflexion was performed. Patient tolerance to the procedure was good. The procedure was not difficult.

Limitations/Complications: There were no apparent limitations or complications

Findings:

<u>Esophagus</u>	Mucosa	Grade B esophagitis with no bleeding was seen in the lower third of the esophagus, compatible with esophageal reflux. Cold forceps biopsies were performed for histology.
<u>Stomach</u>	Lumen Mucosa	Evidence of a previous gastric sleeve was seen in the stomach. Normal mucosa was noted in the stomach. Cold forceps biopsies were performed for H. pylori assessment in the stomach antrum.
<u>Duodenum</u>	Protruding lesions	A single polyp of benign appearance was found in the second part of the duodenum. Cold forceps biopsies were performed for histology.
	Additional duodenum findings	Otherwise normal duodenum..

Impressions:

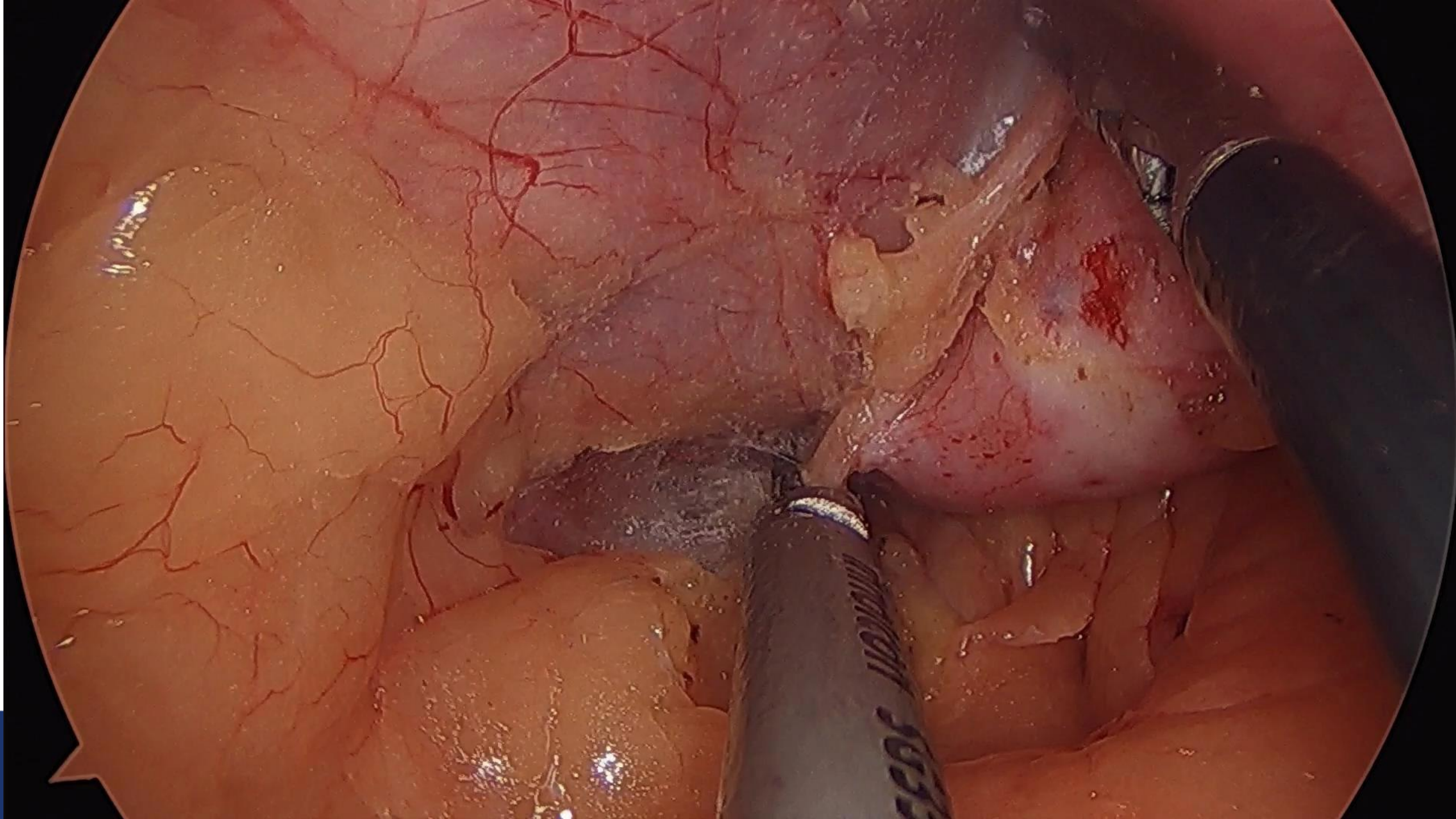
- Polyp in the second part of the duodenum. (Biopsy).
- Gastric previous surgery.
- Otherwise normal duodenum. .
- Normal mucosa in the stomach. (Biopsy H-Pylori).
- Grade B esophagitis in the lower third of the esophagus compatible with esophageal reflux. (Biopsy).

Plan: Start PPI bid
Advance diet as tolerated
Follow up biopsies

Melbourne 2024

**Case 2: Female, 50 years old, BMI 52 kg/m² –
Unexpected intraoperative severe bleeding in the dissection of the greater curve in a LSG**





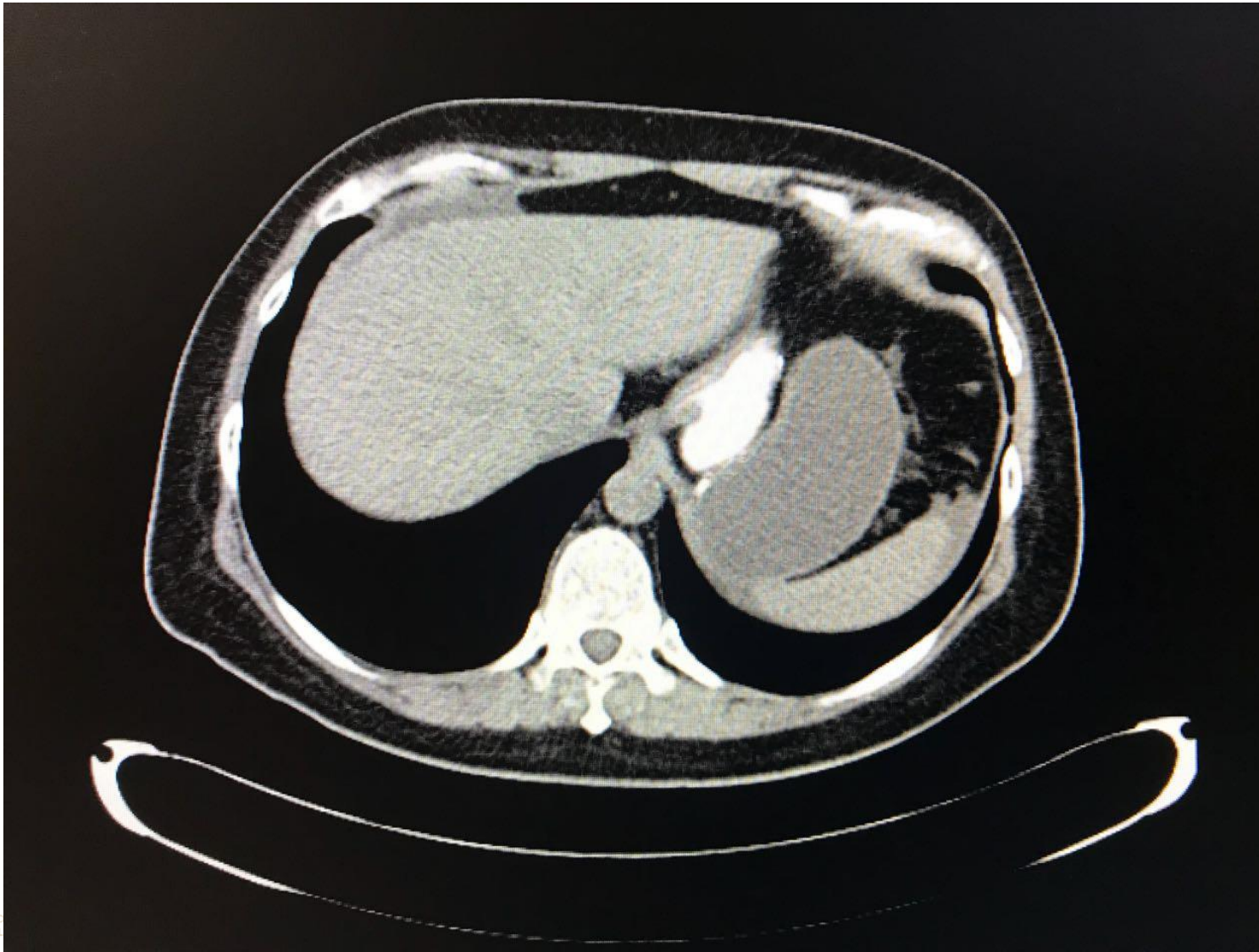
Case 3: Male, 53 years old, BMI 27 kg/m² , RYGB 18 months ago, presenting chronic abdominal pain in the last months but now with 18h of severe acute pain and tachycardia



XXVII Ifso World Congress



Melbourne 2024



GCC
CENTRO DE
METABÓL

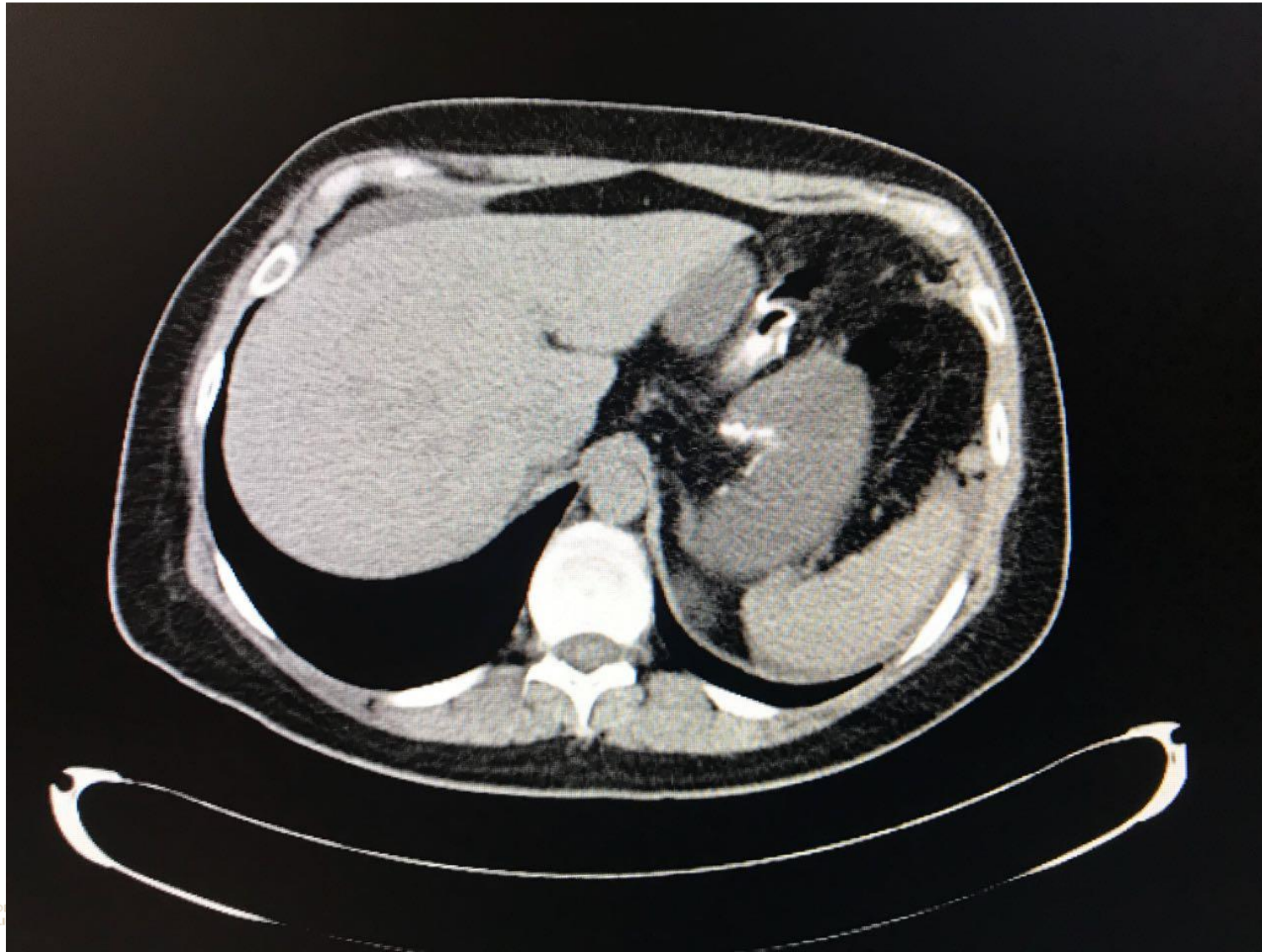


Elias Ortiz & Company
MEXICO WEIGHT LOSS SPECIALISTS

XXVII Ifso World Congress


IFSO
MELBOURNE 2024

Melbourne 2024



GCC
CENTRO DE
METABOLISMO

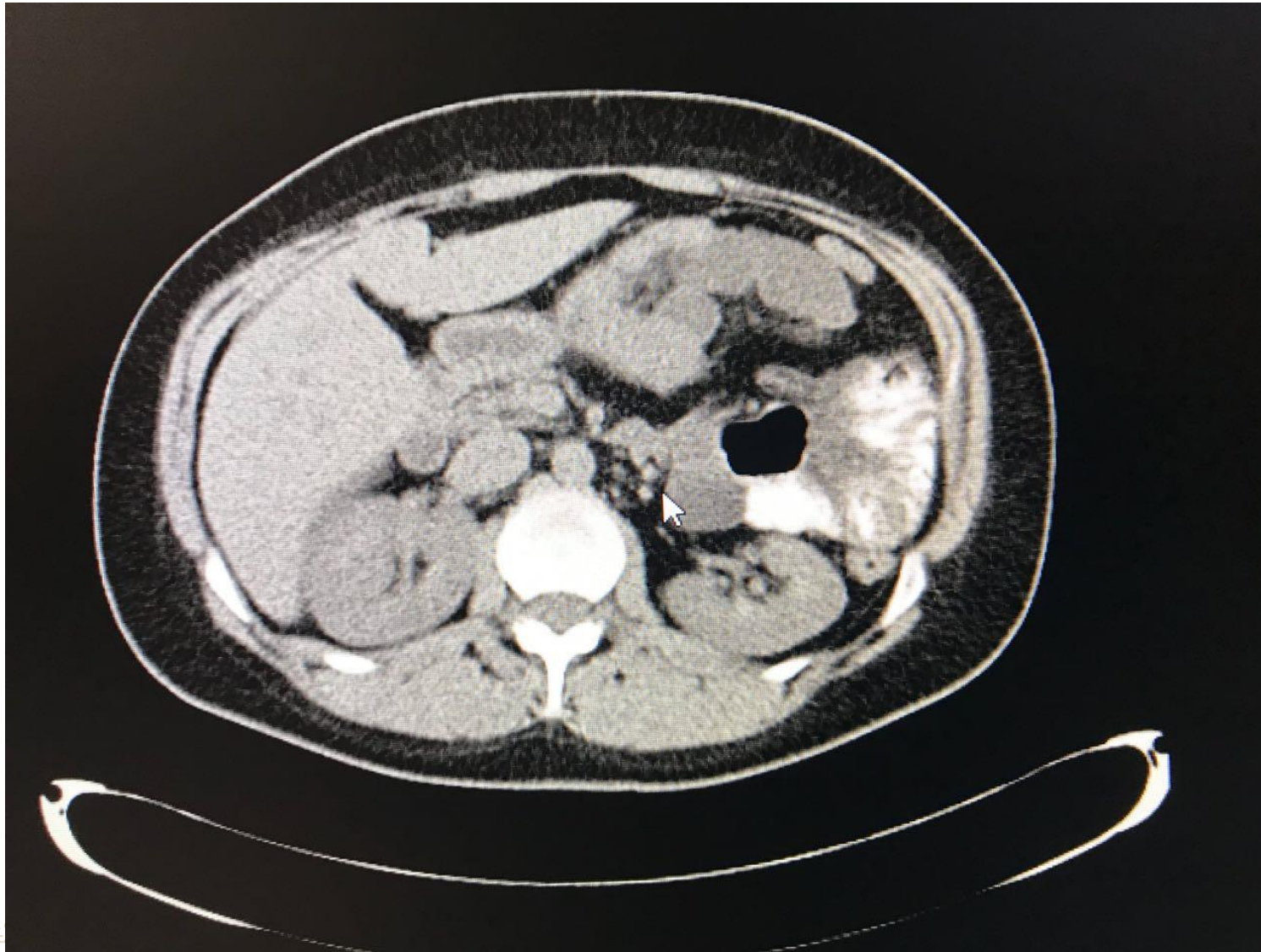

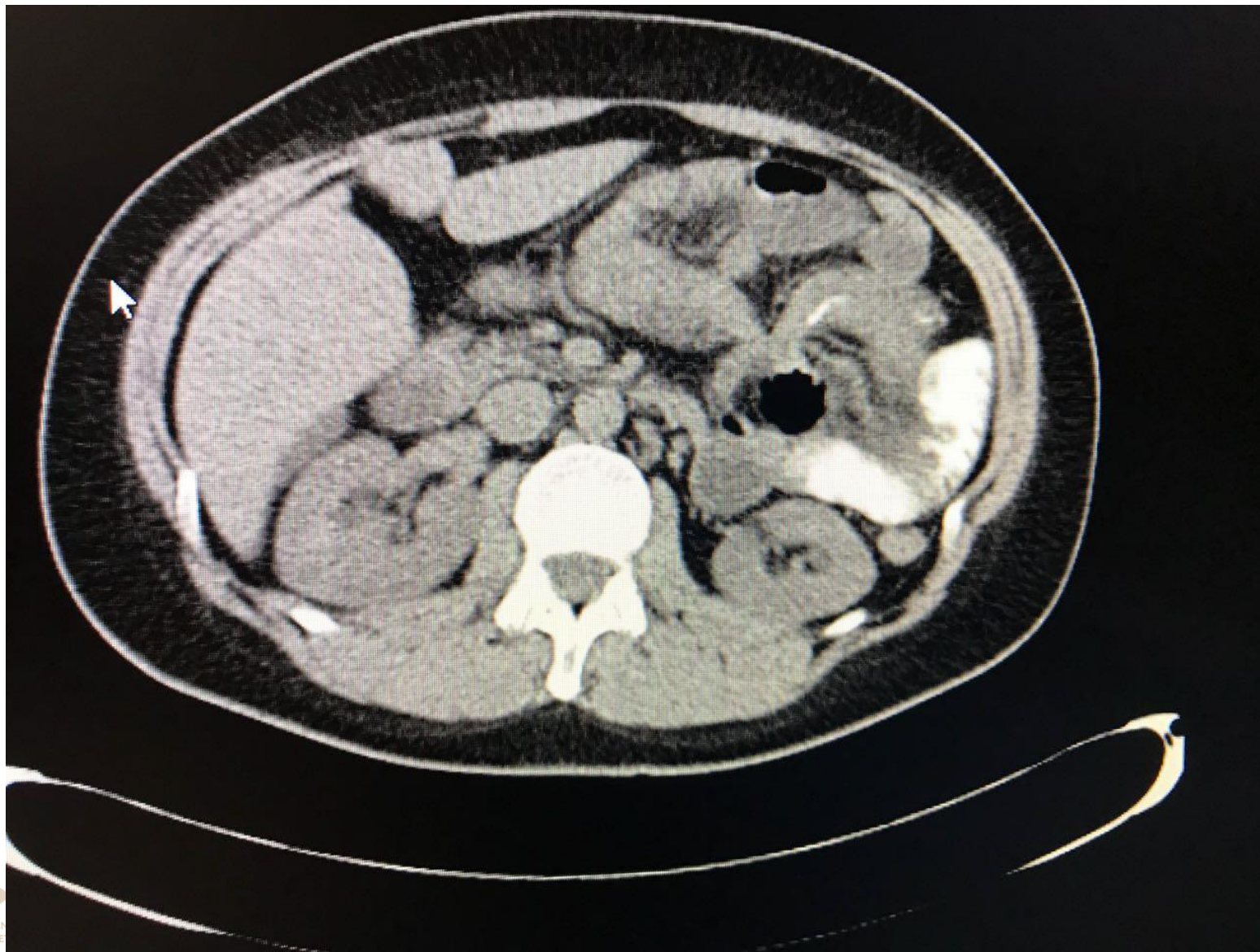
Elias Ortiz & Company
MEXICO WEIGHT LOSS SPECIALISTS

XXVII Ifso World Congress


IFSO
MELBOURNE 2024

Melbourne 2024





GCC
CEN
ME

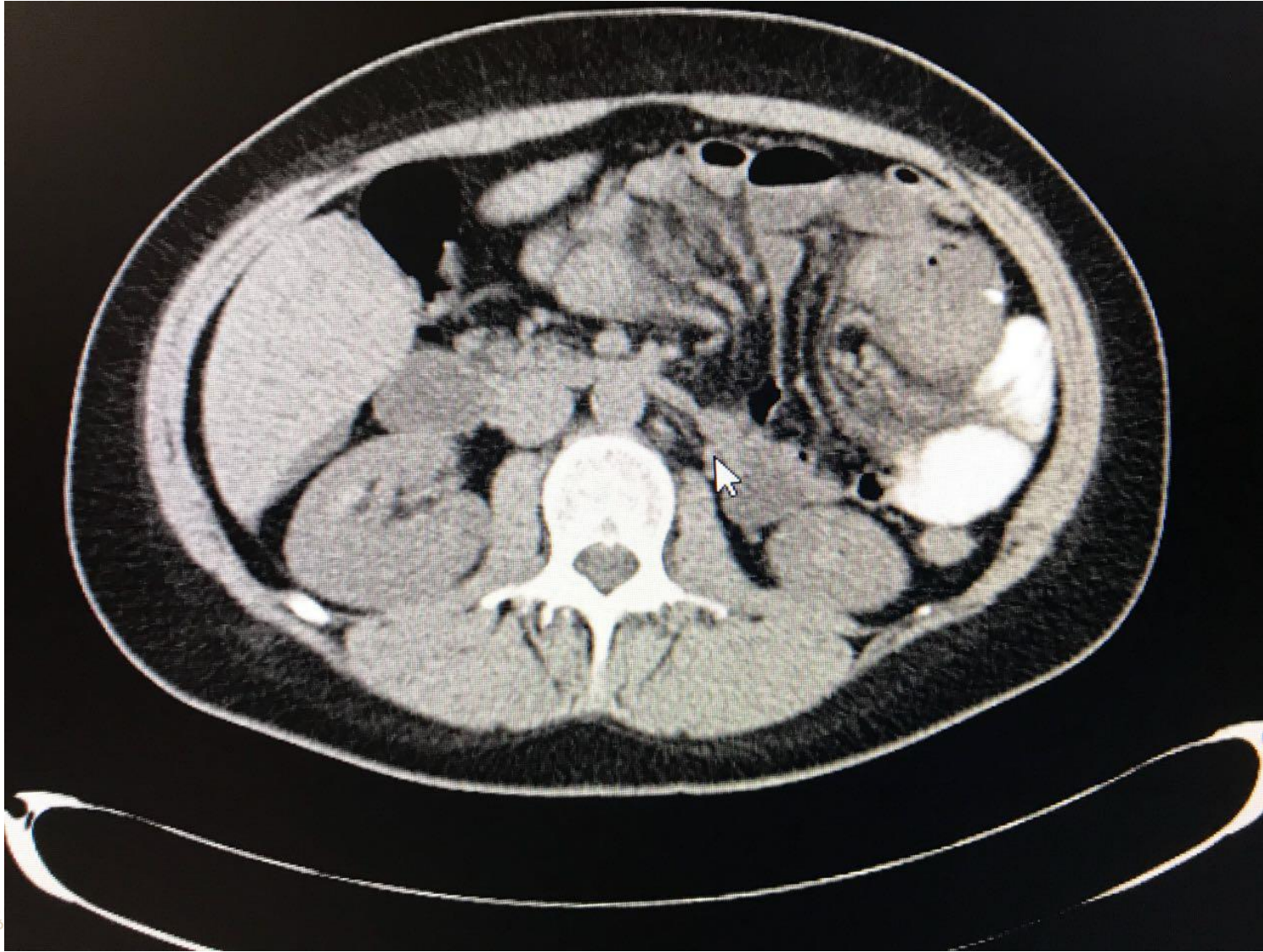


Elias Ortiz & Company
MEXICO WEIGHT LOSS SPECIALISTS

XXVII Ifso World Congress


IFSO
MELBOURNE 2024

Melbourne 2024



GCC
CENTRO
METABÓ



Elias Ortiz & Company
MEXICO WEIGHT LOSS SPECIALISTS

XXVII Ifso World Congress

IFSO
MELBOURNE 2024

Melbourne 2024

Thank you!
Gracias!



Almino Cardoso Ramos
ramos.almino@gmail.com



almino.ramos



dr.almino_ramos