

# Acute Parahiatal Hernia After Sleeve Gastrectomy

**Mohamed Hany MD<sup>a,c</sup>, Mohamed Ibrahim MD<sup>b</sup>, Ahmed Zidan MD<sup>b</sup>, Bart Torensma. MSc, PhD<sup>d</sup>**

*<sup>a</sup> Professor at the Department of Surgery, Medical Research Institute, Alexandria University, Egypt*

*<sup>b</sup> Department of Surgery, Medical Research Institute, Alexandria University, Egypt*

*<sup>c</sup> Consultant of bariatric surgery, Medina Womens' hospital. IFSO centre of excellence*

*<sup>d</sup> Clinical Epidemiologist, Leiden University Medical Center (LUMC), Leiden, The Netherlands.*

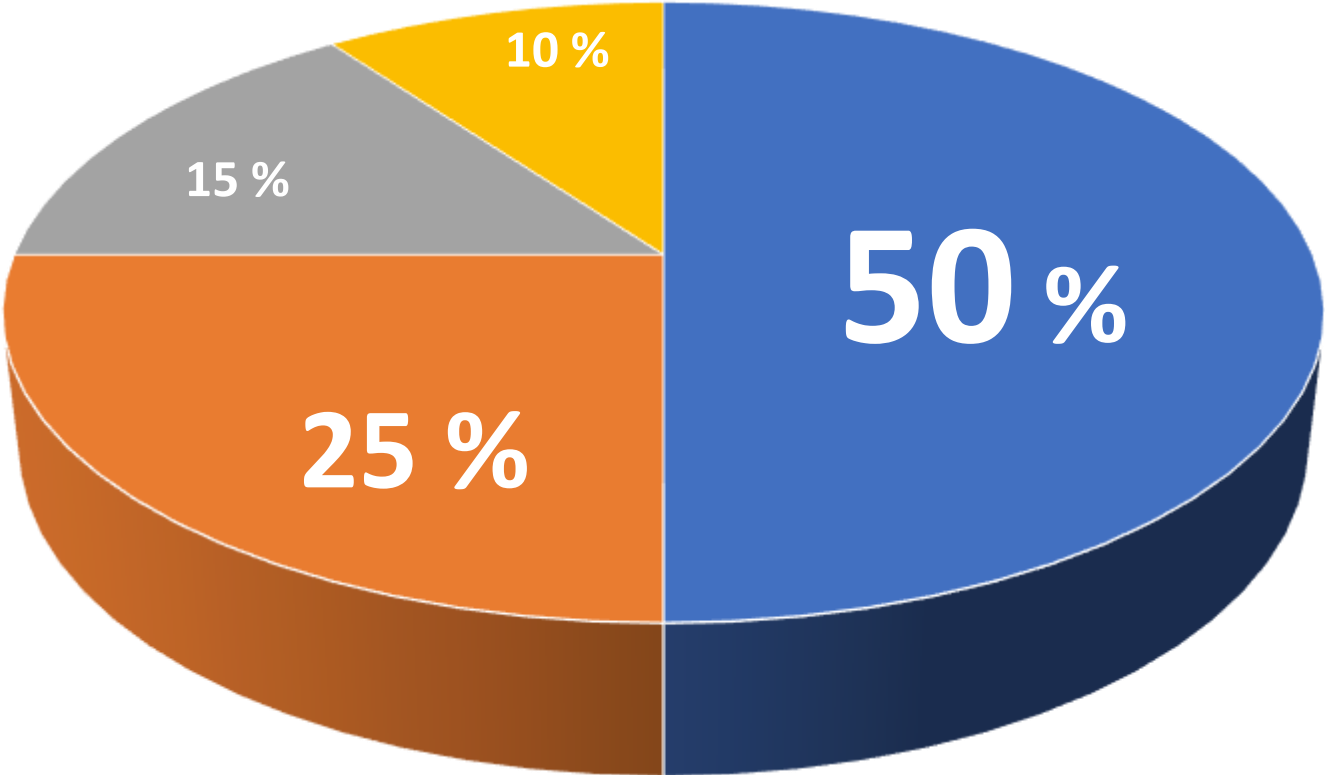


**We have no potential conflict of interest to report**



CASE MIX DISCLOSURE

Operation



■ SG ■ Revisional ■ RYGB ■ OAGB



# Clinical Presentation

- 36 year old female
- BMI 38 Kg/m<sup>2</sup> + osteoarthritis + menstrual irregularities
- Sleeve gastrectomy on September 2021
- Lab work-up and upper endoscopy normal before surgery



[mohamed.ashour@alexu.edu.eg](mailto:mohamed.ashour@alexu.edu.eg)

ORCID: 0000-0001-6650-8112

+20 100 2600970

Egypt



Thank you



[bart@torensmaresearch.nl](mailto:bart@torensmaresearch.nl)

ORCID: 0000-0003-0274-9608

+316 41 38 90 70

The  
Netherlands

